

# VU Research Portal

## Tattoo complications

van der Bent, Sebastiaan Alain Servé

2021

### **document version**

Publisher's PDF, also known as Version of record

[Link to publication in VU Research Portal](#)

### **citation for published version (APA)**

van der Bent, S. A. S. (2021). *Tattoo complications: Diagnosis and treatment*. s.n.

### **General rights**

Copyright and moral rights for the publications made accessible in the public portal are retained by the authors and/or other copyright owners and it is a condition of accessing publications that users recognise and abide by the legal requirements associated with these rights.

- Users may download and print one copy of any publication from the public portal for the purpose of private study or research.
- You may not further distribute the material or use it for any profit-making activity or commercial gain
- You may freely distribute the URL identifying the publication in the public portal ?

### **Take down policy**

If you believe that this document breaches copyright please contact us providing details, and we will remove access to the work immediately and investigate your claim.

### **E-mail address:**

[vuresearchportal.ub@vu.nl](mailto:vuresearchportal.ub@vu.nl)

# TATTOO COMPLICATIONS

Diagnosis and treatment

*S.A.S. van der Bent*



# **TATTOO COMPLICATIONS**

## **Diagnosis and treatment**

Sebastiaan Alain Servé van der Bent

De afbeelding op de omslag van dit proefschrift is gemaakt door Henk Schiffmacher (betrokken bij opening van de Tattoo poli in 2017) in samenwerking met Herman Brood. Het kunstwerk, genaamd Fisherman's Friend, is gemaakt in 2007. De afbeelding behelst een lichaam gemaakt in de karakteristieke stijl van Brood, met hierop tatoeages in de stijl van Schiffmacher. Dit alles op een achtergrond met een veelbesproken en omstreden kleur: rood.

*The image on the cover of this thesis is made by Henk Schiffmacher (involved in the opening of the Tattoo Clinic in 2017) in collaboration with Herman Brood. This work of art, called 'Fishermans Friend', was produced in 2007. The illustration beholds a body made in the typical style of Brood, which contains tattoos made in the style of Schiffmacher. The background of the illustration is the much-discussed and controversial colour: red.*

Gepubliceerd met toestemming van de uitgever/artiest.  
*Published with consent of the artist/publisher.*

---

## **Tattoo complications: diagnosis and treatment**

ISBN/EAN: 978-94-93197-49-7

Copyright © 2021 **S.A.S. van der Bent**

All rights reserved. No part of this thesis may be reproduced, stored or transmitted in any way of by any means without the prior permission of the author, or when applicable, of the publishers of the scientific papers.

Layout and printing: Off page, [www.offpage.nl](http://www.offpage.nl)

### *Contact details*

Tattoo poli, Alrijne Ziekenhuis  
Houtlaan 55, 2334 CK Leiden  
[info@tattoopoli.nl](mailto:info@tattoopoli.nl)

Financial support for printing this thesis was generously provided by:

[www.tattoopoli.nl](http://www.tattoopoli.nl), Huidstichting Chanfleury van IJsselstein, Bayer BV (Bepanthen), Pigmentfonds Nederland ([pigmentfonds.nl](http://pigmentfonds.nl)), BAP Medical BV, La Roche-Posay, Viatrix BV, Van der Bend BV, Pfizer BV, Beiersdorf NV (Eucerin), Galderma Benelux BV, Almirall BV, [Viligo.nl](http://Viligo.nl), Tobrix BV, Psoriasispatiënten Nederland, BlooMEDical Benelux BV, Berg Care, Lichen Planus Vereniging Nederland, Laservision instruments BV, Flen Health, 4C Creative Cad Cam Consultants, Bundesverband Tattoo e.V., Tattoland, LEV Medische Groothandel BV, Nederlands PMU Congres 2021, Olmed, ild care foundation ([www.ildcare.nl](http://www.ildcare.nl)), Chipsoft, LEO Pharma BV, Landelijke Stichting voor Blinden en Slechtzienden, Dalton Medical BV (Medical & Aesthetic lasers), Stichting Wetenschappelijk Onderzoek Psoriasis

VRIJE UNIVERSITEIT

**TATTOO COMPLICATIONS**

Diagnosis and treatment

ACADEMISCH PROEFSCHRIFT

ter verkrijging van de graad Doctor aan  
de Vrije Universiteit Amsterdam,  
op gezag van de rector magnificus  
prof.dr. V. Subramaniam,  
in het openbaar te verdedigen  
ten overstaan van de promotiecommissie  
van de Faculteit der Geneeskunde  
op vrijdag 9 april 2021 om 11.45 uur  
in de aula van de universiteit,  
De Boelelaan 1105

door

Sebastiaan Alain Servé van der Bent

geboren te Bergen op Zoom

promotor: prof.dr. T. Rustemeyer

copromotor: dr. A. Wolkerstorfer

overige leden: prof.dr. R. Hoekzema

prof.dr. P.W.B. Nanayakkara

prof.dr. M.R. van Dijk

dr. M.C. Leger

dr. I.J. Schornagel

dr. E.M. de Boer

dr. C. de Cuyper

paranimfen:

drs. J.J.W.M. Brouwers

A.A.W. van der Bent, MSc





# TABLE OF CONTENTS

<b>Chapter 1</b>	General introduction	9
<b>PART I</b>	<b>CLINICAL ASPECTS</b>	<b>37</b>
<b>Chapter 2</b>	Red tattoo reactions, a prospective cohort on clinical aspects	39
<b>Chapter 3</b>	Tattoos and self-reported adverse events in sarcoidosis patients	47
<b>Chapter 4</b>	Granulomatous tattoo reactions in permanent makeup of the eyebrows	55
<b>PART II</b>	<b>DIAGNOSTICS AND PATHOMECHANISM</b>	<b>63</b>
<b>Chapter 5</b>	Histopathology of red tattoo reactions	65
<b>Chapter 6</b>	Comparison of the skin sensitization potential of five red and black tattoo inks using IL-18 biomarker in a Reconstructed Human Skin model	81
<b>Chapter 7</b>	Quantification of cutaneous allergic reactions using 3D optical imaging: A feasibility study	103
<b>PART III</b>	<b>TREATMENT</b>	<b>121</b>
<b>Chapter 8</b>	Ablative laser surgery for allergic tattoo reactions: a retrospective study	123
<b>Chapter 9a</b>	Granulomatous tattoo reaction with associated uveitis successfully treated with methotrexate	139
<b>Chapter 9b</b>	Allergic reaction to red cosmetic lip tattoo treated with hydroxychloroquine.	147
<b>Chapter 9c</b>	Spontaneous resolution of multidrug-resistant Mycobacterium abscessus infection in tattoo	155
<b>Chapter 10</b>	General discussion	163
<b>Chapter 11</b>	General summary	183
	Algemene samenvatting	189
<b>Appendices</b>	PhD Portfolio	195
	Dankwoord	203
	List of publications	208
	Curriculum vitae	213

1

# GENERAL INTRODUCTION

---

Sebastiaan A.S. van der Bent

Partially covered in: Huisman S, van der Bent SAS, Maijer KI, Tio D, Rustemeyer T. Cutaneous non-allergic complications in tattoos: an overview of the literature. *PRESSE MEDICALE*. 2020 Dec;49(4).



# GENERAL INTRODUCTION

## Tattoos: definition, usage and incidence

Body art involves decorating the skin of the human body. Forms of body art include tattoos, piercings, scarification, subdermal implants (also called beadings or boegroes), shaping, body painting, tongue splitting or elf ears. Tattoos are one of the most popular forms of body art. It is defined as creating a permanent design by placing exogenous pigment particles and additives into the dermis.<sup>1</sup> The demand, and sometimes need for tattoos should not be underestimated. In the last decades, tattoos have become more popular. In Europe and the USA the overall prevalence of tattoos in the population is around 10-20% and rising.<sup>2-10</sup> The percentage of tattooed Europeans increased from 5-10% in 2003 to 12% in 2016.<sup>11</sup> Also, in the USA, an increase of tattooing is reported. Data from the Harris Poll survey from 2003 showed that 16% of the Americans was tattooed; in 2015 this percentage rose to 29%.<sup>12</sup> In the Netherlands, 8-12% of the population older than 12 years has a tattoo.<sup>13</sup> In the past, tattoos were associated with sailors, criminals, soldiers and prostitutes. Also, tattooing was more prevalent among men. However, this all has changed over the last decades. Nowadays, in the Netherlands and several other countries, women (60%) are more frequently tattooed than men (40%).<sup>13</sup> Furthermore, the uses of tattoos are broadened, for example permanent makeup: tattooing of the eyeliner, lips, lipliner or eyebrows. Tattoos are not only used for decorative reasons, but also for several medical purposes: nipple areola tattooing after breast cancer surgery, radiology markings, camouflage of scars or even medical marking of colon- or oral mucosa.

In general, tattooing is considered to be safe. However, different complications can occur. The exact incidence of tattoo complications is unknown. Furthermore, despite its popularity, little is known about the clinical spectrum, pathogenesis and treatment of dermatological and systemic tattoo complications. Nonetheless, it is important for clinicians to timely identify and treat these complications. The literature consists of only few original studies regarding tattoo complications of which most are case-reports and case-series. Moreover, in the last decades there has been changes in the composition of the inks as well as a great shift in the international tattoo industry. Inorganic tattoo pigments, such as heavy metals, have been widely replaced by organic pigments such as azo pigments. The results of the shift in tattoo inks regarding tattoo complications is unknown.<sup>14,15</sup> Currently, safety of tattoos and permanent make-up is discussed in the EU, mainly focused on content analysis of tattoo inks.<sup>16-19</sup> However little research has been performed about the impact, nature and number of complications that occur associated with tattooing. Also, permanent makeup is an upcoming form of tattooing of the last decade and its popularity is increasing. As the type of use of tattooing has broadened and new tattoo inks have been introduced, new complications may occur. Therefore, it is important that research on tattoo complications is performed to assess the risk of these new techniques, inks and types of use.

Because of its enormous popularity, worldwide use and potential serious complications, this thesis is relevant for many healthcare workers and all people involved in the tattoo industry: dermatologists, general practitioners, internists, pulmonologists, ophthalmologists, cosmetic doctors, tattoo artists, beauticians, tattoo ink producers, regulatory authorities and policymakers. Furthermore, tattoo clients should be well informed about the possible adverse events that can occur during and after tattooing.

In the past, medical research on tattoos was underexposed. Hopefully, this thesis will trigger more research.

## **Tattoo adverse events**

An adverse reaction may occur due to the tattooing procedure itself and/or subsequent application of aftercare products. Numerous articles report the wide spectrum of adverse reactions related to tattooing, ranging from superficial infections, allergic reactions, vasculitis and sarcoidosis. These reactions have a different time of onset of symptoms, appearing immediately after placement of the tattoo until several years later. This introduction will focus on cutaneous adverse reactions of tattoos. Systemic, temporary (henna), psychosocial and complications due to removal of tattoos will not be discussed in this chapter.

## **SYMPTOMS**

Cutaneous adverse reactions to tattoos can be roughly divided into four categories: infections, inflammatory reactions, miscellaneous complications and seldomly reported neoplasms. An overview of the dermatoses is listed in table 1. The most frequently reported dermatoses will be discussed.

Reported complaints related to previously mentioned categories of adverse reactions vary from local itch and pain to skin elevation and burning sensations at distinct sites.

Reliable incidence rates of adverse reactions are missing. Kazandjieva et al. reported several long-term adverse reactions such as infections in 5 out of 234 patients (2.1%).<sup>20</sup> However in self-reported questionnaires physical complaints are reported more often. This may implicate that many persons who have gotten a tattoo do not seek for medical advice regarding adverse reactions to tattoos. An internet survey, performed in German-speaking countries, reported skin problems in 67% of the 3411 collected reports that had occurred within a few weeks after tattooing. Furthermore, 6 percent reported persistent skin problems in the tattooed area.<sup>21</sup> Another study performed in 154 Danish individuals who attended a clinic of venereology, reported reactions secondary to tattooing in 27% of the individuals. Complaints were mainly minor, varying from skin elevation to itching.<sup>22</sup> The 'beach study', performed in 144 sunbathers (individuals sunbathing from June to September 2011 at the beaches of Denmark) with in total 301 tattoos, reported adverse reactions such as swelling, itching, pain and redness in 42% of the individuals.<sup>23</sup> Remarkably, the two Danish studies describe that respectively 58% and 52% of complaints

**Table 1.** Overview of the associated and reported dermatoses in tattoos. Reported micro-organism are shown in italics.

<b>Infectious</b>	<b>Inflammatory</b>	<b>Neoplasms</b>	<b>Miscellaneous</b>
Bacterial	Allergic reaction to tattoo pigment	Benign	Hematoma
<i>Atypical mycobacteria</i>	Excessive hyperkeratotic	Dermatofibroma	Hypertrophic scar
Cellulitis	Generalised	Epidermal cyst	Keloid
Erysipelas	Plaque-like	Pseudo-epitheliomatous hyperplasia	Misapplication
Folliculitis	Ulceronecrotic	Seborrheic keratosis	MRI-scan induced symptoms
Furunculosis	Allergic reaction to tattoo (after)care products	Malignant	Neurosensory itch or pain
Impetigo	Atopic dermatitis	Basal cell carcinoma	Overworked tattoo
<i>Syphilis</i>	Auto-immune and auto-inflammatory	Keratoacanthoma	Photo induced reactions
<i>Tuberculosis</i>	Granuloma annulare	Cutaneous leiomyosarcoma	Pigment fanning
Mycosis	Morphea	Cutaneous lymphoma	Pigment fading
Acremonium	Lichen planus	Dermatofibrosarcoma protuberans	Pigment migration
<i>Aspergillus fumigates</i>	Lichen sclerosus	Melanoma	Pigment overload
Dermatophytosis	Lupus erythematoses	Squamous cell carcinoma	Tattoo blow-out
Sporotrichosis	Pyoderma gangrenosum		Tattoo removal complications
Zygomycosis	Sarcoidosis		Laser
Parasitic	Vitiligo		Non-laser
<i>Leishmaniasis</i>	Erythema multiforme		
Viral	Foreign body reaction		
Hepatitis B and C	M. Darier		
Herpes simplex	Perforating collagenosis		
<i>Human papilloma virus</i>	Pseudolymphoma		
HIV	Urticaria		
<i>Molluscum contagiosum</i>	Vasculitis		
Rubella			

were sun related. A cross-sectional survey in 38 American states found that among the 501 participants, 3.2% stated to have a history of a tattoo infection. In tattoos of at least one month old, pruritus and pain occurred in 22.6% and 3.8% respectively.<sup>24</sup> The Dutch Food and Drug Administration ('Nederlandse Voedsel en Warenautoriteit', NVWA) performed an analysis on tattooed individuals above the age of 12 years old in the Netherlands. Three percent reported inflammation, bleeding or allergic reactions related to tattooing.<sup>13</sup> In a survey of 300 randomly selected tattooed people in New York City, 10.3% reported experiencing an adverse tattoo reaction.<sup>25</sup>

Taken together, many articles report on various adverse reactions due to tattooing and show that symptoms such as itching and morphological changes such as skin thickening are remarkably common. However, incidence rates of these adverse reactions vary. It should be noted that all above-mentioned data are self-reported and do not include a confirmed clinical diagnosis.

## INFECTIONS

Tattooing is a technique to penetrate the skin barrier for the intended deposition of coloured materials. This procedure bears the intrinsic risk of causing an infection. Hygiene regulations have been tightened in the past and since then incidences have dropped. However even with appropriate precautions microbial contamination after tattooing may still occur. The risk of infection depends on several determinants: the skin condition under which the tattoo has been placed, proper sterilization of equipment, contamination of ink, disinfection of the skin and proper aftercare. For instance, a Danish study showed that already 10% of the unopened tattoo ink stock bottles in Denmark were contaminated with a variety of bacteria. Among them were pathogenic as well as non-pathogenic bacteria. Furthermore, 28% of the analysed stock bottles were inadequately sealed.<sup>26</sup> The Dutch NVWA has performed microbiological research on unopened ink stock bottles between 2008 and 2013. Remarkably in 2009 and 2010 they have noticed a substantial number of contaminated samples. Respectively 15% and 8% of the samples were polluted with microorganisms. All contaminated samples were produced by one manufacturer. In the subsequent years, the number of contaminated samples decreased to 1 to 3%.<sup>27</sup>

Despite hygiene legislation infections are still thought to be the most frequent complication. Also, as the incidence of tattooing and worldwide travelling is increasing, a new assessment of the number and type of tattoo infections is needed.

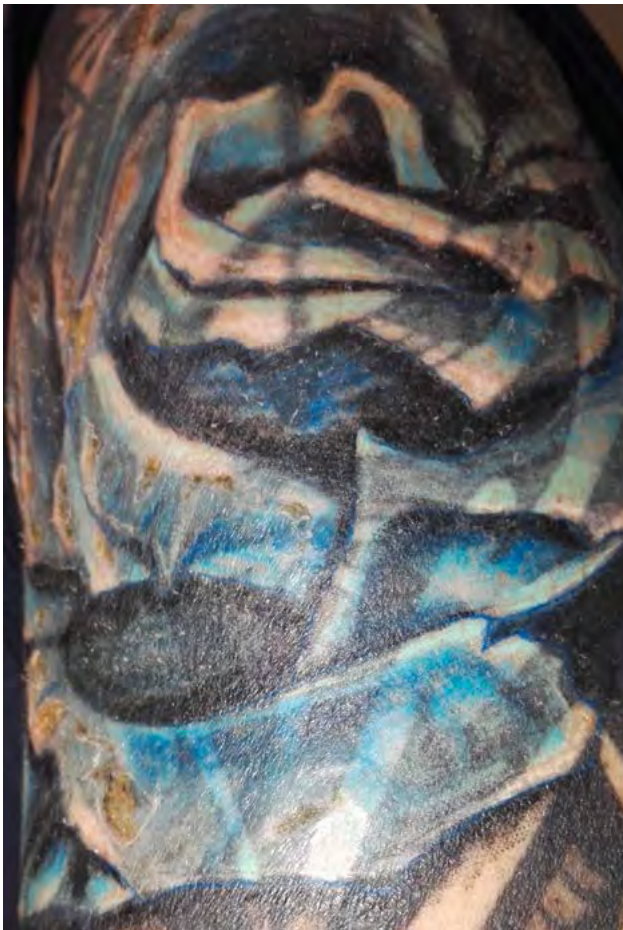### Bacterial infections

Although no exact incidence rates are available, the most frequent clinical infections are impetigo and folliculitis (fig. 1). For these superficial infections *Staphylococcus aureus*, *Streptococcus pyogenes*, *Clostridium difficile* and *Pseudomonas aeruginosa* are the most important culprits. Furthermore, infections involving the inner layers of the skin, like cellulitis and erysipelas, are reported as well (fig. 2).<sup>28</sup> Clinical signs of bacterial infections include

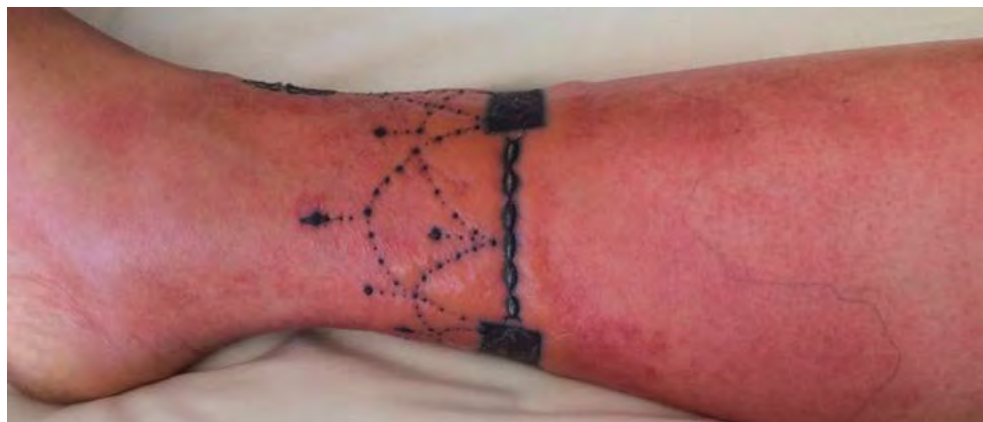

local pain, erythema and swelling, but also fever and purulence. Cellulitis or erysipelas should not be confused with temporary tattoo-induced oedema. This transient oedema is induced by the tattooing procedure, especially when applied to the lower extremities. This reaction is frequent and may occur in any individual.<sup>29</sup> Most bacterial infections are easily treatable and treatment is regularly not different from that of any other bacterial infection. However, various pathogens can be more difficult to treat. For instance, an outbreak of tattoo infections with methicillin-resistant *Staphylococcus aureus* (MRSA) was observed in three American states.<sup>30</sup>

In the last decades one case of secondary syphilis occurring within a tattoo has been described. In the 19<sup>th</sup> century syphilis was more commonly described. Back in those days, tattoo artists would moisten the needle with saliva or use non-sterile or used needles. This could result in tattooist contaminating the patient with *Treponema pallidum*.<sup>31</sup>



**Figure 1.** Golden yellow crusts in a recently placed tattoo on the upper arm: a superficial infection with *Staphylococcus aureus*.



**Figure 2.** Bullous erysipelas occurring after a black-inked tattoo was placed on the lower leg.

### **Mycobacterial infections**

During the last years, several tattoo related outbreaks of *Mycobacterium chelonae* have been reported in the literature. This occurs, in particular when grey ink is prepared by dilution of black ink with water. If the water is contaminated by *Mycobacterium chelonae*, a typical bacterium in non-sterile water, this microbe can cause infection. Less commonly, *Mycobacterium haemophilum*, *Mycobacterium abscessus*, *Mycobacterium immunogenum*, *Mycobacterium massiliense* and *Mycobacterium fortuitum* cause tattoo related skin infections.<sup>32,33</sup> Interestingly, mycobacterial infections appear more frequently in the grey or black areas of a tattoo. Clinical symptoms include papules, pustules or ulcerating nodules, which are typically confined to the tattooed area.<sup>34</sup>

Primary cutaneous tuberculosis can occur following tattooing.<sup>20</sup> This occurs after inoculation with *Mycobacterium tuberculosis* or *Mycobacterium bovis* in individuals who have not previously acquired immunity. Within 2-4 weeks an erythematous papule or nodule arises, progressing to a superficial ulcer (tuberculous chancre). Often, painless regional lymphadenopathy occurs within 3 to 8 weeks. If the patient's immune system is compromised, progression to lupus vulgaris and tuberculosis cutis verrucosus or even hematogenous spread may occur.<sup>35</sup> Histologically, epithelioid histiocytes, Langerhans giant cells and tuberculoid granulomas with or without central caseous necrosis can be found. A positive tuberculin test is of great diagnostic value for primary tuberculosis.

Reports of tattoo inoculation with *Mycobacterium leprae* are mainly described in areas where leprosy is endemic and unhygienic tattooing is common.<sup>36</sup> Leprosy skin lesions may manifest decades after inoculation. Clinical presentation mainly depends on the immunologic status of the host.

If a mycobacterial infection is clinically suspected, a biopsy, tissue culture and PCR for mycobacterium species should be performed. Histologically, these reactions are characterized by suppurative granuloma formation with polymorphonuclear leukocytes.

## Viral infections

Serious viral infections, like HIV, hepatitis B (HBV) and hepatitis C (HCV), have been reported to be transmitted through tattooing. However, in almost all reports the tattoo was performed in a non-professional setting. Under present hygiene legislation and performed by professional tattoo artists, transmission of the above-mentioned viral infections is unlikely. Moreover, a substantial number of patients carrying HIV, HBV or HCV, are exposed to other possible modes of transmission like drug use by injections. Nonetheless, for this reason, in the Netherlands, those who have set a tattoo are prohibited to donate their blood for 6 months after placement of the tattoo. This can last up to 12 months depending on local regulations.<sup>19,37</sup>

Isolated reports on the presence of human papilloma virus (HPV), herpes simplex virus (HSV) and mollusca contagiosa (MCV) have been described in tattoos.<sup>19</sup> This infection can either be transmitted by tattooing or re-activated from an already present indolent virus. The incubation period is usually weeks to months. In one case, a 32-year old patient developed HPV lesions exclusively within the tattoo lines after a latency period of 2.5 years.<sup>38</sup> The triggering factor was a recent sunburn, suggesting that ultraviolet(UV)-radiation could induce immunosuppression and trigger re-activation of HPV. When multiple viral lesions spontaneously occur within a tattoo, it may be the reason to test for underlying immunodeficiencies.

## Fungal infections

Fungal infections after tattooing are rare. However anecdotal cases of infection with dermatophytes, *aspergillus fumigatus*, sporotrichosis, zygomycosis or *Acremonium fungi* have been described. Fungal infections should be considered whenever cutaneous complications exacerbate while using topical corticosteroids.<sup>31,39.</sup>

## Parasitic infections

Cutaneous leishmaniasis arising in tattoos is rarely described with all cases occurring in individuals known with visceral leishmaniasis or HIV (which leads to immunosuppression).<sup>31</sup> Re-using needles may be a possible form of transmission. No other parasitic infections in tattoos have been reported so far.

# INFLAMMATORY COMPLICATIONS

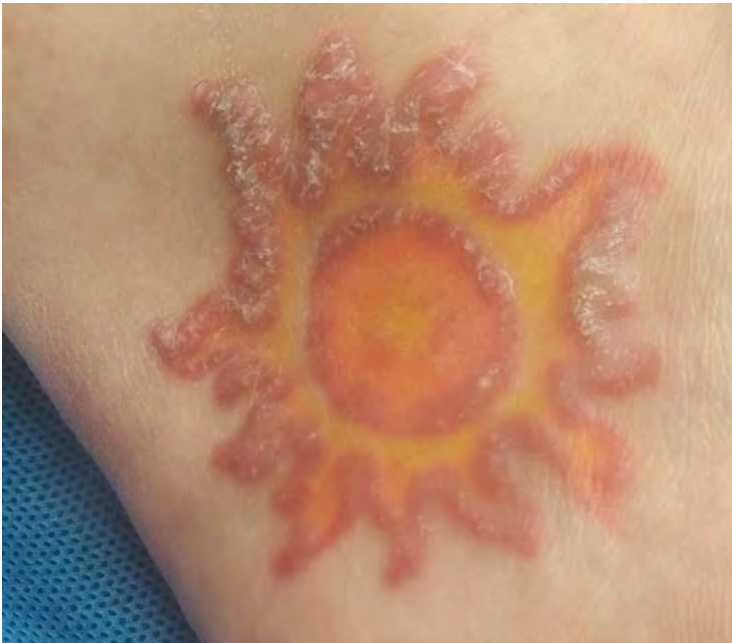## Allergic reactions to tattoo pigments

Most chronic tattoo reactions are caused by an allergic reaction to tattoo pigments. Allergic reactions to tattoo pigments cause chronic itch, pain or swelling, generally confined to one tattoo pigment colour.<sup>40</sup> The symptoms can cause a reduced quality of life.<sup>41</sup> In allergic reactions to tattoo pigments, colours red or nuances of red pigments are most frequently involved.<sup>42</sup> Already in 1927, the first red tattoo reaction was described.<sup>43,44</sup> Not only the red tattoos can be effected: blue, green and yellow tattoos are reported as well.<sup>42,45,46</sup> Rarely,

multiple colours in one tattoo can be affected, most likely caused by one pigment present in all tattoo colours.<sup>47</sup>

The clinical presentation is mainly an elevation confined to the red tattooed skin of which the most common one is called the 'plaque-type' reaction (fig. 3).<sup>48-50</sup> Other clinical varieties include excessive hyperkeratotic, ulcero-necrotic or even generalized reactions.<sup>51</sup> Few clinical studies have been done and the literature mainly consists of case reports and case series. In these, a great variety in the time of onset of symptoms is reported: varying between several days up to several years after tattooing. Little is known about the natural course and eliciting factors.

Histological examination is crucial in the diagnosis of chronic tattoo complications. The differential diagnosis includes bacterial or mycobacterial infections and autoimmune skin diseases such as sarcoidosis, lichen planus or psoriasis. Also, atopic dermatitis or contact dermatitis to aftercare products can occur. However, the exact histopathology of red tattoo reactions is not known, and many variations have been described. As in the clinical presentation, the literature mainly consists of case-reports and case studies and only few studies have been performed.<sup>52-54</sup> Obtaining more knowledge about the histopathology of red tattoo reactions would therefore be beneficial for diagnostics, but also for revealing its aetiology. These reactions are thought to be a delayed allergic reaction, but the exact pathomechanism is unknown. Clinical and *in vitro* research on red tattoos reactions could



**Figure 3.** Red and yellow tattoo on the left foot with 'plaque' elevation in the red tattooed skin: 'plaque-type' allergic red tattoo reaction.

also provide more knowledge in its aetiology. Furthermore, although thought to be an allergic reaction, the causative allergen is still unknown. In the past, mercury was thought to be the causative allergen. However, in the last decades there has been changes in the composition of the inks as well as a great shift in the international tattoo industry: inorganic tattoo pigments (such as heavy metals) have been widely replaced by organic pigments (such as azo pigments).<sup>14,15</sup> Still, red tattoo reactions seem to be the most frequent chronic tattoo reactions. Though tattoo ink may still contain heavy metals, be it as chromophores, shading additives or contaminants. Nevertheless, mercury is no longer thought to be the causative allergen.

Because of the continuous presence of tattoo pigments in the dermis, these reactions are chronic and patients experience persistent and sometimes severe symptoms. Therefore, treatment can be challenging. The therapeutic options mainly include anti-inflammatory therapy such as topical and intralesional corticosteroid administration, surgical excision, dermatome shaving and ablative laser treatment. Only few studies have been performed and most scientific literature consists of cases and case-series.<sup>53,55,56</sup> Consequently, there is a need for further research to acquire more knowledge about appropriate treatment modalities. Also, objective outcomes should be used for follow-up of treatment effect, for example by measuring the volume of a 'plaque-like' red tattoo reaction before and after treatment.

### **Allergic reactions to tattoo (after) care**

Not only tattoo pigments can cause allergic reactions, the tattooing procedure itself or the tattoo aftercare care several health risks. For example, during tattooing a severe type I allergic reaction to latex has been reported, caused by the latex gloves worn by the tattoo artist.<sup>57</sup> Also, topical products used in the aftercare of tattooing may cause contact dermatitis.<sup>58</sup> In these products frequently potential allergens are used such as fragrance, panthenol and wool alcohols.

### **Autoimmune skin diseases**

Individuals with chronic autoimmune skin disease, such as psoriasis, vitiligo, granuloma annulare, lichen planus, lichen sclerosus, pyoderma gangrenosum, lupus erythematoses, morphea, M. Darier, and sarcoidosis have a risk of localization of the skin disease in a tattoo (fig. 4).<sup>1,31</sup> These skin diseases have in common that a local skin injury can lead to the appearance of the disease. This is called the Koebner phenomenon. The Koebner phenomenon was first described in 1876 by Heinrich Koebner who discovered the formation of psoriasiform lesions in, notably, a recently placed tattoo in a psoriatic patient.<sup>59</sup> Individuals with the above-mentioned skin diseases should be warned of the potential risk of localization of the disease in a tattoo, especially if the dermatosis is active. Of note, these autoimmune adverse reactions in tattoos may be the initial presentation of the skin disease.



**Figure 4.** Sharply defined squamous plaques within and around tattoos: psoriasis Koebner phenomenon. In the center the biopsy location was marked.

Clinical characteristics are identical to those in non-tattooed skin, however physical examination may be hampered due to the ink. Usually symptoms of auto-immune skin diseases develop within a few weeks after tattooing. However, the literature shows a high variation in time interval between tattooing and onset of symptoms. Horner et al. described a patient with new-onset psoriasis guttata in a tattoo 7 months after its placement, suggesting an older skin trauma may also elicit an isomorphic inflammatory response (Koebner phenomenon).<sup>60</sup>

As the popularity and demand for tattoos is rising, more patients with auto-immune (skin) diseases want a tattoo. However, little is known about the specific risks these patients have when getting tattooed. There may be a local flare-up in the tattoo due to Koebnerization or a higher chance of getting a secondary infection due to immunosuppressive medication. New studies in autoimmune patients are needed to determine these risks. Also, for clinicians, it is important to recognize auto-immune skin diseases in tattoos as there may be systemic involvement, for example in lupus erythematosus and sarcoidosis.

### **Inflammatory chronic black tattoo reaction (papulo-nodular reactions)**

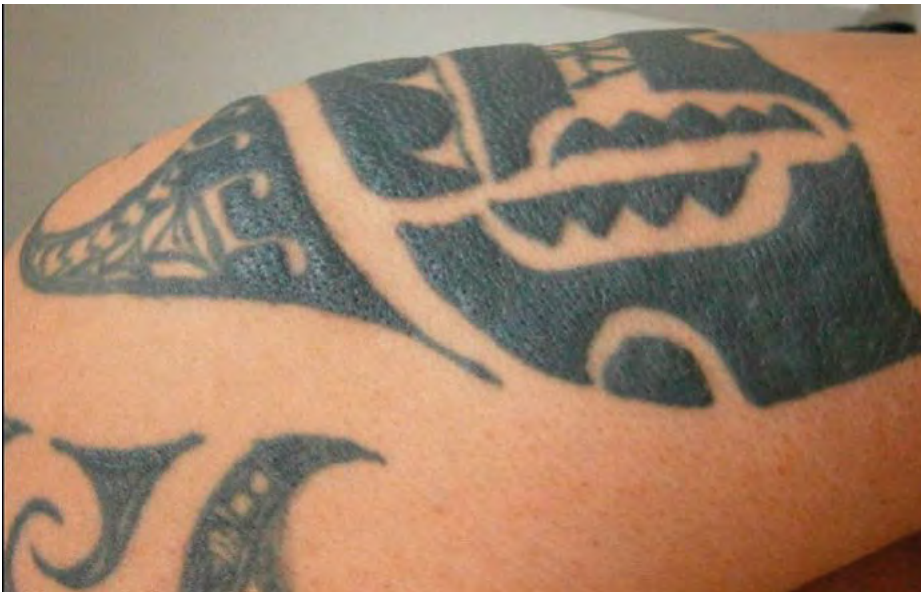Because black ink is most frequently used in tattooing, chronic inflammatory non-allergic black tattoo reactions account for a significant part of all tattoo complications. Its clinical presentation mainly includes papules and nodules in the black tattooed skin (fig. 5). Sepehri et al. observed this association between black pigment and the papulo-nodular type of tattoo reactions.<sup>61</sup> Sarcoidosis is clinically expected to be nodular and it is known that reactions in black tattoos can be a manifestation of (systemic) sarcoidosis and can even be its first. In the study of Sepehri et al. 29% of the papulo-nodular reactions

were diagnosed as cutaneous or systemic sarcoidosis. The authors therefore state that a papulo-nodular tattoo reaction should be seen as a clue to the diagnosis of sarcoidosis. The majority of these black tattoo reactions were however non-sarcoidosis and their exact pathomechanism remains unknown. In a similar study, pigment overload was noted in 42% of papulo-nodular reactions, suggesting that repeatedly introducing foreign material in the skin may trigger local auto-immunity. Furthermore, they observed a new phenomenon, called the *rush phenomenon*. It is the abrupt and widespread reaction of other black tattoos, triggered by a recent placed tattoo with a papulo-nodular reaction. This phenomenon was observed in 70% of the sarcoidosis group and 28% of the non-sarcoidosis group, which may indicate an even stronger association with sarcoidosis.

As this is one of the few studies in chronic black tattoo reactions, the results need to be confirmed by other studies. This should be done not only for regular decorative tattoos, but also for permanent makeup, as this is a growing trend of tattooing in the last decade. However, little is known about its complications, clinical presentation, relation to systemic autoimmune diseases, aetiology and treatment methods.

### Vasculitis

Isolated cases of localized cutaneous vasculitis have been reported. They occurred shortly after tattooing, however their true relationship remains unknown. In clinical care, additional investigations are required to exclude other causes of vasculitis, such as infection, drug reactions, malignancy or systemic diseases.<sup>62</sup>



**Figure 5.** A papulo-nodular non-sarcoid reaction: nodules in a black tattoo on trunk and extremities.



# HISTOLOGICAL CLASSIFICATION OF INFLAMMATORY COMPLICATIONS: LICHENOID, PSEUDOLYMPHOMATOUS AND GRANULOMATOUS REACTIONS

A clear classification of inflammatory adverse reactions according to the clinical appearance and histopathological patterns remains challenging. The current literature describes various patterns of adverse reactions to tattoos either histologically or clinically. Some studies report histological diagnoses including lichenoid, granulomatous and pseudolymphomatous and less frequently spongiotic reactions, however a clear definite diagnosis is frequently missing. The situation is further complicated as one clinical pattern can have different histological patterns. Furthermore, it is possible that several histopathological pattern can be present in one tattoo complication.

## 1. Lichenoid reactions

Lichenoid reactions are mainly reported to red ink. Lichenoid reactions can be either caused by an allergy or by lichen planus (LP). LP clinically presents with slightly elevated polygonal papules and plaques. A local flare of LP is generally due to the Koebner phenomenon and therefore not necessarily confined to one colour. However, LP can be clinically and histologically indistinguishable from allergic reactions with lichenoid infiltrate. Allergic reactions are generally confined to one colour, mainly red. The reason why remains unclear, as ink compositions are highly diverse.

Thorough physical examination, i.e. oral and nail examination should be performed to rule out LP. Progression of localized lichenoid reaction of the tattooed skin towards a generalized lichenoid reaction has also been described in literature.<sup>63</sup> In most cases the question remains whether the lichenoid reaction is caused by the Koebner phenomenon in an (undiagnosed) LP patient or the lichenoid reaction is caused by the tattoo ink in an allergic patient, as aetiology remains unknown.

## 2. Granulomatous reactions

Besides lichenoid reactions, granulomatous reactions also occur frequently. In the literature the term 'granulomatous reaction' is commonly used as a diagnosis. However, the term is solely histological and there are different possible underlying diagnoses. The differential diagnosis of non-infectious granulomatous reactions includes allergic reactions, foreign body reactions and sarcoidosis. Also, few cases of granulomatous tattoo reactions and associated uveitis have been reported. In these cases, chronic inflammation is limited to the tattooed skin and eyes and no other features of systemic disease, especially sarcoidosis, can be found.<sup>64</sup>

Differentiation between the above-mentioned conditions is difficult. Allergic reactions are difficult to confirm by patch testing as test results are mainly negative.<sup>65</sup> Foreign



body reactions often occur in the borders or corners of a tattoo, where the density of pigment is higher than in other parts of the tattoo. Tattooing over an existing tattoo, also named 'touch-ups', are thought to enhance the risk of pigment overload and thereby a foreign body reaction. As granulomatous skin reactions may be the initial presentation of systemic disease, a comprehensive anamnesis and further investigations (i.e. chest x-ray and laboratory tests) for sarcoidosis are recommended. Sarcoidal tattoo reactions often present in black tattoos and can present months to years after placement. The exact aetiology and pathogenesis of sarcoidosis is unknown.<sup>66</sup> Chronic exposure of the immune system to the ink may stimulate the development of granulomas and might ultimately lead to granulomatous inflammation in an individual who is genetically sensitive to the development of sarcoidosis. This would explain the often long latency period between the placement of the tattoo and the onset of clinical symptoms.

### 3. Pseudolymphomatous reactions

Next to lichenoid and granulomatous inflammation, adverse reactions to tattoo pigments can also show a pseudolymphomatous inflammation. If the reaction is confined to one color, an allergic reaction is more likely. If more tattoo colors are affected, differentiation between an allergic reaction and a true pseudolymphoma is difficult. The exact pathogenesis of pseudolymphoma is unknown. It is theorized that pigment induces chronic inflammation, resulting in polyclonal proliferation of lymphoid B- and T-cells. Histologically, these reactions can appear as a cutaneous T- or B-cell lymphoma however they are clinically benign. Malignant transformation is likely to be rare. However, one case described evolvement into a histologically malignant and immunologically monoclonal B-cell large cell lymphoma in a tattoo.<sup>67</sup>

## NEOPLASMS

In the past decades several cases of malignant melanoma (MM), basal-cell carcinoma (BCC), squamous-cell carcinoma (SCC) and keratoacanthoma of uncertain malignancy (KA) in tattoos have been reported.<sup>68,69</sup> Moreover tattoo ink can contain potential carcinogenic substances, such as aromatic amines and polycyclic aromatic hydrocarbons.<sup>17</sup> This raises the question whether there is an association between tattooing and the development of neoplasms (fig. 6). Besides MM, BCC, SCC and KA, isolated cases of rare cutaneous malignancies, including dermatofibrosarcoma protuberans, cutaneous leiomyosarcoma and cutaneous lymphoma, have been reported. Kluger and Koljonen showed that melanoma and BCC are more prevalent on dark coloured tattoos while SCC, KA and pseudo-epitheliomatous hyperplasia mainly appeared on red tattoos.<sup>70</sup>

Carcinogenesis is in general a multifactorial process. Numerous factors have been identified to contribute to neoplasms occurring in tattooed areas. Among them are the injection of potential carcinogenic substances, trauma induced by the tattooing procedure, chronic inflammatory response to foreign material in the skin, UV-radiation and



**Figure 6.** A nodular and superficial basal-cell carcinoma in a tattoo on the right shoulder.

especially genetic predisposition.<sup>68</sup> Furthermore a delay in diagnosing can occur. A tattoo can mask the appearance of skin lesions and the development of neoplasms, thereby complicating thorough clinical evaluation of the skin. This potentially may cause a delay in diagnosing. Moreover, tattooing over a nevus might induce a trauma and has been thought to induce dysplasia or potentially mask signs of atypical nevi.

So far, in light of the few reported cases of cutaneous malignancies in tattoos compared to all tattooed individuals worldwide, the association has to be interpreted as coincidental. However large-scale studies are needed to assess whether tattooing is an independent risk factor for cutaneous malignancies. This may be difficult because the long latency period of developing cancer would require a big cohort to prove a causal correlation. Considering the abovementioned considerations, it is reasonable to refrain from tattooing on nevi. Certainly, when it comes to larger or congenital melanocytic nevi.

Benign neoplasms, like dermatofibroma, seborrheic keratosis, epidermal cysts, milia and pseudo-epitheliomatous hyperplasia have also been reported. However, cases are only rarely published. Histological changes seen in pseudo-epitheliomatous hyperplasia are often difficult to distinguish from SCC and KA.<sup>70</sup> The number of reported benign neoplasm in tattoos is likely to be an underrepresentation.

## **MISCELLANEOUS CUTANEOUS COMPLICATIONS**

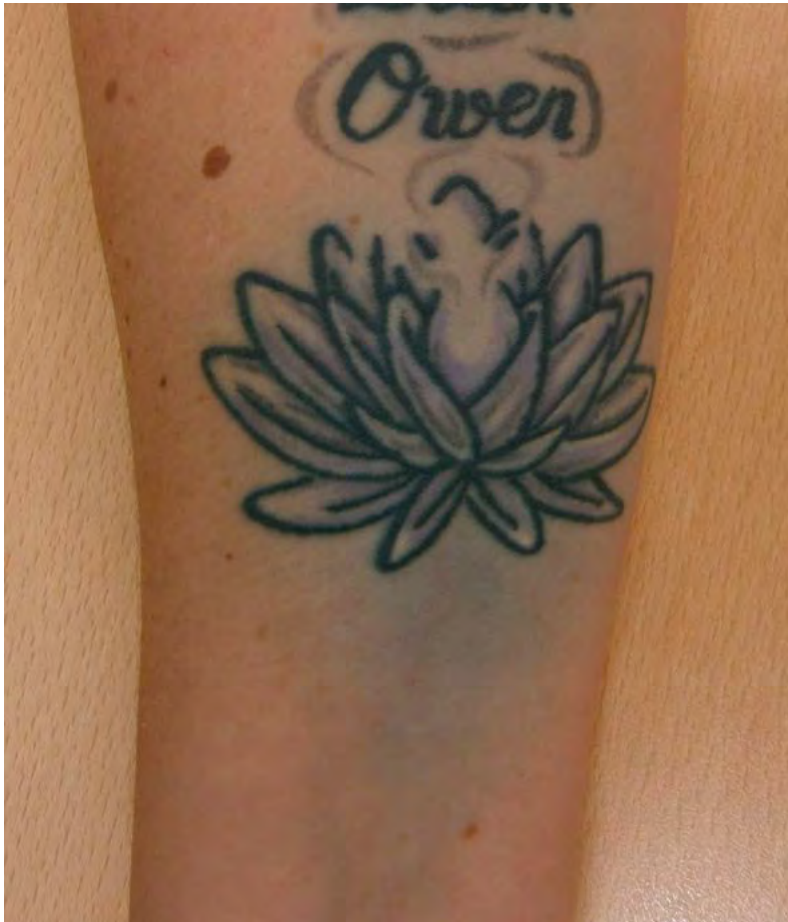### **Misapplication, pigment migration and pigment fanning**

Other common adverse events in tattoos, frequently causing dissatisfaction, include misapplication (form and color), pigment migration, fading or fanning.<sup>71,72</sup> These adverse

events are more frequently seen in permanent make-up and may distort the appearance. Pigment migration has also been reported after local injection with anesthetics prior to laser tattoo removal. This may be caused by numerous injections in the skin creating tunnels in which the ink could spread into the surrounding skin.<sup>73</sup>

### Tattoo blow-out

A tattoo blow-out is rarely described in the literature.<sup>74,75</sup> It describes an adverse reaction in which the tattoo pigment disperses outside the borders of the original tattoo caused by too deeply injected ink into subcutaneous tissue (fig. 7). It may rapidly appear around the tattoo after its completion. Likewise, natural aging of a tattoo will result in blurry outer lines of the tattoo, however should not be confused with a tattoo blow-out which occurs much faster.<sup>31</sup>



**Figure 7.** Tattoo blow-out: dispersed dark blue pigment in the distal part of the tattoo on the lower arm.

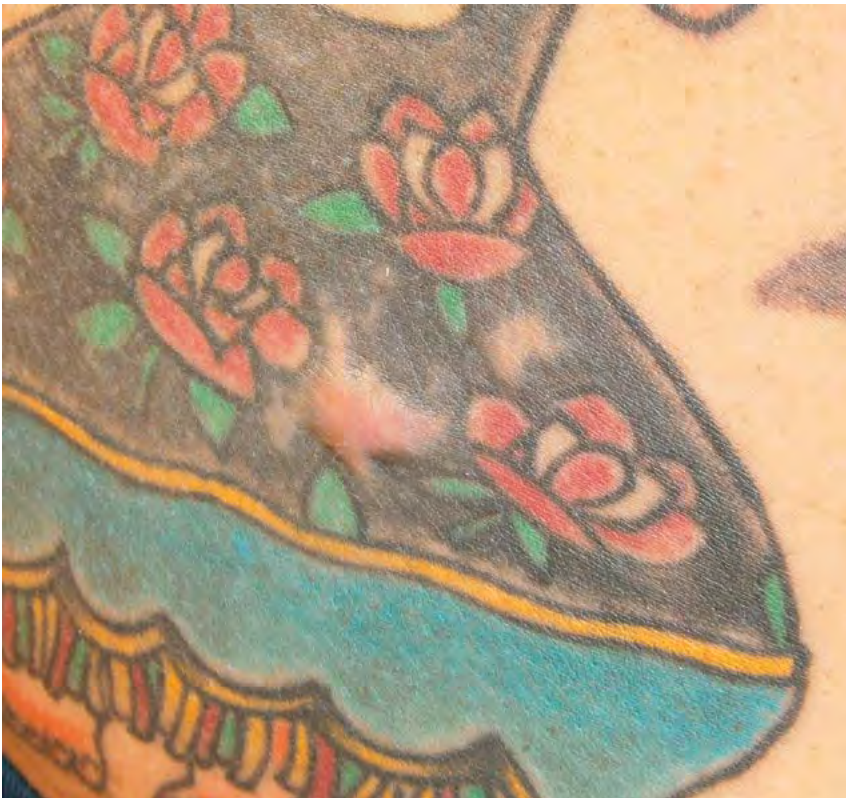
## Hypertrophic scars and keloids

Tattooing could be considered as a massive trauma to the skin which could result in hypertrophic scars or keloids, however surprisingly this is rarely reported.<sup>76</sup> Nonetheless, one of the patients in our clinic was consulted because of keloid on the back of an individual who had a multicolored tattoo that was set in Brazil (fig. 8). This patient did not have a history of keloid or wound healing disorders. Keloids are more frequent in patients with darker skin type and predilection sites include sternum, neck and earlobes.

## Neuro-sensory complications

Sometimes patients develop uncomprehended pain or itch in a tattoo. In these cases, generally, no clinical or histological abnormalities are found.

One case of complex regional pain syndrome in an individual with a tattoo on the wrist has been reported. Possibly the location of the tattoo in this case is crucial as the cutaneous branch of the median nerve is superficial at the wrist. It is presumed that substances of the ink affected the C-fibers of the sensory nerves.<sup>77</sup> However, coincidence cannot be ruled out in these rare cases.



**Figure 8.** A skin colored soft node in a black, green, blue and red tattoo on the back: keloid.

## Cutaneous complications during magnetic resonance imaging

Several case reports describe individuals with tattoos or permanent-make up experiencing cutaneous reactions after undergoing magnetic resonance imaging (MRI), such as skin irritation, swelling and burning.<sup>78</sup> Furthermore, tattoos, especially permanent make-up containing metallic pigments, may interfere with the quality of MRI and may cause image artifacts. There is a tendency for these problems to occur whenever pigments that contain magneto-ferrous compounds are used. The exact causative mechanism is unknown. However, as symptoms are transient and relatively minor, individuals should not be restrained from undergoing MRI.

## Photo-induced reactions

Reactions to ultraviolet(UV)-light are mainly described in tattoos containing cadmium sulfide. This metal salt is present in traditional yellow and red pigments. Photo-induced reactions to cadmium sulfide manifest as erythematous and edematous lesions. Little is known about the exact pathomechanism. These reactions are thought to be photo-toxic and should be treated as such.<sup>20</sup>

However, tattoo inks and pigments underwent a major change from the use of inorganic pigments to organic pigments that are mainly composed out of azo-dyes. Due to the less frequent use of cadmium sulfide in tattoo ink, the abovementioned phototoxic reactions are expected to occur less frequently nowadays.

Hutton Carlsen and Serup performed a study on the beach, directly interviewing sunbathing tattooed individuals. Remarkably, 52% of all surveyed individuals mentioned sun as the triggering factor of tattoo irritation. Reactions to sunlight were mainly reported in red tattoos and could switch on and off in seconds. The causative mechanism of these photo-toxic reaction is thought to be the induction of reactive oxygen species (ROS) due to a photochemical reaction to pigment. ROS may interact with DNA, proteins or lipids, thereby compromising their normal function and mediate symptoms such as pain, itch or even cell death. Preventive measures include covering the tattoos from UV-light or the use of sunscreen.

Incidental cases of granulomatous reactions to 'invisible' blacklight or UV-light accentuated tattoos have been reported. 'Invisible' tattoo ink is composed of substances, which fluorescence under the exposure to UV-light. The differential diagnosis of non-infectious granulomatous reactions consists of allergic reactions, foreign body reactions and sarcoidosis, as mentioned above.<sup>79,80</sup> Likewise, in our Academic Tattoo Clinic we encountered a patient with swelling and pruritis in an 'invisible' blacklight tattoo after sun exposure. Symptoms resolved after the use of sunscreen and coverage of the affected skin area.

In conclusion, this overview illustrates the wide range of morphological changes and histological patterns related to cutaneous adverse reactions that may occur after tattooing. Most of tattoo adverse reactions are non-life-threatening, however potential serious skin

conditions can occur. Adverse reactions can be divided into four categories: infections, inflammatory reactions, neoplasms and miscellaneous complications. It is difficult to estimate the true incidence of tattoo related adverse reactions, as no registry is available. The classification of the clinical signs and histopathological patterns into all-embracing entities is still unclear and challenging. However, this overview gives clinicians tools to recognize short- and long-term tattoo adverse reactions. It is important for tattoo artists and clients to be well informed about potential complications. More research should be performed to classify tattoo reactions, reveal its pathomechanisms and study potential treatment options. As the popularity of tattoos is broad and rising, new studies of adverse events are important, especially in high-risk groups such as patients with auto-immune diseases. This research is not only important for clinicians, but also for non-clinicians such as tattoo ink producers and regulatory authorities when it comes to production and legislation of tattoo inks.

In the end, all of this research should lead to enhanced safety of tattooing.

*Note: all photographs were published with written informed consent of the patients.*

## AIMS AND OUTLINE OF THIS THESIS

Tattoos are a broad subject, and main subtopics to discuss are: dermatological and systemic complications, tattoo technique and craftsmanship, cultural heritage, history of tattooing, contra-indications of tattooing, regulation and law, ingredients and production of tattoo inks, tattoo removal etc. However, the primary goal of this thesis is to gain more clinical knowledge about tattoo complications, resulting in a more efficient and high-quality dermatologic care for these patients. Therefore, this thesis will focus on the dermatological complications of tattoos.

In the **General introduction** an overview of tattoo adverse events is presented. In the first three chapters the clinical aspects of tattoo complications are discussed. **Chapter 2** deals with the clinical aspects of red tattoo reactions and **Chapter 3** investigates the prevalence of tattoos in sarcoidosis patients and associated adverse events. Granulomatous reactions in permanent makeup are discussed in **Chapter 4**.

The Chapters 5-7 focus on diagnostics and pathomechanisms of tattoo complications. The histopathology of red tattoo reactions is presented in **Chapter 5**, followed by research on the skin sensitization potential of five tattoo inks in vitro by using reconstructed human skin (RHS) and the contact sensitization biomarker interleukin (IL)-18 in reconstructed human skin model in **Chapter 6**. **Chapter 7** investigates the quantification of cutaneous allergic tattoo reactions using 3D optical imaging. The last Chapters focus on the treatment and course of tattoo complications. **Chapter 8** concerns a retrospective study about ablative laser therapy of allergic red tattoo reactions and other treatment options will also be discussed. In **Chapter 9** A-C, cases of treatment and course of respectively tattoo associated uveitis, allergic reaction to permanent makeup of the lips and mycobacterial tattoo infection are presented.

## REFERENCES

1. Islam PS, Chang C, Selmi C, et al. Medical Complications of Tattoos: A Comprehensive Review. *Clin Rev Allergy Immunol*. 2016;50(2):273-286. doi:10.1007/s12016-016-8532-0
2. Laumann AE, Derick AJ. Tattoos and body piercings in the United States: a national data set. *J Am Acad Dermatol*. 2006;55(3):413-421. doi:10.1016/j.jaad.2006.03.026
3. Karagas MR, Wasson JH. A World Wide Web-based survey of nonmedical tattooing in the United States. *J Am Acad Dermatol*. 2012;66(1):e13-e14. doi:10.1016/j.jaad.2010.11.038
4. Stirn A, Hinz A, Brähler E. Prevalence of tattooing and body piercing in Germany and perception of health, mental disorders, and sensation seeking among tattooed and body-pierced individuals. *J Psychosom Res*. 2006;60(5):531-534. doi:10.1016/j.jpsychores.2005.09.002
5. Piccinini P, Pakalin S, Contor L, Bianchi I. Safety of tattoos and permanent make-up. Adverse health effects and experience with the Council of Europe Resolution (2008)1. Luxembourg: Publications Office of the European Union; 2016. doi: 10.2788/177900
6. Renzoni A, Pirrera A, Novello F, et al. The tattooed population in Italy: a national survey on demography, characteristics and perception of health risks. *Ann Ist Super Sanita*. 2018;54(2):126-136. doi:10.4415/ANN\_18\_02\_08
7. Bundesinstitut für Risikobewertung. BfR-Verbrauchermonitor 2018, Spezial Tattoos. BfR; 2018. Retrieved from <https://www.bfr.bund.de/cm/350/bfr-verbrauchermonitor-2018-spezial-tattoos.pdf>.
8. Bäuml W. Tattoos and Their Potential Health Consequences. *Dtsch Arztebl Int*. 2016;113(40):663-664. doi:10.3238/arztebl.2016.0663
9. Breuner CC, Levine DA; COMMITTEE ON ADOLESCENCE. Adolescent and Young Adult Tattooing, Piercing, and Scarification [published correction appears in *Pediatrics*. 2018 Jan 31;:]. *Pediatrics*. 2017;140(4):e20163494. doi:10.1542/peds.2017-1962
10. Kluger N. Epidemiology of tattoos in industrialized countries. *Curr Probl Dermatol*. 2015;48:6-20. doi:10.1159/000369175
11. Griffiths CE, Barker J, Bleiker TO. *Rook's Textbook of Dermatology*. Ninth edition. Oxford, United Kingdom: Wiley Blackwell; 2016.
12. Shannon-Missal L. Tattoo takeover: three in ten Americans have a tattoo, and most don't stop at one. Harris Poll No. 12. 2016. Retrieved from: <https://theharrispoll.com/tattoos-can-take-any-number-of-forms-from-animals-to-quotes-to-cryptic-symbols-and-appear-in-all-sorts-of-spots-on-our-bodies-some-visible-in-everyday-life-others-not-so-much-but-one-thi/>. Accessed April 8, 2020.
13. Schoots W. *Tatoeages en piercings, een analyse van OBiN-gegevens*. Amsterdam: VeiligheidNL; 2013.
14. Laux P, Tralau T, Tentschert J, et al. A medical-toxicological view of tattooing. *Lancet*. 2016;387(10016):395-402. doi:10.1016/S0140-6736(15)60215-X
15. Schmidt H. *Tatoveringer – kulturhistoriske, kunstneriske og medicinske aspekter*. Copenhagen: Løvens Kemiske Fabrik;1967.p24–34.
16. Piccinini, P, Bianchi I, Pakalin S, Senaldi C. Safety of tattoos and permanent make-up. Compilation of information on legislative framework and analytical methods. Luxembourg: Publications Office of the European Union; 2015. doi:10.2788/542617.



17. EC. Resolution ResAP(2003)2 on tattoos and permanent make-up. 2003. Retrieved from [https://search.coe.int/cm/Pages/result\\_details.aspx?ObjectId=09000016805df8e5](https://search.coe.int/cm/Pages/result_details.aspx?ObjectId=09000016805df8e5). Accessed 11 April 2020.
18. EC. Resolution ResAP(2008)1 on requirements and criteria for the safety of tattoos and permanent make-up. 2008. Retrieved from <https://rm.coe.int/16805d3dc4>. Accessed 11 April 2020.
19. European Chemicals Agency. Substances in tattoo inks and permanent make up. Helsinki: ECHA; 2019.
20. Kazandjieva J, Tsankov N. Tattoos: dermatological complications. *Clin Dermatol*. 2007;25(4):375-382. doi:10.1016/j.clindermatol.2007.05.012
21. Klügl I, Hiller KA, Landthaler M, Bäuml W. Incidence of health problems associated with tattooed skin: a nation-wide survey in German-speaking countries. *Dermatology*. 2010;221(1):43-50. doi:10.1159/000292627
22. Høgsberg T, Hutton Carlsen K, Serup J. High prevalence of minor symptoms in tattoos among a young population tattooed with carbon black and organic pigments. *J Eur Acad Dermatol Venereol*. 2013;27(7):846-852. doi:10.1111/j.1468-3083.2012.04590.x
23. Hutton Carlsen K, Serup J. Photosensitivity and photodynamic events in black, red and blue tattoos are common: A 'Beach Study'. *J Eur Acad Dermatol Venereol*. 2014;28(2):231-237. doi:10.1111/jdv.12093
24. Liszewski W, Kream E, Helland S, Cavigli A, Lavin BC, Murina A. The Demographics and Rates of Tattoo Complications, Regret, and Unsafe Tattooing Practices: A Cross-Sectional Study. *Dermatol Surg*. 2015;41(11):1283-1289. doi:10.1097/DSS.0000000000000500
25. Brady BG, Gold H, Leger EA, Leger MC. Self-reported adverse tattoo reactions: a New York City Central Park study. *Contact Dermatitis*. 2015;73(2):91-99. doi:10.1111/cod.12425
26. Høgsberg T, Saunte DM, Frimodt-Møller N, Serup J. Microbial status and product labelling of 58 original tattoo inks. *J Eur Acad Dermatol Venereol*. 2013;27(1):73-80. doi:10.1111/j.1468-3083.2011.04359.x
27. Nederlandse Voedsel- en Warenautoriteit. Resultaten onderzoek van kleurstoffen voor tatoeages en permanente make-up in de periode 2008-2013. Utrecht: NVWA; 2014, 16 p.
28. Wenzel SM, Rittmann I, Landthaler M, Bäuml W. Adverse reactions after tattooing: review of the literature and comparison to results of a survey. *Dermatology*. 2013;226(2):138-147. doi:10.1159/000346943
29. Kluger N. Acute complications of tattooing presenting in the ED. *Am J Emerg Med*. 2012;30(9):2055-2063. doi:10.1016/j.ajem.2012.06.014
30. Centers for Disease Control and Prevention (CDC). Methicillin-resistant *Staphylococcus aureus* skin infections among tattoo recipients--Ohio, Kentucky, and Vermont, 2004-2005. *MMWR Morb Mortal Wkly Rep*. 2006;55(24):677-679.
31. Simunovic C, Shinohara MM. Complications of decorative tattoos: recognition and management. *Am J Clin Dermatol*. 2014;15(6):525-536. doi:10.1007/s40257-014-0100-x
32. Conaglen PD, Laurenson IF, Sergeant A, Thorn SN, Rayner A, Stevenson J. Systematic review of tattoo-associated skin infection with rapidly growing mycobacteria and public health investigation of a cluster in Scotland, 2010. *Euro Surveill*. 2013;18(32):20553. Published 2013 Aug 8. doi:10.2807/1560-7917.es2013.18.32.20553
33. Velez L, Harb J, Anuszewski S, Wesson S. Cutaneous *Mycobacterium massiliense* infection from tattooing: a common yet under-reported and persistent epidemic hazard

- for dermatologists. *BMJ Case Rep.* 2018;2018:bcr2017222762. Published 2018 Jan 12. doi:10.1136/bcr-2017-222762
34. Kluger N, Muller C, Gral N. Atypical mycobacteria infection following tattooing: review of an outbreak in 8 patients in a French tattoo parlor. *Arch Dermatol.* 2008;144(7):941-942. doi:10.1001/archderm.144.7.941
  35. Wong HW, Tay YK, Sim CS. Papular eruption on a tattoo: a case of primary inoculation tuberculosis. *Australas J Dermatol.* 2005;46(2):84-87. doi:10.1111/j.1440-0960.2005.00147.x
  36. Ghorpade A. Inoculation (tattoo) leprosy: a report of 31 cases. *J Eur Acad Dermatol Venereol.* 2002;16(5):494-499. doi:10.1046/j.1468-3083.2002.00548.x
  37. Hayes MO, Harkness GA. Body piercing as a risk factor for viral hepatitis: an integrative research review. *Am J Infect Control.* 2001;29(4):271-274. doi:10.1067/mic.2001.114402
  38. Brajac I, Loncarek K, Stojni -Sosa L, Gruber F. Delayed onset of warts over tattoo mark provoked by sunburn. *J Eur Acad Dermatol Venereol.* 2005;19(2):247-248. doi:10.1111/j.1468-3083.2004.01121.x
  39. Kluger N, Saarinen K. *Aspergillus fumigatus* infection on a home-made tattoo. *Br J Dermatol.* 2014;170(6):1373-1375. doi:10.1111/bjd.12859
  40. van der Bent SA, Wolkerstorfer A, Rustemeyer T. Huidafwijkingen bij tatoeages [Adverse Reactions to Tattoos]. *Ned Tijdschr Geneesk.* 2016;160:A9808.
  41. Carlsen KH, Serup J. Chronic tattoo reactions cause reduced quality of life equaling cumbersome skin diseases. *Curr Probl Dermatol.* 2015;48:71-75. doi:10.1159/000369644
  42. Serup J, Sepehri M, Hutton Carlsen K. Classification of Tattoo Complications in a Hospital Material of 493 Adverse Events. *Dermatology.* 2016;232(6):668-678. doi:10.1159/000452148
  43. Goldstein N. IV. Complications from tattoos. *J Dermatol Surg Oncol.* 1979;5(11):869-878. doi:10.1111/j.1524-4725.1979.tb00770.x
  44. Brose, W. Neue Tätowierungsphänomene. *Derm Wschr.* 1927;84:461-463.
  45. Yoong C, Vun YY, Spelman L, Muir J. True blue football fan: tattoo reaction confined to blue pigment. *Australas J Dermatol.* 2010;51(1):21-22. doi:10.1111/j.1440-0960.2009.00608.x
  46. van der Bent SAS, Berg T, Karst U, Sperling M, Rustemeyer T. Allergic reaction to a green tattoo with nickel as a possible allergen. *Contact Dermatitis.* 2019;81(1):64-66. doi:10.1111/cod.13226
  47. González-Villanueva I, Álvarez-Chinchilla P, Silvestre JF. Allergic reaction to 3 tattoo inks containing Pigment Yellow 65. *Contact Dermatitis.* 2018;79(2):107-108. doi:10.1111/cod.13004
  48. Serup J, Carlsen KH, Sepehri M. Tattoo complaints and complications: diagnosis and clinical spectrum. *Curr Probl Dermatol.* 2015;48:48-60. doi:10.1159/000369645
  49. Serup J. How to Diagnose and Classify Tattoo Complications in the Clinic: A System of Distinctive Patterns. *Curr Probl Dermatol.* 2017;52:58-73. doi:10.1159/000450780
  50. Price A, Tavazoie M, Meehan SA, Leger M. Id reaction associated with red tattoo ink. *Cutis.* 2018;102(5):E32-E34.
  51. van der Bent SAS, Maijer KI, Rustemeyer T. Image Gallery: Hyperkeratotic hypersensitivity reaction to red pigment tattoo. *Br J Dermatol.* 2017;177(6):e350. doi:10.1111/bjd.16040
  52. Høgsberg T, Thomsen BM, Serup J. Histopathology and immune histochemistry of red tattoo reactions. Interface dermatitis is the lead pathology, with increase in T-lymphocytes and Langerhans cells suggesting an allergic pathomechanism. *Skin Res Technol.* 2015;21(4):449-458. doi:10.1111/srt.12213

53. Forbat E, Al-Niaimi F. Patterns of Reactions to Red Pigment Tattoo and Treatment Methods. *Dermatol Ther (Heidelb)*. 2016;6(1):13-23. doi:10.1007/s13555-016-0104-y
54. Thum CK, Biswas A. Inflammatory complications related to tattooing: a histopathological approach based on pattern analysis. *Am J Dermatopathol*. 2015;37(1):54-66. doi:10.1097/DAD.0b013e3182974558
55. Sepehri M, Jørgensen B, Serup J. Introduction of dermatome shaving as first line treatment of chronic tattoo reactions. *J Dermatolog Treat*. 2015;26(5):451-455. doi:10.3109/09546634.2014.999021
56. Millán-Cayetano JF, Alegre-Sánchez A, Boixeda P. Treatment of red tattoo reaction using CO2 laser. *Lasers Med Sci*. 2018;33(5):1171-1173. doi:10.1007/s10103-017-2229-3
57. Hutton Carlsen K, Serup J. Tattooing may cause life-threatening latex allergy. *J Eur Acad Dermatol Venereol*. 2016;30(7):1242-1244. doi:10.1111/jdv.13171
58. Bregnbak D, Johansen JD, Zachariae C. Contact dermatitis caused by panthenol used for aftercare treatment of a new tattoo. *Contact Dermatitis*. 2016;75(1):50-52. doi:10.1111/cod.12544
59. Köbner H. Zur aetiologie der psoriasis. *Vjschr Dermatol* 1876;3:559-61.
60. Horner KL, Chien AJ, Edenholm M, Hornung RL. Winnie the Pooh and psoriasis too: an isomorphic response of guttate psoriasis in a tattoo. *Pediatr Dermatol*. 2007;24(5):E70-E72. doi:10.1111/j.1525-1470.2007.00445.x
61. Sepehri M, Hutton Carlsen K, Serup J. Papulo-Nodular Reactions in Black Tattoos as Markers of Sarcoidosis: Study of 92 Tattoo Reactions from a Hospital Material. *Dermatology*. 2016;232(6):679-686. doi:10.1159/000453315
62. Kluger N. Tattoo-induced vasculitis: is it really the ink?. *Am J Emerg Med*. 2011;29(3):347. doi:10.1016/j.ajem.2010.11.009
63. Kluger N. Cutaneous Complications Related to Tattoos: 31 Cases from Finland. *Dermatology*. 2017;233(1):100-109. doi:10.1159/000468536
64. Adam MK, Rahimy E, Dunn JP. Tattoo-associated uveitis. *JAMA Ophthalmol*. 2015;133(4):e144543. doi:10.1001/jamaophthalmol.2014.4543
65. Serup J, Hutton Carlsen K. Patch test study of 90 patients with tattoo reactions: negative outcome of allergy patch test to baseline batteries and culprit inks suggests allergen(s) are generated in the skin through haptization. *Contact Dermatitis*. 2014;71(5):255-263. doi:10.1111/cod.12271
66. Kluger N. Sarcoidosis on tattoos: a review of the literature from 1939 to 2011. *Sarcoidosis Vasc Diffuse Lung Dis*. 2013;30(2):86-102. Published 2013 Aug 1.
67. Sanguenza OP, Yadav S, White CR Jr, Brazier RM. Evolution of B-cell lymphoma from pseudolymphoma. A multidisciplinary approach using histology, immunohistochemistry, and Southern blot analysis. *Am J Dermatopathol*. 1992;14(5):408-413. doi:10.1097/00000372-199210000-00006
68. Kluger N, Koljonen V. Tattoos, inks, and cancer. *Lancet Oncol*. 2012;13(4):e161-e168. doi:10.1016/S1470-2045(11)70340-0
69. Milam EC, Leger MC, McClain SA, Brusteim DM. Concurrent keratoacanthomas and nonsarcoidal granulomatous reactions in new and preexisting tattoos. *Cutis*. 2019;103(2):E39-E42.
70. Kluger N, Plantier F. Pseudo-epitheliomatous hyperplasia, keratoacanthoma, and squamous cell carcinoma occurring within tattoos: diagnostic issues. *J Am Acad Dermatol*. 2007;57(5):901-902. doi:10.1016/j.jaad.2007.06.021
71. De Cuyper C. Permanent makeup: indications and complications. *Clin Dermatol*. 2008;26(1):30-34. doi:10.1016/j.clindermatol.2007.10.009

72. Hutton Carlsen K, Sepehri M, Serup J. Tattooist-Associated Tattoo Complications: "Overworked Tattoo," "Pigment Overload" and Infections Producing Early and Late Adverse Events. *Dermatology*. 2020;236(3):208-215. doi:10.1159/000501962
73. Ortiz AE, Avram MM. Redistribution of ink after laser tattoo removal. *Dermatol Surg*. 2012;38(10):1730-1731. doi:10.1111/j.1524-4725.2012.02560.x
74. Kluger N. Blurry halos around tattoos: a new case of "tattoo blow-out". *Int J Dermatol*. 2014;53(1):e44-e46. doi:10.1111/j.1365-4632.2012.05724.x
75. Kluger N. Blurry halos after tattooing (tattoo blowouts): a review of 16 cases. *J Eur Acad Dermatol Venereol*. 2018;32(12):e466-e468. doi:10.1111/jdv.15069
76. Kluger N, Bosonnet S. Keloid occurring in a tattoo. *Ann Dermatol Venereol*. 2017;144(6-7):455. doi:10.1016/j.annder.2017.01.019
77. Morte PD, Magee LM. Hyperalgesia after volar wrist tattoo: a case of complex regional pain syndrome?. *J Clin Neuromuscul Dis*. 2011;12(3):118-121. doi:10.1097/CND.0b013e3181dd344c
78. Tope, W. D., & Shellock, F. G. (2002). Magnetic resonance imaging and permanent cosmetics (tattoos): survey of complications and adverse events. *Journal of magnetic resonance imaging : JMRI*, 15(2), 180–184. <https://doi.org/10.1002/jmri.10049>
79. Tsang M, Marsch A, Bassett K, High W, Fitzpatrick J, Prok L. A visible response to an invisible tattoo. *J Cutan Pathol*. 2012;39(9):877-880. doi:10.1111/j.1600-0560.2012.01961.x
80. Schumann T, Peitsch WK, Géraud C, Goerdts S, Leverkus M. Ultraviolet light tattoo complicated by granulomatous inflammation. *J Am Acad Dermatol*. 2011;65(4):e124-e126. doi:10.1016/j.jaad.2011.03.028





## **CLINICAL ASPECTS**

2



# **RED TATTOO REACTIONS, A PROSPECTIVE COHORT ON CLINICAL ASPECTS**

---

Sebastiaan A.S. van der Bent, Ruben W. de Winter,  
Albert Wolkerstorfer, Thomas Rustemeyer

*Journal of the European Academy of Dermatology and Venereology. 2019;33(10):e384-e386.*



Tattooing has become increasingly popular across the globe. In 2016, 12% of Europeans were tattooed.<sup>1</sup> However, complications of tattooing can occur in which mainly red tattoo pigments are involved.<sup>2</sup> These reactions to red tattoos are chronic, cause itch and lead to a reduced quality of life.<sup>3</sup> The clinical presentation includes thickening, hyperkeratosis or ulceration, confined to the red tattooed skin.<sup>4,5</sup> Nonetheless, little is known about its aetiology, eliciting factors and clinical aspects.

A prospective study was conducted in patients with cutaneous reactions to red tattoos at the Department of Dermatology of the VU University Medical Center during 2014-2018. Institutional Review Board approval was obtained. A red tattoo reaction was defined as a chronic reaction, affecting one or more tattoos, and restricted to red or nuances of red. The study focused on eliciting factors and clinical aspects. Data were obtained by medical history and physical examination. In the categorization of the clinical presentation of the tattoo reactions the classification of Serup et al. was used.<sup>2</sup> Histopathology was obtained to exclude other diagnoses such as scarring, infections or sarcoidosis. No routine patch testing was performed.

Overall, 101 patients were included (Table 1). The most frequently affected tattoo locations were the distal extremities (77%). Other affected locations were the face (5%) and proximal extremities. Patients reported itch in 94% and pain in 17%. All patients had symptoms for more than 3 months. Worsening of symptoms was self-reported in 32% after sun exposure, defined as unprotected exposure of the tattoo in the outdoor sun for a nonspecified time period. Forty-three percent of the patients developed symptoms within 1 month of getting the tattoo and 24% after 1 year up to 7 years. The average time of developing symptoms was 12 months. In 23% of the 43 patients with other older red tattoos, simultaneously symptoms occurred in the older red tattoos suggesting 'cross reactivity'. Clinically, we observed a plaque, hyperkeratotic, and ulcero-necrotic pattern in 92%, 3% and 5% respectively (Figure 1) of all patients. In 87 patients histopathology was obtained. A skin biopsy was refused in 14 patients. Histology included lichenoid, pseudolymphomatous or granulomatous inflammation. In 12 patients a granulomatous inflammation was found but chest X-ray and serum angiotensin-converting enzyme revealed no signs of sarcoidosis.

Currently little is known about the aetiology of red tattoo reactions. As these reactions are sharply confined to exclusively the red tattooed area, an allergy to the injected tattoo pigments is thought to be the underlying cause. Furthermore, an in vitro study showed that tattoo inks were able to cause an inflammatory IL-18 response.<sup>6</sup> In this study we observed a substantial time span between tattooing and onset of symptoms. Together with the emergence of cross reactive red tattoo reactions, these findings suggest a delayed type allergic reaction. In our study we remarkably found that allergic tattoo reactions were mainly present in tattoos localized on the extremities (91%). In comparison, in a nation-wide survey in Germany, they found that tattoos were located on the extremities in only 41%.<sup>7</sup> Moreover, we found a relatively high percentage of reactions on sun exposed areas: the distal extremities and face (83%). Additionally, a notable number of patients (32%) explicitly

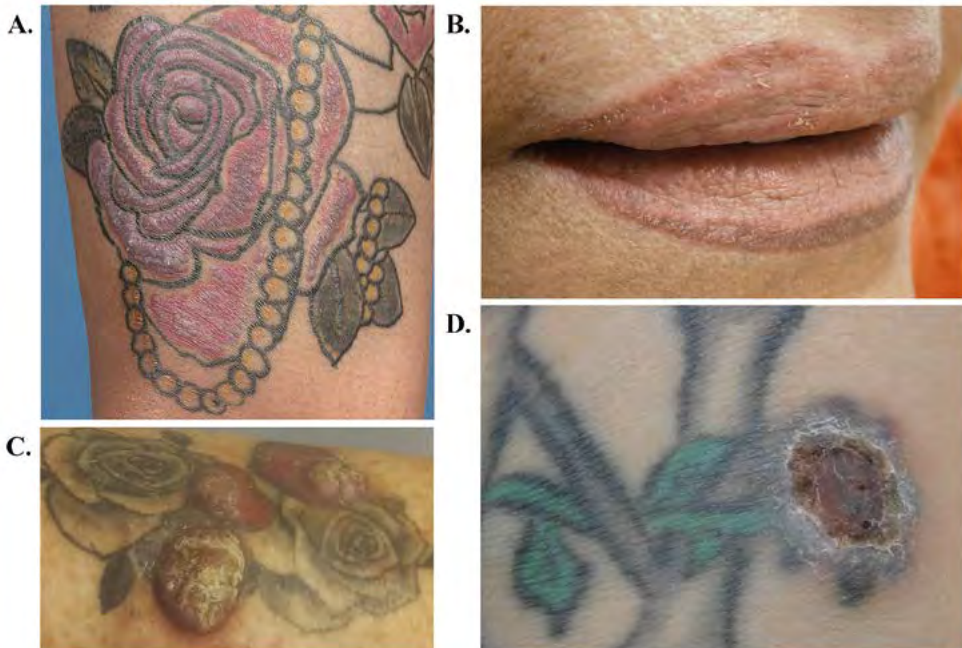
**Table 1.** Clinical patient characteristics.

Parameter	
Patients, N	101
Age, y, mean (SD)	44.0 (12.7)
Sex, n (%)	
Male	23 (22.8)
Female	78 (77.2)
Tattoo location, n (%)*	
Distal upper extremities	36 (35.0)
Proximal upper extremities	13 (12.6)
Distal lower extremities	43 (41.7)
Proximal lower extremities	2 (1.9)
Trunk	4 (3.9)
Face	5 (4.9)
Tattoo setting, n (%)	
Amateur	4 (4.0)
Professional	97 (96.0)
Cross reactivity, n (%)	
Other red tattoos	43 (42.6)
Other symptomatic red tattoos	10 (9.9)
Unknown	3 (3.0)
Symptoms, n (%)	
Itch	95 (94.1)
Pain	17 (16.8)
Exacerbation after sun exposure, n (%)	
Yes	32 (31.7)
No	56 (55.4)
Unknown	13 (12.9)
Tattoo ink brand, n (%)	
Intenze	17 (16.8)
Eternal	5 (5.0)
Starbrite	2 (2.0)
Fusion ink	2 (2.0)
Intenze and Eternal	3 (3.0)
Unretrievable	62 (61.4)
Time onset of symptoms, n (%)	
< 1 months	43 (42.6)
1-3 months	12 (11.9)
3-6 months	14 (13.9)
6-12 months	8 (7.9)
1-2 years	6 (5.9)
2-5 years	14 (13.9)
>5 years	4 (4.0)
Clinical presentation, n (%)	
Plaque elevation	93 (92.1)
Excessive hyperkeratotic	3 (3.0)

**Table 1.** (continued)

Parameter		
Ulceronecrotic		5 (5.0)
Histology, n (%)		
Lichenoid		20 (19.8)
Pseudolymphomatous		13 (12.9)
Granulomatous		12 (11.9)
Combined granulomatous and lichenoid		2 (2.0)
Combined lichenoid and pseudolymphomatous		5 (5.0)
Other		35 (34.7)
No biopsy		14 (13.9)

\* Two patients had a tattoo reaction on a tattoo set at the same time but in different anatomical area (distal lower and distal upper extremities, distal upper and proximal upper extremities).

**Figure 1.** Clinical reaction types of allergic reactions to red tattoos.

- A. Plaque elevation reaction in a red tattoo on the right upper leg.
- B. Plaque elevation in red tattooed lip liner (permanent makeup).
- C. Excessive hyperkeratotic reaction in a red tattoo on the right lower arm.
- D. Ulceronecrotic reaction in an originally red 'flower' tattoo on the right wrist.

report sunlight as a trigger. These findings suggest that sunlight may play a role in forming the allergen. Light is known to cause photochemical cleavage of tattoo pigments *in vitro*, and new cases of a tattoo allergy following treatment with a Q-switch laser have been reported.<sup>8,9</sup>

Altogether, these clinical findings support the hypothesis that red tattoo reactions are caused by a delayed type allergy where the allergen is formed in the dermis through a slow process of haptization.<sup>10</sup> The tattoo pigments may undergo enzymatic processes in a substantial time period in the dermis. As a result, compounds of the tattoo pigments form the allergen that induces a T-cell-mediated reaction. This could explain the great variation in time of onset and the reason why patch testing is generally negative.

Although this study has limitations (monocenter, no photopatch testing) our findings provide more information about the aetiology, eliciting factors and clinical aspects of red tattoo reactions. Further research, such as identification of potential pigments and photopatch testing, should be performed to reveal more about its aetiology and possible allergens.

## REFERENCES

1. Piccinini P, Pakalin S, Contor L, Bianchi L, Senaldi C. Safety of tattoos and permanent make-up: final report. EUR27947, 2016.
2. Serup J, Sepehri M, Hutton Carlsen K. Classification of Tattoo Complications in a Hospital Material of 493 Adverse Events. *Dermatology* 2016;232:668-78.
3. Hutton Carlsen K, Serup J. Patients with tattoo reactions have reduced quality of life and suffer from itch. *Skin Res Technol.* 2015;21:101–7.
4. Van der Bent SA, Wolkerstorfer A, Rustemeyer T. Cutaneous adverse reactions to tattoos. *Ned Tijdschr Geneeskd.* 2016;160:A9808.
5. Van der Bent SAS, Maijer K I, Rustemeyer T. Image Gallery: Hyperkeratotic hypersensitivity reaction to red pigment tattoo. *Br J Dermatol* 2017:e350.
6. Bil W, van der Bent SAS, Spiekstra SW, Nazmi K, Rustemeyer T, Gibbs S. Comparison of the skin sensitization potential of 3 red and 2 black tattoo inks using interleukin-18 as a biomarker in a reconstructed human skin model. *Contact Dermatitis.* 2018;1-10.
7. Klügl I, Hiller KA, Landthaler M, Bäuml W. Incidence of health problems associated with tattooed skin: A nation-wide survey in German-speaking countries. *Dermatology.* 2010;221:43-50.
8. Engel E, Spannberger A, Vasold R, König B, Landthaler M, Bäuml W. Photochemical cleavage of a tattoo pigment by UVB radiation or natural sunlight. 2007;2007(Band 5):583-9.
9. Ashinoff R, Levine VJ, Soter NA. Allergic reactions to tattoo pigment after laser treatment. *Dermatol Surg.* 1995;21:291-4.
10. Serup J, Hutton Carlsen K. Patch test study of 90 patients with tattoo reactions: Negative outcome of allergy patch test to baseline batteries and culprit inks suggests allergen(s) are generated in the skin through haptens. *Contact Dermatitis.* 2014;:255–63.

3



# **TATTOOS AND SELF-REPORTED ADVERSE EVENTS IN SARCOIDOSIS PATIENTS**

---

Sebastian A.S. van der Bent, Marloes J.C. Engel, Esther J. Nossent,  
René E. Jonkers, Albert Wolkerstorfer, Thomas Rustemeyer.

*Journal of the European Academy of Dermatology and Venereology. 2020;34(4):e167-e169.*



Tattoos are currently popular worldwide. However, complications can occur, such as allergic reactions, infections and auto-immune diseases such as sarcoidosis.<sup>1</sup> Sarcoidosis is frequently reported in tattoos and sometimes as its first manifestation.<sup>2</sup> This could be explained by the Köbner phenomenon or the prevailing theory on the etiology of sarcoidosis: environmental factors, such as tattoo pigments, acting as an antigen in people with a genetic predisposition causing cutaneous sarcoidosis. The practical use of tattoos is broad and its demand is high. However, little is known about the prevalence of tattoos and tattoo complications in sarcoidosis patients, as no previous studies have been performed. Furthermore, there is no consensus in the literature about what to advise patients in this matter.<sup>3</sup> The aim of this study is to gather more information about the prevalence of tattoos and tattoo adverse events in sarcoidosis patients.

We conducted a multicenter cross-sectional study, using an online survey among sarcoidosis patients from December 2018 to April 2019 in two academic centers. We included patients, 18-75 years-old, who consulted a dermatologist or pulmonologist at least once in the last two years. By chart, the Sarcoidosis Diagnostic Score was used for diagnose confirmation.<sup>4</sup> Exclusion criteria included an uncertain diagnosis, clinical remission, non-proficiency in the Dutch language and unavailable contact information. The study outcomes were gathered by questionnaire including presence of tattoos, skin type following Fitzpatrick's classification and occurrence of adverse events and its characteristics. Data was collected in Castor EDC and analyzed in SPSS version 25. Approval was obtained of the medical ethical committee.

The database search revealed 638 possible sarcoidosis patients. 295 Patients were excluded. 343 patients received and finally 212 completed the survey (61.8%). Patient characteristics are shown in table 1. In total, 47 (22.2%) were tattooed, mainly on the upper extremities (62.2%). Most patients had one to three tattoos (40.5%) and 54.1% was tattooed before being diagnosed with sarcoidosis. Tattoo adverse events were reported in 21.3% (table 2) of which 70% developed after a year and persisted for more than three months in 40%. Half of the patients consulted a physician. Black ink, and papules and nodules were most frequently reported in 90% respectively 70%. Skin type VI was substantially more reported than other skin types (N=7; 70%,  $p=0.007$ ) (table 2). Of people with tattoos and sarcoidosis with skin types I-III and IV-VI, adverse events were reported in 1/20 (5%) respectively 9/26 (35%). Of people with tattoos and sarcoidosis with skin type VI, 7/15 (47%) reported adverse events.

Our study shows that nearly a quarter of the sarcoidosis patients are tattooed and tattoo adverse events are common (21.3%). In comparison, a recent self-reported study amongst dermatologic patients showed only 10.3% tattoo adverse events.<sup>5</sup> In another study, 27% tattoo adverse events was reported in a random population.<sup>6</sup> Remarkably, 60% reported being tattooed both before and after diagnosed with sarcoidosis, assuming adverse events occurred in people who were predisposed for sarcoidosis.

The exact nature of the reported adverse events could not be identified. However, as cutaneous involvement occurs in 25% of sarcoidosis patients, it is probable that

**Table 2.** Characteristics of total sample, tattooed no AE and tattooed with AE.

Parameter	Total Sample	Tattooed patients	
		Tattooed no AE	Tattooed with AE
Patients, N	212	37	10
Age, y, mean (SD)	52.6 (11.0)	47 (11.2)	40 (8.4)
Sex, n (%)			
Men	120 (56.6)	16 (43.2)	5 (50.0)
Women	92 (43.4)	21 (56.8)	5 (50.0)
Self-reported skin type, n (%)			
I	7 (3.3)	2 (5.4)	0 (0)
II	56 (26.4)	8 (21.6)	1 (10.0)
III	62 (29.2)	10 (27.0)	0 (0)
IV	28 (13.2)	7 (18.9)	2 (20.0)
V	14 (6.6)	2 (5.4)	0 (0)
VI	45 (21.2)	8 (21.6)	7 (70.0)
Correlation of skin type VI and tattoo adverse events			
Skin type VI		Tattooed no AE	Tattooed with AE
Yes		8	7
No		29	3
P value		0.007	

Values in parentheses are percentages

the majority of the tattoo adverse events found are sarcoid.<sup>7</sup> Hence, 70% reported papules and nodules in their tattoo. Clinically, papulo-nodular tattoo reactions are suspect for sarcoidosis. A recent study describes systemic sarcoidosis in 8% of these reactions.<sup>8</sup>

Skin type is strongly correlated with adverse events in our study. Whereas 15/47 (31%) of the patients with tattoos and sarcoidosis had type VI skin, these patients experienced 70% of the reported adverse events. Despite the fact that the incidence of sarcoidosis is threefold higher in Afro-Americans than in Caucasians, the occurrence of tattoo adverse events in skin type VI patients is remarkable.<sup>9</sup> In addition, more frequent cutaneous involvement amongst Afro-Americans with sarcoidosis is previously reported.<sup>10</sup>

Strengths of this study are the multicenter approach, no previous similar studies and the large sarcoidosis population with a high response rate. Limitations include selection bias due to our academic patient population, patient recall bias and the adverse events and skin type are self-reported.

Concluding, patients (pre)diagnosed with sarcoidosis have a moderate risk of tattoo adverse events, particularly papulo-nodular reactions. Patients with darker skin color seem to be more at risk for developing complications.

**Table 2.** Outcomes of the tattooed with AE.

Parameter	
Patients, N	10
Number of affected tattoos, n (%)	
1	4 (40.0)
2-3	3 (30.0)
4-5	1 (10.0)
6-9	1 (10.0)
>10	1 (10.0)
Affected tattoo location, n (%)	
Trunk	4 (40.0)
Upper extremities	8 (80.0)
Lower extremities	4 (40.0)
Other <sup>1</sup>	
Body surface area <sup>2</sup> , n (%)	
1%	6 (60.0)
2-3 %	2 (20.0)
4-5 %	2 (20.0)
Other <sup>3</sup>	
Time onset of symptoms, n (%)	
<4 weeks	1 (10.0)
>3 months	2 (20.0)
>1 year	7 (70.0)
Symptoms, n (%)	
Papules and nodules	7 (70.0)
Itch	4 (40.0)
Redness (erythema)	2 (20.0)
Swelling	2 (20.0)
Elevation of one tattoo or specific tattoo color	3 (30.0)
Elevation of multiple tattoos or all tattoos	2 (20.0)
Crusts	1 (10.0)
Scaling	2 (20.0)
Scars	1 (10.0)
Other <sup>4</sup>	
Tattoo color, n (%)	
Black	9 (90.0)
Blue	2 (20.0)
Green	2 (20.0)
Red	2 (20.0)
Purple, pink	2 (20.0)
White	1 (10.0)
Other <sup>5</sup>	

Values in parentheses are percentages

<sup>1</sup> Others included: face, neck or genital region. <sup>2</sup> Body surface area of the largest affected tattoo was self-reported as one palm presenting 1% of the body surface. <sup>3</sup> No tattoo sizes >5% of the body surface area were reported. <sup>4</sup> Other symptoms included: pain, wounds or blisters. <sup>5</sup> Other tattoo colors included: brown, yellow, skin tone and orange.

## REFERENCES

1. van der Bent SAS, de Winter RW, Wolkerstorfer A, Rustemeyer T. Red tattoo reactions, a prospective cohort on clinical aspects. *J Eur Acad Dermatol Venereol*. 2019.
2. Huisman S, van der Bent SAS, Wolkerstorfer A, Rustemeyer T. Granulomatous tattoo reactions in permanent makeup of the eyebrows. *J Cosmet Dermatol*. 2019;18(1):212-4.
3. Kluger N. Contraindications for tattooing. *Curr Probl Dermatol*. 2015;48:76-87.
4. Bickett AN, Lower EE, Baughman RP. Sarcoidosis Diagnostic Score: A Systematic Evaluation to Enhance the Diagnosis of Sarcoidosis. *Chest*. 2018;154(5):1052-60.
5. Brady BG, Gold H, Leger EA, Leger MC. Self-reported adverse tattoo reactions: a New York City Central Park study. *Contact Dermatit*. 2015;73(2):91-9.
6. Hogsberg T, Hutton Carlsen K, Serup J. High prevalence of minor symptoms in tattoos among a young population tattooed with carbon black and organic pigments. *J Eur Acad Dermatol Venereol*. 2013;27(7):846-52.
7. Kluger N. Sarcoidosis on tattoos: a review of the literature from 1939 to 2011. *Sarcoidosis Vasc Diffuse Lung Dis*. 2013;30(2):86-102.
8. Sepehri M, Hutton Carlsen K, Serup J. Papulo-Nodular Reactions in Black Tattoos as Markers of Sarcoidosis: Study of 92 Tattoo Reactions from a Hospital Material. *Dermatology*. 2016;232(6):679-86.
9. Rybicki BA, Major M, Popovich J, Jr., Maliarik MJ, Iannuzzi MC. Racial differences in sarcoidosis incidence: a 5-year study in a health maintenance organization. *Am J Epidemiol*. 1997;145(3):234-41.
10. Baughman RP, Teirstein AS, Judson MA, Rossman MD, Yeager H, Jr., Bresnitz EA, et al. Clinical characteristics of patients in a case control study of sarcoidosis. *Am J Respir Crit Care Med*. 2001;164(10 Pt 1):1885-9.



4



# **GRANULOMATOUS TATTOO REACTIONS IN PERMANENT MAKEUP OF THE EYEBROWS**

---

Sanne Huisman, Sebastiaan A.S. van der Bent, Albert  
Wolkerstorfer, Thomas Rustemeyer

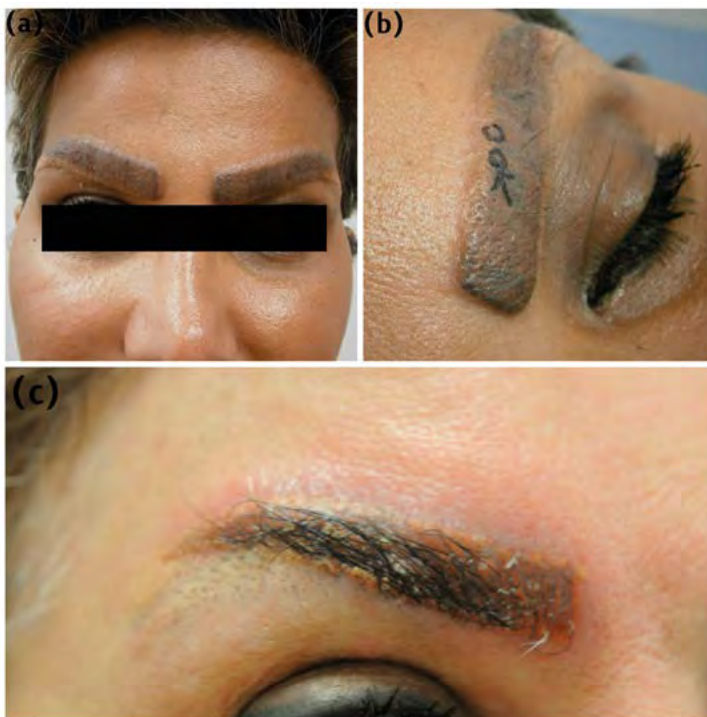*Journal of Cosmetic Dermatology.* 2019;18(1):212-214.



Permanent make-up has become very popular over the last decade(s). Permanent make-up, also named cosmetic tattoos, is used for different indications, such as tattooing eyebrows, eyeliner or the lining of the lips. It offers a solution to individuals with allergies to cosmetic products or physical incapability's such as arthrosis or visual impairment.<sup>1</sup> Although permanent make-up is common and regarded safe, it may still cause adverse skin reactions, including infections, allergic reactions, and auto-immune diseases such as sarcoidosis. Regardless of the size of the affected area, tattoo reactions cause a reduced quality of life.<sup>2</sup>

Here, we report 5 patients referred to the Academic Tattoo Clinic Amsterdam because of a skin reaction in their tattooed eyebrows.

The clinical presentation in these patients include elevated and frequently yellowish plaques, sharply demarcated around the tattooed skin. Figure 1. Remarkably, all patients got their permanent make-up of their eyebrows several times during the last 4 to 15 years. Table 1. Time between last placement of the cosmetic tattoo and onset of complaints varied between 1 to 18 months. Dyes used were in the red, brown and black spectrum. No triggering factors could be identified and there was no history of systemic complaints.



**Figure 1.**

- a) Patient 1: Elevated plaques in the tattooed eyebrow area.
- b) Patient 1: Close up, marked are the biopsy locations.
- c) Patient 4: Yellowish squamous papules and plaques in the tattooed eyebrow area.

**Table 1.** Five cases of granulomatous reactions in permanent make-up.

Patient	Gender (F = female)	Age (years)	Frequency of tattoos	Histopathological pattern	Time lapse (months)	ACE * (U/L)	Chest x-ray	HRCT	Treatment	Follow-up (months)
1	F	41	5	Granulomatous	16	126	Hilar adenopathy	Mediastinal adenopathy	Potent topical steroids	6
2	F	53	2	Granulomatous	18	50	Normal	N/A	Intralesional steroids	10
3	F	33	2	Granulomatous	2	N/A	N/A	N/A	Intralesional steroids	39
4	F	57	15	Granulomatous	1	56	Hilar adenopathy and dubious nodules	Normal	Potent topical steroids	8
5	F	48	4	Granulomatous	17	43	Normal	N/A	Potent topical steroids	3

\* Normal range 20 – 70 U/L. HRCT = High-resolution computed tomography. N/A = not available.

Histopathological evaluation revealed granulomatous inflammation in all patients and additional stains were negative for fungi and acid-resistant mycobacteria. In patient 1 an elevated level of angiotensin-converting enzyme (ACE) of 126 (range 20-70 U/L) was found. In the same patient high-resolution computed tomography (HRCT) revealed mediastinal lymphadenopathy, concluding systemic sarcoidosis. In patient 4 chest x-ray revealed hilar adenopathy and dubious nodules. In the other patients we did not find any signs of systemic sarcoidosis. Patients were treated with topical or intralesional corticosteroids, resulting in almost complete resolution of the skin manifestation.

The differential diagnosis of non-infectious reactions in cosmetic tattoos includes allergic reactions, foreign body reactions and sarcoidosis. Differentiation between these conditions is challenging as allergic reactions to tattoo pigment are difficult to confirm by patch testing, as results are mainly negative.<sup>3</sup> In addition to foreign body reactions and sarcoidosis, allergic reactions can cause granulomatous inflammation as well.<sup>4</sup> If a granulomatous reaction is found, further investigation into sarcoidosis is advised. The percentage of underlying sarcoidosis in individuals presenting with a granulomatous reaction is unknown, however one-third of patients with systemic sarcoidosis have cutaneous lesions.<sup>5</sup> Sepehri et al. confirmed that sarcoidosis is common in non-infectious cosmetic tattoo reactions. They reported in 29% of their patient's sarcoidosis with a papulo-nodular pattern at clinical examination.<sup>6</sup>

The exact pathological mechanism of sarcoidosis remains unclear.<sup>5</sup> Chronic minor exposure of the immune system to the ink may stimulate the development of granulomas and might ultimately lead to granulomatous inflammation in an individual who is genetically sensitive to the development of sarcoidosis.<sup>6</sup> The above would elucidate the long latency period between the placement of the permanent make-up and clinical manifestation in our presented cases. Remarkably, as stated in table 1, our presented cases had set permanent make-up 2 to 15 times before developing adverse reactions. In theory, repeated tattooing and reintroducing foreign material in the skin may trigger autoimmune activation.

Many patients with clinical granulomatous reactions are, eventually, not diagnosed with cutaneous sarcoidosis. Sepehri et al. suggest that these patients might be subclinical cases or cases predisposed to sarcoidosis later in life and therefore must be monitored.<sup>6</sup>

Although the differential diagnosis is challenging, the treatment of choice for granulomatous reaction can be similar. All above presented cases were successfully treated with potent topical or intralesional corticosteroids. Quint et al. also reported a patient in which all lesions had been resolved after the injection of potent corticosteroids.<sup>7</sup> Even spontaneous resolution of a granulomatous reaction to a cosmetic lip tattoo after punch biopsy is described.<sup>8</sup> In associated systemic disease oral prednisone, methotrexate or other immunosuppressant are preferred. Martin et al. reported allopurinol as an effective treatment in a patient, with a granulomatous reaction to a cosmetic tattoo of the lips, not responding to topical steroids.<sup>9</sup> Alternatives are surgical excision or laser therapy, however this trauma can cause exacerbation of the underlying disease.

In conclusion, clinicians should be aware of the fact that granulomatous reactions in tattoos may be a marker of sarcoidosis and therefore, screening and follow-up for other manifestations of sarcoidosis should be performed. The cutaneous lesion may be the only manifestation of the systemic disease. For the treatment we recommend topical or intralesional corticosteroids.

## REFERENCES

1. De Cuyper C., Cosmetic and Medical Applications of Tattooing. In: Cuyper C.D., Pérez-Cotapos S M.L. (eds) *Dermatologic Complications with Body Art*. Springer, Berlin, Heidelberg, 2009
2. Hutton Carlsen K, Serup J. Patients with tattoo reactions have reduced quality of life and suffer from itch. *Skin research and technology*. 2014; 21(1):101-107
3. Serup J, Hutton Carlsen K. Patch test study of 90 patients with tattoo reactions: Negative outcome of allergy patch test to baseline batteries and culprit inks suggests allergen(s) are generated in the skin through haptization. *Contact dermatitis*.2014;71(5): 255-263
4. Van der Bent SA, Wolkerstorfer A, Rustemeyer T. Cutaneous adverse reactions to tattoos. *Nederlands tijdschrift voor de Geneeskunde*. 2016;160:A9808
5. Kluger N. Sarcoidosis on tattoos: a review of the literature from 1939 to 2011. *Sarcoidosis vasculitis and diffuse lung diseases*. 2013;30:86-102
6. Sepehri M, Hutton Carlsen K, Serup J. Papulo-nodular reactions in black tattoos as markers of sarcoidosis: study of 92 tattoo reactions from a hospital material. *Tattoo and body art*. 2016;232(6):679-686
7. Quint KD, Genders RE, Vermeer MH. A delayed granulomatous reaction to a cosmetic tattoo of the eyebrows: A report of total regression after intralesional corticosteroid injections. *Dermatologic surgery*.2012;38(6):951-953
8. Jones B, Oh C, Egan CA. Spontaneous resolution of a delayed granulomatous reaction to cosmetic tattoo. *International journal of dermatology*. 2008;47(1):59-60
9. Martin JM, Revert A, Monteagudo C, Villalón G, Godoy R, Jordá E. Granulomatous reactions to permanent cosmetic tattoos successfully treated with topical steroids and allopurinol. *Journal of cosmetic dermatology*. 2007;6(4):229-231





**DIAGNOSTICS AND  
PATHOMECHANISM**

5

# HISTOPATHOLOGY OF RED TATTOO REACTIONS

---

Sebastiaan A.S. van der Bent, Ellen Oyen, Thomas Rustemeyer,  
Elisabeth H. Jaspars, Rick Hoekzema.

*The American Journal of Dermatopathology. 2020 Jul 22*

# ABSTRACT

## Background

Despite popularity of tattoos, complications might occur. In particular, red tattoo reactions due to allergic reactions are the most frequent chronic tattoo reactions. However, little is known about its histopathology and underlying pathomechanisms.

## Objective

The aim of this article is to analyse the histopathology of red tattoo reactions for diagnostic purposes and to acquire more insight into pathogenesis.

## Methods

A retrospective cross-sectional study was conducted by reviewing the histopathology of 74 skin biopsies of patients with allergic red tattoo reactions. Histopathological findings, such as inflammation patterns, inflammatory cells and pigment depth and colour, were semi-quantified with an in-house validated scoring system by two independent senior investigators.

## Results

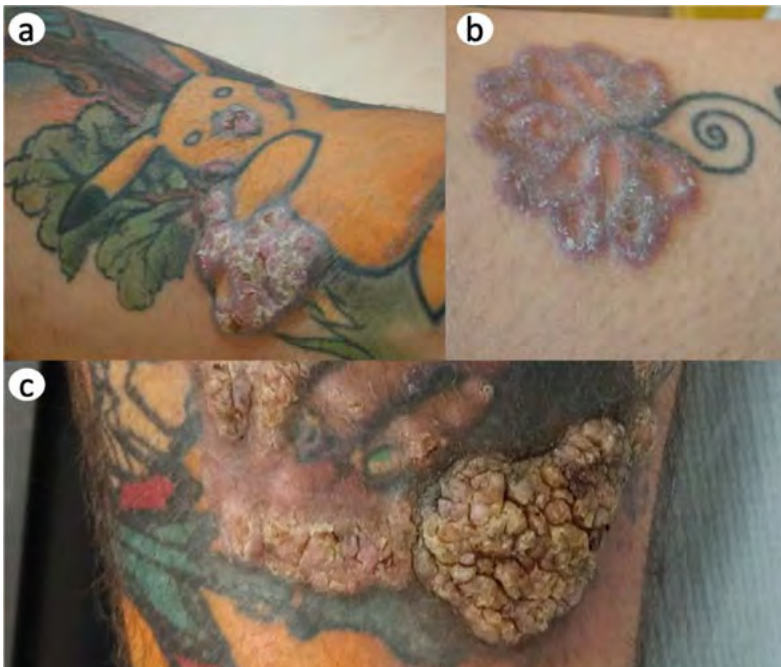Histiocytes and lymphocytes were both present in >93%. Histiocytes were the predominant inflammatory cells in 74.3%, but well-defined granulomas were mostly absent (78,0%). Eosinophils were uncommon (8,1%) The predominantly histiocytic reaction combined with interface dermatitis was the main inflammation pattern (37,9%). Most biopsies showed more than one reaction pattern. Interface involvement was observed in 64,8%, despite the intended depth of standard tattoo procedures, in which pigment is placed deeper, in the upper and mid dermis. Statistical analyses showed a significant association between inflammation severity and pigment depth ( $p = 0.024$ ). In six cases (8,1%) pigments could not be retrieved histologically.

## Conclusion

In this cohort we demonstrated that cutaneous reactions to red tattoo ink are frequently characterized by the combination of dermal predominantly histiocytic infiltrates and epidermal interface dermatitis. Allergic reactions to red tattoo pigments probably represent a combination of a subtype IVa and IVc allergic reaction. Clinicians should be aware of the specific histopathology of these reactions and therefore the importance of taking a diagnostic skin biopsy.

## INTRODUCTION

The prevalence of Europeans with one or more tattoos has increased from 5-10% in 2003 up to 12% in 2016.<sup>1, 2</sup> Tattoos respond to an apparently need to beautify or decorate the skin and are sometimes used for medical purposes as scar camouflage, nipple reconstruction after breast cancer and implants or marking for radiotherapy. However, tattoos can be complicated by infections, allergic reactions and induction of cutaneous autoimmune diseases.<sup>3-5</sup> Although complications of green and blue tattoos are frequently reported, red tattoo reactions are the most frequent chronic tattoo reactions.<sup>6, 7</sup> These tattoo reactions can cause itch, pain and swelling, which may be experienced as highly bothersome and alter the quality of life.<sup>8, 9</sup> Clinically, these reactions present as an elevated plaque in the tattooed skin, sharply confined to the areas coloured red, or nuances of red [Figs 1a-1b]. Less frequently there is hyperkeratosis [Fig. 1c] and rarely ulceration and necrosis.<sup>10, 11</sup> Reactions can develop days, months or even years after tattooing, with an average time of occurrence of 12 months after the tattoo was placed.<sup>12</sup> Histological examination is crucial in the diagnosis of an allergic red tattoo reaction, to exclude other causes of inflammation at the tattoo site, such as infection (including mycobacterial infections) or autoimmune skin diseases such as sarcoidosis, psoriasis,



**Figure 1.** Clinical manifestations.

Tattoo on the left under arm (1a) and the left lower leg (1b), both showing elevation and scaling in the red tattooed area: 'plaque-type allergic reaction'. Tattoo on the left lower leg (1c) with prominent hyperkeratosis in the red tattooed area.

and also atopic dermatitis, or contact dermatitis due to ingredients used in local tattoo aftercare products. Even if the affected skin is limited to one tattoo colour, cutaneous sarcoidosis can occur.<sup>13</sup> A great variety of reaction patterns in tattoo complications have been reported, yet little is published about the association between clinical and histopathological aspects.<sup>5,14,15</sup>

To study the histology of allergic red tattoo reactions is important, as the exact aetiology of these reactions is still unknown. However, little is known about its histopathology: only case series or small studies have been reported so far.<sup>11,16</sup> Histological analysis of the reaction patterns may contribute to the understanding of the underlying pathomechanisms. Clinical studies suggest type IV (delayed type) hypersensitivity as the basic mechanism of tattoo reactions<sup>12</sup>, nevertheless patch testing was shown to be negative in the majority of patients.<sup>17</sup> Hogsberg et al. also suggested an allergic pathomechanism, based on the finding of increased epidermal and dermal inflammatory cells, such as T-lymphocytes and Langerhans cells in a microscopical study of tattoo reactions.<sup>16</sup> Furthermore, Forbat et al. underlined that the majority of the available literature on this subject consists of case series.<sup>18</sup> In our present study we analysed a large cohort of patients with tattoo reactions to red pigments histologically, with focus on the inflammation pattern and the contribution of different inflammatory cell types, in relation to the pigment and its depth. Our data may aid in understanding the immunological events that cause red tattoo reactions.

## MATERIALS AND METHODS

In this retrospective cross-sectional designed study, a search was performed using the database of the Academic Tattoo Clinic Amsterdam of the Department of Dermatology for all patients who visited the clinic between January 2008 and April 2019. Patients clinically diagnosed with an allergic red tattoo reaction, from whom a punch biopsy was taken from a representable affected area within the macroscopically red part of the tattoo, were included. An allergic red tattoo reaction was defined as a chronic tattoo reaction, sharply confined to the red (or nuances of red: pink, purple, brown) tattooed skin only, with symptoms being present for at least 3 months, using the same criteria as previously used by Serup et al. and Van der Bent et al.<sup>3, 7, 12</sup> Patients were excluded based on the following reasons: other diagnoses such as sarcoidosis; other ink colours involved in the reaction than nuances of red; no biopsy taken in the diagnostic process or biopsy taken elsewhere. Whenever sarcoid granulomas were observed histologically, further investigation was performed by chest X-ray and serum angiotensin-converting enzyme for exclusion of systemic sarcoidosis. Clinical information, such as tattoo location, colour and photosensitivity was gathered by medical file review. Photosensitivity was defined as worsening of symptoms at the site of the tattoo reaction, after a variable exposure to outdoor sun. Informed consent was obtained from all participants.

Skin biopsies from tattoo reactions were formalin-fixed, four-micrometer sections were stained with haematoxylin/eosin (HE) and examined by conventional microscopy.

Two independent researchers, a senior dermatologist with expertise in the field of dermatopathology and a pathologist specialized in dermatopathology, reviewed the biopsies individually, blinded for any patient information. A third independent researcher observed the microscopic slides together with both reviewers and filled in the database. In case inter-observer discrepancies existed, re-assessment of the slides took place with both researchers until consensus was achieved.

For data analysis an in-house validated scoring method was used. This method was based on the semi-quantitative method of Hogsberg et al.<sup>16</sup> General histologic features (epidermal acanthosis, -spongiosis, interface activity, dermal fibrosis), types of inflammatory cells (lymphocytes, histiocytes, eosinophilic granulocytes, plasma cells) and pigment colour shades and depth were assessed on a 3-point scale: 0 None; 1 Some/Moderate; 2 Many/Severe. Pigment and inflammation depth were divided into: 0. None; 1. Papillary dermis; 2. Upper reticular dermis; 3. Lower reticular dermis; 4. Subcutis. The predominant subtype(s) group(s) were: Predominantly histiocytic (with or without granulomas); Interface dermatitis; Pseudo-lymphomatous; Spongiotic dermatitis; Perivascular infiltrate and Other/Atypical infiltrate.

Descriptive statistics were generated for all variables. Crosstabs, the Fisher's exact test with p-values ( $p < 0.05$ ) were used to compare categories and check for statistical significance. Statistical analysis was performed using SPSS software (version 25).

## RESULTS

Of the total of 267 patients with tattoo complications, 121 met the criteria for allergic red tattoo reactions. Of these, 74 patients were eligible and gave informed consent, after which their clinical information and skin biopsies were analysed.

The majority of the biopsies were obtained within the last 3 years. Table 1 shows that the majority of participants were women (77,0%); distal lower extremities was the most common tattooed site (50,0%) and plaque elevation was the main clinical manifestation (90,5%). Histological characteristics in Table 2 show that inflammation was scored as severe in 75,7%. Epidermal acanthosis was variable (absent in 44,6% some in 33,8%) and spongiosis was mostly absent (73,0%). Interface activity at the epidermal-dermal junction was present in the majority of biopsies (64,8%), as was dermal fibrosis (91,9%). Both histiocytes and lymphocytes were present in more than 93%. Plasma cells were observed in 37,9% and eosinophils in only 8,1%.

Biopsies showed more than one reaction pattern in 77%. A predominantly histiocytic infiltrate was present in 74,3% (55 cases), sometimes as solitary inflammatory pattern (10,8%, 8 cases) and in most cases combined with other reaction patterns (i.e. together with interface-, spongiotic- or perivascular dermatitis: 63,5%, 47 cases). Interestingly, a predominantly histiocytic dermal reaction combined with the presence of interface dermatitis was the main histopathological combination, observed in 37,9%, with a variable admixture of lymphocytes. [Figs 2a-2b] [Table 4 shows the dominant histological subtypes]

**Table 1.** Patient and tattoo characteristics in patients with allergic red tattoo reactions.

	<b>NUMBER (PERCENTAGE%)</b>
Patients (N)	74
Mean age [SD]	47 (20-74) [12]
Gender, N (%)	
Male	17 (23,0)
Female	56 (77,0)
Tattoos	74
Tattoo localization, N (%)	
Face	4 (5,4)
Trunk	3 (4,1)
Proximal upper extremities	4 (5,4)
Distal upper extremities	24 (32,4)
Proximal lower extremities	2 (2,7)
Distal lower extremities	37 (50,0)
Colour ink	
Red	64 (86,5)
Pink	2 (2,7)
Purple, lavender	4 (5,4)
Combination (red/pink/purple)	4 (5,4)
Clinical manifestation	
Plaque elevation	67 (90,5)
Hyperkeratotic	3 (4,1)
Ulceronecrotic	4 (5,4)
Setting	
Professional tattoo shop	72 (96,0)
Amateur	3 (4,0)
Revision	
No	67 (90,5)
Yes	7 (9,5)
Photosensitivity	
No	45 (60,8)
Yes	21 (28,4)
Unknown	8 (10,8)

When we studied the epidermal-dermal junction at high magnification in cases with distinct interface dermatitis and superficial dermal tattoo pigment, we encountered apoptotic keratinocytes with adjacent lymphocytes, apparently undergoing 'satellite cell necrosis'. Pigment particles appeared to be present in close proximity or on the surface of these apoptotic keratinocytes. [Figs 2c-2d]. We noticed that most biopsies (78%) did not contain well-defined granulomas. If present, granulomas frequently appeared to be poorly defined ('fuzzy' granulomas) [Fig 2e] or were merely present as undefined collections of histiocytes.



**Table 2.** Histopathological features of allergic red tattoo reactions.

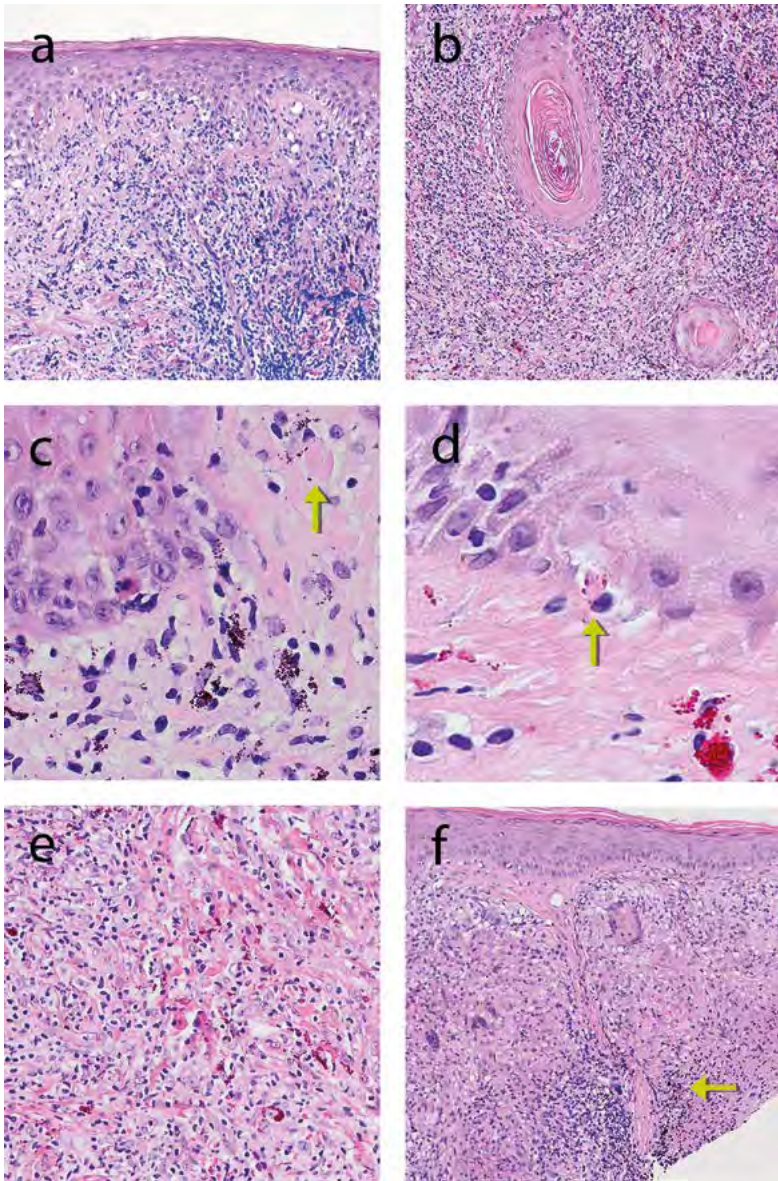
	<b>0 (none)</b>	<b>1 (moderate/some)</b>	<b>2 (severe/many)</b>
<b>INFLAMMATION SEVERITY</b>			
HISTOLOGICAL FEATURES			
Acanthosis	33 (44,6%)	25 (33,8%)	16 (21,6%)
Spongiosis	54 (73,0%)	18 (24,3%)	2 (2,7%)
Interface Activity	26 (35,1%)	24 (32,4%)	24 (32,4%)
Fibrosis	6 (8,1%)	42 (56,8%)	26 (35,1%)
<b>INFLAMMATORY CELLS</b>			
Lymphocytes	4 (5,4%)	27 (36,5%)	43 (58,1%)
Histiocytes	3 (4,1%)	13 (17,6%)	58 (78,4%)
Eosinophils	68 (91,9%)	6 (8,1%)	0 (0,0%)

However, in some cases, well-defined sarcoid granulomas were encountered, reminiscent of cutaneous sarcoidosis. [Fig 2f] [Figs 2e-2f] We did not observe a pseudolymphomatous pattern in any of the biopsies.

In determining the depth of inflammation and tattoo pigment, as shown in table 3, inflammatory infiltrates and pigment particles were mainly confined to the upper and lower reticular dermis. Yet, in some biopsies both pigment particles and inflammatory infiltrates extended into the subcutis. Although all biopsies had been taken from macroscopically red tattoos, microscopic colour shades of tattoo pigment particles varied significantly: cherry red in 24,3% and dark red in 28,4%, purple in 5,4%, brown in 14,9%, up to even black coloured pigment particles in 8,1%. In eight cases (10,8%) overlap between red and dark brown/black pigment particles was visible within the same biopsy. In six cases (8,1%) we were unable to detect any tattoo pigment particles microscopically. Statistical analyses showed a significant correlation between the severity of inflammation and pigment depth with  $p < 0.024$ . ( $\alpha < 0.05$ ). No associations were found between pigment depth and inflammation depth, photosensitivity and interface activity, visible pigment and interface activity, or tattoo location and interface activity.

## DISCUSSION

In this study, the histopathological features of red tattoo reactions generally included the presence of histiocytes as the predominant inflammatory cells (74,3%), indicating a central role for histiocytes in hypersensitivity reactions to red ink. Unexpectedly, interface activity was present in 64,8% [Table 2.] of the biopsies. The combination of a histiocytic pattern and interface dermatitis may point to a specific immunologically mediated red tattoo reaction. It is not exactly clear why this typical reaction, involving the interface between epidermis and dermis, occurs. Interestingly, biopsies with interface dermatitis sometimes showed apoptotic basal keratinocytes with one or more attached lymphocytes.



**Figure 2 a-f.** Histopathological features of red tattoo reactions.

a) example of epidermal interface dermatitis, with dermal predominantly histiocytic infiltrate and 'fuzzy' granulomas (HE x100); b) follicular interface dermatitis and diffuse lymphohistiocytic infiltrate (HE x100); c) detail of epidermal interface dermatitis, with dark tattoo pigment and lymphocytes directly adjacent to a Civatte body (arrow)(HE x400); d) another example of an epidermal apoptotic keratinocyte, with red pigment particles on its surface and an attached lymphocyte (arrow)(HE x400); e) ill-defined 'fuzzy' granuloma, with abundant red tattoo pigment present (HE x200); f) well-developed sarcoid granulomas, with dark-brown tattoo pigment present (arrow)(HE x100).

**Table 3.** Histological inflammation depth and pigment depth of allergic red tattoo reactions.

	<b>0 ABSENT</b>	<b>1 PAPILLARY DERMIS</b>	<b>2 UPPER RETICULAR DERMIS</b>	<b>3 LOWER RETICULAR DERMIS</b>	<b>4 SUBCUTIS</b>
Inflammation depth (%)	3 (4,1%)	0	20 (27,1%)*	46 (62,1%)*	5 (6,8%)
Tattoo pigment depth (%)	6 (8,1%)	2 (2,7%)	29 (39,2%)*	34 (48,6%)*	1 (1,4%)

\*Minimum depth: as far as assessment was possible in superficial biopsies

**Table 4.** Overview of the dominant histological subtypes of allergic red tattoo reactions.

	<b>Total</b>	<b>With granulomas</b>	<b>Without granulomas</b>
<b>DOMINANT SUBTYPE(S)</b>			
Predominantly histiocytic	8 (10,8%)	3 (4,1%)	5 (6,8%)
Perivascular infiltrate	6 (8,1%)		
Other/atypical	3 (4,1%)		
Pseudolymphomatous	0 (0,0%)		
<b>MIXTED SUBTYPES</b>			
Predominantly histiocytic + interface dermatitis	28 (37,8%)	7 (9,5%)	21 (28,4%)
Predominantly histiocytic + perivascular infiltrate	16 (21,6%)	2 (2,7%)	14 (18,9%)
Interface dermatitis + perivascular infiltrate	9 (12,2%)		
Predominantly histiocytic + spongiotic dermatitis	3 (4,1%)	0	3 (4,1%)
Spongiotic dermatitis + perivascular infiltrate	1 (1,4%)		

This phenomenon, highly suggestive of 'satellite cell necrosis', i.e. the process of cytotoxic lymphocytes inducing apoptosis in basal keratinocytes, was observed in several biopsies, in some cases with tattoo pigment particles visible on the surface of the involved keratinocytes [Figs. 2c-2d]. Although reported before <sup>16, 18, 19</sup>, the pathomechanism for interface reactions to red tattoo pigment remains unclear. It could be hypothesized that pigment particles, after binding to certain cell surface molecules on basal keratinocytes, form neo-antigens that are recognized by cytotoxic T cells, Natural Killer (NK) cells or NK-T cells. This could subsequently lead to apoptosis of the (neo)antigen-expressing keratinocytes, causing the release of pro-inflammatory cytokines and the attraction of histiocytes and other inflammatory cells. However, the sequence of events remains to be established: it is also possible that attraction and activation of histiocytes by accumulated red tattoo pigment in the dermis is the initial event and that the observed interface dermatitis is a secondary reaction to the formation of dermal inflammatory infiltrates. In our Tattoo Clinic, tattoo reactions to other colours are also observed, mainly in black tattoos. We studied the histopathology of these black tattoo reactions (data to be published) and, in contrast to red tattoo reactions, these were mainly granulomatous and no interface

dermatitis was rarely observed. The distinct presence of histiocytes could be explained by their role as major component of the innate immune system: they can phagocytose and degrade tattoo ink particles and activate the adaptive immune system by presenting ink antigens to lymphocytes and by cytokine signaling.<sup>20</sup> Indeed, the significant numbers of lymphocytes present in the majority of biopsies with severe inflammation in our study suggest a contribution of antigen-specific cell-mediated immunity, but to confirm this antigen-specific T-cell activation assays are required. The presence of either poorly- or well-defined granulomas (16.3%) may also indicate delayed type hypersensitivity reactions. [Figure 2e;2f] However, in previous studies “dermatitis” or “lichenoid” reactions seemed to be dominant.<sup>21</sup>

We did not observe a pseudolymphomatous reaction pattern in any of the 74 biopsies, which differs from cases reported by others, although they categorised this pattern as uncommon.<sup>22-24</sup>

### **Tattoo pigments: presence and colours**

Histology of uncomplicated tattoos usually shows pigment particles in the upper and mid dermis. Particles can be seen captured inside macrophages and also freely between collagen bundles.<sup>20, 25</sup> In our study, tattoo pigments were found in all layers of the skin, tended to be smaller in the deeper skin layers and were not visible histopathologically in six cases. This was remarkable, since all biopsies were taken from macroscopically visible affected red tattooed skin. Possibly, macrophages had eliminated most pigments by phagocytosis and degradation in these cases. This finding is in line with a recent study, in which 104 red tattoo reactions were studied and no pigments could be identified in 22%.<sup>26</sup>

Pigment depth was associated with inflammation severity, which could be explained by a stronger inflammatory stimulus if pigment depositions are more abundant throughout the skin. Also, histiocytes may have ‘dragged’ pigment particles, bound to cell surface receptors or phagocytosed, deeper into the reticular dermis during the course of the expanding inflammatory infiltrate. Whether deeper situated tattoo pigment itself provokes a stronger inflammatory response in the immediate environment remains to be established. In 3 cases (4,1%) no microscopic inflammation was observed at all, despite the clinical presence of an elevated plaque in the red tattoo. This could indicate that these clinical plaque elevations were merely based on dermal oedema rather than inflammatory infiltrates. As tattoo pigments are permanently located in the dermis, treatment is difficult.<sup>4, 27</sup> The depth of tattoo pigments cannot be established clinically. Histologically, we observed ample variety in pigment depth. Pigment depth may also vary within a single tattoo. These findings suggest that the treatment and removal of these pigments requires an individual approach in which the treatment depth can vary, for example with ablative laser therapy or dermatome shaving.<sup>28</sup> The variation in pigment colours that we observed microscopically may have been due to differences in the composition of the red ink used during tattooing. Mercury, formerly frequently used as a red tattoo pigment, is known

to induce epithelial alterations.<sup>29</sup> However, since mercury is much less frequently used in tattoo pigments nowadays, still most chronic reactions are caused by red pigments.<sup>20, 30, 31</sup> In their search for the identity of the culprit allergen, Serup. et al suggested that azo pigment breakdown products, serving as haptens, may cause the allergic reaction.<sup>26</sup>

## Allergy

Eosinophils were found in only 6 biopsies (8,1%), in contrast to what is expected in cutaneous allergic reactions<sup>20, 32</sup>, yet similar to a previous study on red tattoo reactions (11,11% eosinophils).<sup>16</sup> This raises the question whether these red tattoo reactions are truly caused by an allergy. However, previous reports showed multiple clues for pathomechanism that involve type IV hypersensitivity reactions: i) these reactions are sharply confined to the exclusively red tattooed area; ii) tattoo pigments can cause an inflammatory IL-18 response (pro-inflammatory cytokine, facilitates Th1 lymphocyte responses); iii) red tattoo reactions may show cross reactivity; iv) the delayed onset of symptoms, and v) the reported role of sunlight (photosensitivity) as a trigger.<sup>12</sup> On the other hand, systematic patch testing in red tattoo reactions were merely negative.<sup>17, 33</sup> The amended Gell and Coomb's classification suggests that type IV hypersensitivity reactions can be divided into 4 subtypes: type IVa (Th1 lymphocyte-mediated with activation of macrophages, with or without granuloma formation), type IVb (Th2 lymphocyte-mediated with eosinophilic involvement), type IVc (mediated by cytotoxic lymphocytes causing apoptosis) and type IVd (T lymphocyte-driven neutrophilic inflammation).<sup>34</sup> According to this subclassification of type IV reactions, our results suggest that in allergic reactions to red tattoo pigments, mainly subtypes IVa and IVc are involved. Decomposition products of tattoo pigments can migrate throughout the body and have been found in the regional lymph nodes, where they can be presented to the adaptive immune system, resulting in an antigen-specific immune response.<sup>35</sup> Binding of small fragments from ink particles to certain host proteins (haptens) and photochemical alteration of tattoo pigment may be attributive factors contributing to allergen formation and antigenicity.<sup>17, 33</sup>

## Strengths and limitations

Strengths of this study are the number of patients with a specific reaction to red tattoo ink and the semi-quantified method used to detect different reaction patterns. Limitations include possible interference by other dermatoses, especially in the 37 (50%) biopsies taken from a distal lower extremity: pre-existing stasis dermatitis caused by chronic venous insufficiency may have been responsible for the epidermal spongiosis and/or dermal fibrosis observed in certain cases. Also, treatment effects were not considered in our analysis of the biopsies. Furthermore, the histopathological term 'granuloma' is imprecise and debatable, since there is no strict definition ('relatively discrete collection of histiocytes'), causing subjectivity. In 7 cases (9,5%), sharply demarcated granulomas were

observed. Although signs of cutaneous or systemic sarcoidosis were absent, it cannot be ruled out that sarcoidosis will develop later in these patients.<sup>36</sup>

## CONCLUSION

Histologically, reactions to red tattoo ink are presented as predominantly histiocytic hypersensitivity reactions, frequently in combination with interface dermatitis. Red pigment particles were encountered throughout the different skin layers, including the basal epidermis, where they may have contributed to the interface dermatitis by formation of neo-antigens.

Clinically, red tattoo reactions are thought to be an allergic reaction. As very few eosinophilic and neutrophilic granulocytes were observed, we conclude that specific allergic reactions to red tattoo pigments most likely represent a combination of a subtype IVa and IVc hypersensitivity reaction. In order to reveal the exact pathomechanism, patch testing and photo-patch testing with single ingredients from red tattoo pigments and their breakdown products should be performed, as well as antigen-specific T cell activation assays.

## REFERENCES

1. Kluger N. Epidemiology of tattoos in industrialized countries. *Curr Probl Dermatol.* 2015;48:6-20.
2. Bil W, van der Bent SAS, Spiekstra SW, et al. Comparison of the skin sensitization potential of 3 red and 2 black tattoo inks using interleukin-18 as a biomarker in a reconstructed human skin model. *Contact Dermatitis.* 2018;79(6):336-45.
3. van der Bent SAS, Engel MJC, Nossent EJ, et al. Tattoos and self-reported adverse events in sarcoidosis patients. *J Eur Acad Dermatol Venereol.* 2019.
4. Serup J, Bäuml W. *Diagnosis and Therapy of Tattoo Complications: With Atlas of Illustrative Cases:* S. Karger AG; 2017.
5. Cuyper Cd, Pérez-Cotapos S ML. *Dermatologic complications with body art : tattoos, piercings and permanent make-up.* Cham: Springer; 2018.
6. van der Bent SAS, Berg T, Karst U, Sperling M, Rustemeyer T. Allergic reaction to a green tattoo with nickel as a possible allergen. *Contact Dermatitis.* 2019;81(1):64-6.
7. Serup J, Sepehri M, Hutton Carlsen K. Classification of Tattoo Complications in a Hospital Material of 493 Adverse Events. *Dermatology.* 2016;232(6):668-78.
8. Hutton Carlsen K, Serup J. Patients with tattoo reactions have reduced quality of life and suffer from itch: *Dermatology Life Quality Index and Itch Severity Score* measurements. *Skin Res Technol.* 2015;21(1):101-7.
9. Carlsen KH, Serup J. Chronic tattoo reactions cause reduced quality of life equaling cumbersome skin diseases. *Curr Probl Dermatol.* 2015;48:71-5.
10. van der Bent SAS, Maijer KI, Rustemeyer T. Image Gallery: Hyperkeratotic hypersensitivity reaction to red pigment tattoo. *British Journal of Dermatology.* 2017;177(6):e350-e.
11. van der Bent SA, Wolkerstorfer A, Rustemeyer T. Cutaneous Adverse Reactions to Tattoos. *Ned Tijdschr Geneeskd.* 2016;160:A9808.
12. van der Bent SAS, de Winter RW, Wolkerstorfer A, Rustemeyer T. Red tattoo reactions, a prospective cohort on clinical aspects. *J Eur Acad Dermatol Venereol.* 2019.
13. Ali MM, Atwan AA, Gonzalez ML. Cutaneous sarcoidosis: updates in the pathogenesis. *J Eur Acad Dermatol Venereol.* 2010;24(7):747-55.
14. Serup J, Carlsen KH, Sepehri M. Tattoo complaints and complications: diagnosis and clinical spectrum. *Curr Probl Dermatol.* 2015;48:48-60.
15. Hogsberg T, Thomsen BM, Serup J. Histopathology and immune histochemistry of red tattoo reactions. Interface dermatitis is the lead pathology, with increase in T-lymphocytes and Langerhans cells suggesting an allergic pathomechanism. *Skin Res Technol.* 2015;21(4):449-58.
16. Serup J, Hutton Carlsen K. Patch test study of 90 patients with tattoo reactions: negative outcome of allergy patch test to baseline batteries and culprit inks suggests allergen(s) are generated in the skin through haptization. *Contact Dermatitis.* 2014;71(5):255-63.
17. Forbat E, Al-Niaimi F. Patterns of Reactions to Red Pigment Tattoo and Treatment Methods. *Dermatol Ther (Heidelb).* 2016;6(1):13-23.
18. Vangipuram R BL, Tarbox MB, Stetson CL. Histopathologic Reaction Patterns in Decorative Tattoos. *Pigmentary Disorders.* 2016;3.
19. Patterson JW, Hosler GA. *Weedon's skin pathology.* Edinburgh: Churchill Livingstone Elsevier; 2016.

20. Thum CK, Biswas A. Inflammatory complications related to tattooing: a histopathological approach based on pattern analysis. *The American Journal of dermatopathology*. 2015;37(1):54-66.
21. Marchesi A, Parodi PC, Brioschi M, et al. Tattoo ink-related cutaneous pseudolymphoma: a rare but significant complication. Case report and review of the literature. *Aesthetic Plast Surg*. 2014;38(2):471-8.
22. Kluger N, Durand L, Minier-Thoumin C, et al. Pseudoepitheliomatous epidermal hyperplasia in tattoos: report of three cases. *Am J Clin Dermatol*. 2008;9(5):337-40.
23. Shinohara MM, Nguyen J, Gardner J, Rosenbach M, Elenitsas R. The histopathologic spectrum of decorative tattoo complications. *J Cutan Pathol*. 2012;39(12):1110-8.
24. Goldstein AP. VII. Histologic reactions in tattoos. *The Journal of dermatologic surgery and oncology*. 1979;5(11):896-900.
25. Serup J, Hutton Carlsen K, Dommershausen N, et al. Identification of pigments related to allergic tattoo reactions in 104 human skin biopsies. *Contact Dermatitis*. 2019.
26. de Winter RW, van der Bent SAS, van Esch M, Wolkerstorfer A, Rustemeyer T. Allergic Reaction to Red Cosmetic Lip Tattoo Treated With Hydroxychloroquine. *Dermatitis : contact, atopic, occupational, drug*. 2019;30(1):82-3.
27. Sehgal VN, Srivastava G, Sharma S, Sehgal S, Verma P. Lichenoid tissue reaction/interface dermatitis: recognition, classification, etiology, and clinicopathological overtones. *Indian journal of dermatology, venereology and leprology*. 2011;77(4):418-29; quiz 30.
28. Sowden JM, Byrne JP, Smith AG, et al. Red tattoo reactions: X-ray microanalysis and patch-test studies. *Br J Dermatol*. 1991;124(6):576-80.
29. Elder DE. *Lever's Histopathology of the Skin*. [Philadelphia]: Wolters Kluwer Health; 2015.
30. M H. Allergic contact dermatitis: PathologyOutlines.com website; [Available from: <https://www.pathologyoutlines.com/topic/skinnontumorallergiccontact.html>].
31. Antony FC, Harland CC. Red ink tattoo reactions: successful treatment with the Q-switched 532 nm Nd:YAG laser. *Br J Dermatol*. 2003;149(1):94-8.
32. Uzzaman A, Cho SH. Chapter 28: Classification of hypersensitivity reactions. *Allergy and asthma proceedings*. 2012;33 Suppl 1:96-9.
33. Wenzel SM, Rittmann I, Landthaler M, Baumler W. Adverse reactions after tattooing: review of the literature and comparison to results of a survey. *Dermatology*. 2013;226(2):138-47.
34. Huisman S, van der Bent SAS, Wolkerstorfer A, Rustemeyer T. Granulomatous tattoo reactions in permanent makeup of the eyebrows. *Journal of cosmetic dermatology*. 2019;18(1):212-4.





6

**COMPARISON OF THE SKIN  
SENSITIZATION POTENTIAL OF  
FIVE RED AND BLACK TATTOO  
INKS USING IL-18 BIOMARKER  
IN A RECONSTRUCTED HUMAN  
SKIN MODEL**

---

Wieneke Bil\*, Sebastiaan A.S. van der Bent\*, Sander W. Spiekstra,  
Kamram Nazmi, Thomas Rustemeyer, Sue Gibbs.

\* These authors contributed equally.

*Contact Dermatitis. 2018 Dec;79(6):336-345.*

## SUMMARY

### Background

During the last decade, the number of people with one or more tattoos has increased noticeably within the European population. Despite this, safety assessment is limited for tattoo inks.

### Objectives

To test the skin sensitization potential of five tattoo inks *in vitro* using reconstructed human skin (RhS) and the contact sensitizer biomarker IL-18.

## 6

### Methods

Two red and three black tattoo inks, one additive (Hamamelis Virginia extract), and one irritant control (lactic acid) were tested. The culture medium of RhS (reconstructed epidermis on a fibroblast populated collagen hydrogel) was supplemented with test substances in a dose-dependent manner for 24 hours, after which cytotoxicity (histology, MTT assay) and sensitizing potential (IL-18 secretion, ELISA) was assessed.

### Results

All but one ink demonstrated cytotoxicity. Notably, one red ink and one black ink were able to cause an inflammatory response, indicated by substantial release of IL-18 suggesting that these inks may be contact sensitizers.

### Conclusions

The *in vitro* RhS model showed that four tattoo inks were cytotoxic and two were able to cause an inflammatory IL-18 response, indicating that an individual may be prone to develop allergic contact dermatitis when exposed to these tattoo inks.

### Key words

allergic contact dermatitis, human reconstructed skin, IL-18, *in vitro*, safety assessment, skin sensitization, tattoo ink.

### Abbreviations

AOP, adverse outcome pathway; C.I., color index; EC50, effective chemical concentration to reduce cell viability by 50%; HPLC, high-performance liquid chromatography; IL-18, interleukin 18; LC, Langerhans cell; NA, not available; PAAs, primary aromatic amines; PAHs, polycyclic aromatic hydrocarbons; RhE, reconstructed human epidermis; RhS, reconstructed human skin; SEM, standard error of the mean; SI, stimulation index.

## INTRODUCTION

During the last decade, the percentage of Europeans with one tattoo or more increased noticeably from 5-10% in 2003 to 12% in 2016.<sup>1</sup> Simultaneously, the number of patients with tattoo-related complications visiting the dermatologist indicates a real health risk. Allergic reactions are reported to be mostly associated with red-pigmented tattoos, in which an itching, plaque-like elevation may be observed, confined to one uniformly colored site of the tattoo.<sup>6,7</sup> A strong allergy occurring in a tattoo can ultimately manifest itself in hyperkeratosis, or even ulceration and necrosis of the skin.<sup>7-9</sup> The onset of complications may differ substantially, from straight after placement of the tattoo up to years or decades afterwards.<sup>1</sup> Occasionally, the allergic reaction can manifest simultaneously in older-, similarly colored tattoos.<sup>7</sup> The disease burden of a chronic allergic reaction in a tattoo is high and significantly reduces the quality of life.<sup>10</sup> Therefore generation of *in vitro* toxicity data is of utmost importance if we are to gain a better understanding of safety regarding tattoo inks. Recent publications concerning the health hazard of tattoo inks provided insight into cytotoxicity, genotoxicity and reactive oxygen species production following tattoo ink exposure in the skin.<sup>2-5</sup> However, *in vitro* data on sensitization potential of tattoo inks is scarce.

The pigments in tattoo ink are not strictly intended for intradermal use but are prepared for other (industrial) uses as well, such as application in textiles, lacquer, inks, or plastics. Therefore these pigments are not specifically assessed for the injection and permanent application into the human body.<sup>11,12</sup> Currently, azo dyes are the class of chemicals most commonly used as colorant in tattoo inks. They replace the traditional pigments such as cinnabar (red), chromium (green), cobalt (blue), cadmium (yellow), or manganese (purple).<sup>1</sup> Azo dyes are present in many consumer products, such as textiles and leather clothing, and are associated with allergy.<sup>13-15</sup> Metabolism or chemical degradation of the azo bond may result in Primary Aromatic Amines (PAAs), some of which have been proven to possess mutagenic and carcinogenic-, or sensitizing properties.<sup>11</sup>

Black inks usually contain pigments from natural origin, such as Carbon Black (Pigment Black 6/7). This pigment consists mainly out of elemental carbon (>97%). The Scientific Committee for Consumer Safety (SCCS, formerly SCCP) concluded in their scientific opinion that this Carbon Black pigment, when considered in its nano-structured form, can be regarded as safe at concentrations up to 10% in consumer products.<sup>16</sup> However, polycyclic aromatic hydrocarbons (PAHs) may be present as contaminants in this pigment, of which several have been classified as carcinogenic by the International Agency for Research on Cancer (IARC).<sup>3,17</sup>

The Adverse Outcome Pathway (AOP) for the process of skin sensitization defines one Molecular Initiating Event and a number of Key Events.<sup>18</sup> Key Event 1 (initial event) – covalent binding of a xenobiotic chemical to a skin protein, forming a hapten, and penetration of the hapten through the skin's stratum corneum into the viable layers of the underlying epidermis; Key Event 2 - activation of keratinocytes resulting in cytokine

secretion e.g. IL1a, IL-18, TNF- $\alpha$ ; Key Event 3 - Langerhans cell (LC) activation (migration and maturation) directly or by a hapten-carrier protein complex; and Key Event 4 - presentation of the antigen by matured LC to antigen-responsive T-Lymphocytes in the draining lymph nodes resulting in primed effector and memory T-Lymphocytes.<sup>18, 19</sup>

It has been observed that sensitizer potency is related to the irritant properties of the chemical, and that this irritancy results in an innate immune inflammatory response (i.e. xenoinflammation).<sup>20</sup> New insights into the mechanism of xenoinflammation have identified IL-18 (amongst other cytokines) as playing a pivotal role in Key Event 2 of skin sensitization and allergic contact dermatitis, but surprisingly not in respiratory sensitization or irritant contact dermatitis.<sup>20-22</sup> IL-18 is therefore considered to be the key between xenoinflammation, which may be caused by irritants as well as contact allergens, and migration of the dendritic cells.<sup>20</sup> Hence, this cytokine can be considered as a specific biomarker which is upregulated by chemicals which have the potential to be skin sensitizers.

We have previously developed an *in vitro* assay to distinguish contact sensitizers from irritants based on the release of IL-18 from reconstructed human epidermis (RhE).<sup>23, 24</sup> The assay is currently undergoing validation in Europe, Asia, and America and can use commercially available RhE as well as in house academic RhE. An IL-18 stimulation index (SI) equal to or above a threshold value (to be defined for each type of RhE) is strongly indicative of a skin sensitizer. For our in house RhE, an SI  $\geq 5$  could predict skin sensitizers from non-sensitizers with 95% accuracy.<sup>23</sup> Of note, in the RhE model, chemicals were applied topically to the stratum corneum, thus mimicking topical exposure in humans.

The aim of this research was to determine whether an organotypic 3D Reconstructed human Skin (RhS) model could serve as a screening tool for determining the skin sensitizing potential of tattoo inks. RhS consists of a reconstructed differentiated epidermis grown on a fibroblast populated collagen hydrogel at the air-liquid interface.<sup>25</sup> Since tattoo inks are permanently injected into the dermis, a topical application was considered not to be the best application method. Therefore, instead of a topical exposure, tattoo dyes were supplemented into the culture medium to achieve an intradermal exposure. IL-18 release and cytotoxicity were determined *in vitro* for two red- and three black tattoo inks in order to obtain information on sensitization potential. These red inks in particular were chosen since they were associated with allergic reactions in patients visiting the tattoo outpatient clinic of VU University Medical Center.

## MATERIALS AND METHODS

### Reconstructed human skin culture

Human foreskin was obtained from healthy human donors and was used in anonymous fashion in compliance with the VU University Medical Center's ethical guidelines and the "Code for Proper Use of Human Tissues" as formulated by the Dutch Federation of Medical Scientific Organizations (see [www.fmwv.nl](http://www.fmwv.nl)).

RhS were constructed as described previously.<sup>26</sup> In short, dermal fibroblasts and epidermal keratinocytes were isolated from foreskins and cultured until 90% confluent. Passage 1 cells were used to construct RhS in 2.5 cm diameter transwells (pore size of 0.4  $\mu\text{m}$ ; Corning, NY, USA). Keratinocytes ( $5 \times 10^4$  cells) were seeded on top of the fibroblast populated collagen hydrogels ( $1 \times 10^5$  fibroblasts per gel).

RhS were cultured initially submerged for 3 days and then a further 14 days at the air liquid interface, with the culture medium only in contact with the underside of RhS via the porous transwell membrane, in order to promote epidermal differentiation in Dulbecco's Modified Eagle Medium (DMEM; Lonza, Basel, Switzerland) and Ham-F12 (Gibco, Grand Island, USA) (3:1) containing 0.2% Ultrosereg (BioSeptra S.A. Cergy-Saint-Christophe, France), 1% penicillin-streptomycin, 1  $\mu\text{M}$  hydrocortisone, 1  $\mu\text{M}$  isoproterenol, 0.1  $\mu\text{M}$  insulin, 2 ng/mL Keratinocyte Growth Factor, 0.5 ng/mL Epidermal Growth Factor,  $1.0 \times 10^{-5}$  M L-carnitine,  $1.0 \times 10^{-2}$  M L-serine, and supplemented with a lipid-mixture (25  $\mu\text{M}$  palmitic acid, 15  $\mu\text{M}$  linoleic acid, and 7  $\mu\text{M}$  arachidonic acid), 50  $\mu\text{g}/\text{mL}$  ascorbic acid, and Vitamin E. Medium was changed twice a week. For the exposure, cultures were incubated overnight in the above mentioned medium, in the absence of hydrocortisone.<sup>25</sup> All substances were derived from Sigma Chemical Co. (St. Lewis, MO, USA) unless stated otherwise.

## Chemical exposure

Two red inks and three black inks which are commercially available from Intenze (Intenze Products, Kalsdorf, Austria), Eternal Ink (Eternal Ink, Brighton, UK) and Carbon Black (H-A-N GmbH, Esslingen, Germany) were selected for testing in the RhS model (Table 1). Hamamelis Virginiana extract was also tested, as it is an anti-inflammatory agent added to 2 of the 5 tattoo inks investigated in this study (Table 1). Isopropanol (1% w/w) was used as vehicle for diluting Eternal Ink Light Red and Carbon Black No. 13 as this is a component of the undiluted ink and glycerol (1 % w/w) was used as vehicle for the other inks as glycerin (not isopropanol) was a component of these inks (see Table 1). Furthermore, a non-sensitizing irritant control was tested in order to obtain a sensitizer threshold level for the SI IL-18 parameter: lactic acid (Table 2).

The culture medium of RhS was supplemented with test substances at final concentrations of 10%, 1%, 0.1%, and 0.01%, or as stated otherwise, for 24 hours. Lactic acid and Hamamelis Virginiana water were diluted in culture medium to the required concentrations. Hereafter RhS were harvested. RhS biopsies were taken and processed immediately i) using the MTT assay to determine mitochondrial activity and ii) for histology. In addition, culture supernatant obtained from underneath the air-exposed RhS was harvested and stored at  $-20\text{ }^{\circ}\text{C}$  until further ELISA analysis.

## MTT assay

Mitochondrial activity, an indicator for cell viability, was determined using the MTT assay<sup>27</sup>. For each RhS, a punch biopsy (diameter 3 mm) was taken, rinsed in PBS to remove

**Table 1.** Commercially available tattoo inks and the relevant hazard identification of these substances according to CLP<sup>a</sup>.

<b>Tattoo Ink</b>	<b>Batch number</b>	<b>Chemical listed in ink</b>	<b>C.I. n.r.</b>	<b>Pigment</b>	<b>CAS n.r.</b>	<b>Hazard identification</b>
Intenze Gold Label Bright Red	RD69Y79O75IMX40	NA	C.I. 12477	Red 210	61932-63-6	Results in o-anisidine (CAS nr. 90-04-0) after amide hydrolysis, Acute Tox. 3, Carc. 1B, Muta. 2
		2-[(4-methoxy-2-nitrophenyl)azo]-N-(2-methoxyphenyl)-3-oxobutyramide	C.I. 11740	Yellow 65	6528-34-3	NA
		4,4'-[(3,3'-Dichloro[1,1'-biphenyl]-4,4'-diyl)bis(azo)]bis[2,4-dihydro-5-methyl-2-phenyl-3H-pyrazol-3-one]	C.I. 21110	Orange 13	3520-72-7	Results in 3,3'-chlorobenzidine (CAS nr. 91-94-1) after cleavage of azo bond, Carc. 1B, Skin Sens. 1
		Hamamelis Virginiana Extract	NA	NA	84696-19-5	NA
		Diazolidinyl Urea	NA	NA	78491-02-8	Formaldehyde (CAS nr. 50-00-0) releasing preservative, Carc. 1B, Muta, 2, Skin Sens. 1, Acute Tox. 3, and Skin Corr. 1B
Eternal Ink Light Red	NA	4-[[4-(Aminocarbonyl)phenyl]azo]-N-(2-ethoxyphenyl)-3-hydroxynaphthalene-2-carboxamide	C.I. 12475	Red 170	2786-76-7	Skin Sens. 1 <sup>c</sup>
		Isopropanol	NA	NA	67-63-0	Eye irrit. 2
		Hamamelis Virginiana Water	NA	NA	84696-19-5	NA
Intenze Sculpting Black	BK76DIS	Carbon black	C.I. 77266	Black 6/7	1333-86-4	Carc. 2 <sup>c</sup>
		Distilled water	NA	NA	7732-18-5	NA
		Isopropanol	NA	NA	67-63-0	Eye irrit. 2
		Glycerin	NA	NA	56-81-5	NA
Intenze True Black	BLK1301MX40-GE	Carbon black	C.I. 77266	Black 6/7	1333-86-4	Carc. 2 <sup>c</sup>
		Distilled water	NA	NA	7732-18-5	NA
		Isopropanol	NA	NA	67-63-0	Eye irrit. 2
		Glycerin	NA	NA	56-81-5	NA



Table 1. (continued)

Tattoo Ink <sup>b</sup>	Batch number	Chemical listed in ink	C.I. nr.	Pigment	CAS nr.	Hazard identification	
Carbon Black No. 13 Blackout	A0000585	Carbon black	C.I. 77266	Black 6/7	1333-86-4	Carc. 2 <sup>c</sup>	
		Ammonium acrylates copolymer	NA	NA	NA	NA	
		Propylene glycol	NA	NA	57-55-6	NA	NA
		Poloxamer 331	NA	NA	NA	NA	NA
		Poloxamer 188	NA	NA	NA	NA	NA
		Isopropanol	NA	NA	67-63-0	NA	Eye irrit. 2

The two red inks and three black inks were commercially available from Intenze (Intenze Products, Kalsdorf, Austria), Eternal Ink (Eternal Ink, Brighton, UK) and Carbon Black (H-A-N GmbH, Esslingen, Germany)

<sup>a</sup>Classification, Labelling and Packaging of Substances and Mixtures Regulation (CLP, Regulation (EC) No. 1272/2008)

<sup>b</sup>This Table illustrates the ingredients mentioned on the label of the tattoo ink bottle.

<sup>c</sup>Self-classified by registrant under REACH (Registration, Evaluation, Authorisation or Restriction of Chemicals Regulation (EC) No. 1907/2006).; NA = Not available.

**Table 2.** The hazard identification of the vehicles, additive, and irritant according to CLP<sup>a</sup>.

Chemical name	CAS nr.	Hazard identification
Isopropanol	67-63-0	Eye irrit. 2
Glycerol	56-81-5	NA
Hamamelis Virginiana extract	84696-19-5	NA
Lactic acid	79-33-4	Eye Dam. 1 <sup>b</sup> , Skin Irrit. 2 <sup>b</sup> , Eye Irrit. 2 <sup>b</sup> , Skin Corr. 1B <sup>b</sup>

NA = Not available

<sup>a</sup> Classification, Labelling and Packaging of Substances and Mixtures Regulation (CLP, Regulation (EC) No. 1272/2008)

<sup>b</sup> Self-classified by the registrant under REACH (Registration, Evaluation, Authorisation, and Restriction of Chemicals Regulation (EC) No. 1907/2006).

6

any excess ink from the underside of the culture, and transferred to a 96 wells culture plate containing 200  $\mu$ L thiazolyl blue tetrazolium bromide (MTT) diluted in PBS (2 mg/mL) and further processed as described in Gibbs, Corsini, Spiekstra, Galbiati, Fuchs, Degeorge, Troese, Hayden, Deng and Roggen.<sup>23</sup> To determine whether the tattoo inks were able to interfere with the MTT assay, 10 % of each tattoo ink was tested in the absence of RhS. No colour change measured at 570 nm was observed and therefore it was concluded that the inks did not interfere with the MTT assay at concentrations used for RhS exposure. This is the method recommended in the OECD TG 431 and 439 for *in vitro* skin corrosion test (epiCS 2012).

### Hematoxylin/eosin paraffin staining assay

For light microscopic examination, RhS samples were fixed in 4% paraformaldehyde and embedded in paraffin. Subsequently, thin sections (5  $\mu$ m) were cut and stained using hematoxylin and eosin.

### IL-18 ELISA

After exposure, the amount of IL-18 in the culture supernatant was measured using a commercially available specific sandwich ELISA kit according to manufacturer's instructions (MBL, Nagoya, Japan). Cytokine levels determined in the exposed RhS were transformed into a stimulation index (SI) relative to the vehicle (fold increase), according to the procedure described in Gibbs, Corsini, Spiekstra, Galbiati, Fuchs, Degeorge, Troese, Hayden, Deng and Roggen<sup>23</sup>.

### High-performance liquid chromatography (HPLC)

RP-HPLC (Jasco, Japan) was performed using aSymmetry C18 column, 100 $\text{\AA}$ , 5  $\mu$ m, 3.9 x 150 mm (Waters, Milford, MA, USA), containing dimethyloctadecylsilyl bonded amorphous silica. to detect the presence of PAHs in the black inks. A PAH identification mixture and a benzo[a]pyrene standard were obtained from Sigma Chemical Co. (St. Lewis, MO, USA). To prepare the benzo[a]pyrene standard, the chemical was dissolved

in methanol to a concentration of 10 µg/mL. Each black ink (1 mL) was extracted overnight using 5 mL dinitrochloromethane (Biosolve, The Netherlands), and dried in a vacuum concentrator RVC-2-25 Co plus (CHRIST, Germany). Subsequently, ink samples were dissolved in methanol. Samples were filtered over a PTFE 0.2µm membrane filter and elution was performed with a linear gradient from 40-85% acetonitrile (Actu-ALL chemicals, The Netherlands) containing 0.1% TFA (Biosolve, The Netherlands) for 45 minutes at a flowrate of 1 mL/min. The PAH identification mixture was used to compare with peaks obtained from the tattoo inks. For identification of benzo[a]pyrene, 20 µl of 10 µg/ml benzo[a]pyrene standard was analyzed separately and then 90 µl of 100 µg/ml benzo[a]pyrene standard was spiked with 10 µl of the extracted Intenze Sculpting Black tattoo ink fraction.

### Data analysis

Data represents at least three independent experiments with an intra-experiment duplicate. Each experiment used RhS constructed from a different skin donor. Results of cell viability and IL-18 secretion were analyzed using one-way ANOVA followed by Dunn's multiple comparison test (GraphPad Prism, version 7.0). Difference was considered significant when  $p < 0.05$ , compared to the vehicle-exposed control for IL-18 SI and the negative control for cell viability.

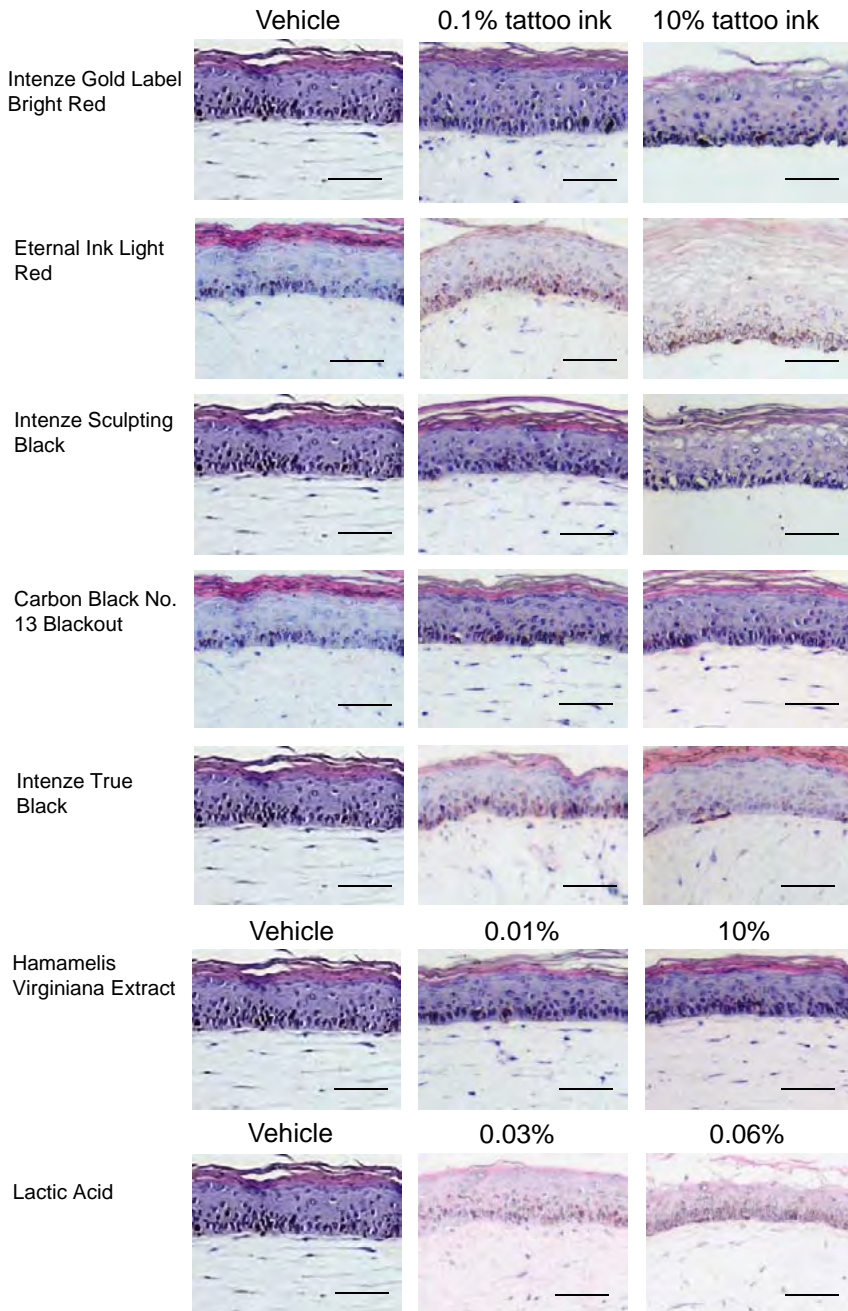
## RESULTS

### Tattoo inks exhibit irritant properties when exposed to reconstructed human skin

Five tattoo inks were selected for testing in the RhS model in order to determine their skin irritant- and sensitizing potency. Furthermore, two vehicles (glycerol and isopropanol), one tattoo ink additive (Hamamelis Virginia extract), and one irritant (lactic acid) were tested (Table 1; Table 2). The substances were added to the culture medium of RhS and tested in a dose-dependent manner for 24 hours.

Clear deleterious effects were observed in the tissue architecture of the RhS exposed to the tattoo inks Eternal Ink Light Red, Intenze Gold Label Bright Red, and Intenze Sculpting Black at a concentration of 10% (Fig. 1). Cytotoxicity was indicated by an increase in the number of vacuoles, nuclei shrinkage, and detachment of the epidermis. Carbon Black No. 13 Blackout and Intenze True Black had no visible effects on tissue histology. As expected, the irritant control (lactic acid) was clearly cytotoxic at a concentration of 0.06%, and Hamamelis Virginia extract had no effect on tissue architecture.

The MTT assay was performed in order to determine the test substance concentration which reduces RhS viability by 50% (EC50 value). This value relates to the cytotoxic/irritant potential of the substances (a low EC50 value corresponds to strong irritant potency). With the exception of Intenze True Black and Hamamelis Virginia extract, RhS viability was reduced in a dose-dependent manner (Fig. 2; Table 3). Ranking the inks, additive,



**Figure 1.** Histology of RhS exposed to tattoo inks, Hamamelis Virginiana extract, vehicles glycerol and isopropanol, and lactic acid. Test substances were added to the culture medium for 24 hours. For Eternal Ink Light Red and Carbon Black No. 13 Blackout isopropanol (1% w/w) was used as vehicle, and for all other substances the vehicle was glycerol (1% w/w). Representative hematoxylin and eosin staining of 5- $\mu$ m paraffin-embedded RhS tissue sections is shown. 200 x magnification; scale bar represents 50  $\mu$ m.

and irritant in order of most-toxic to non-toxic based on their EC50 value provides: Eternal Ink Light Red (0.04% w/w) > lactic acid (0.05% w/w) > Intenze Sculpting Black (0.09% w/w) > Intenze Gold Label Bright Red (6.3% w/w) > Carbon Black No.13 Blackout (12% w/w) > Intenze True Black (not reached) > Hamamelis Virginiana extract (100% w/w). Clearly, four of the five inks have cytotoxic/irritant *in vitro* properties with Eternal Ink Light Red and Intenze Sculpting Black, being highly cytotoxic/ in the same order of magnitude as lactic acid.

### **Exposure to Eternal Ink Light Red and Intenze Sculpting Black increases release of sensitization biomarker IL-18 from reconstructed human skin**

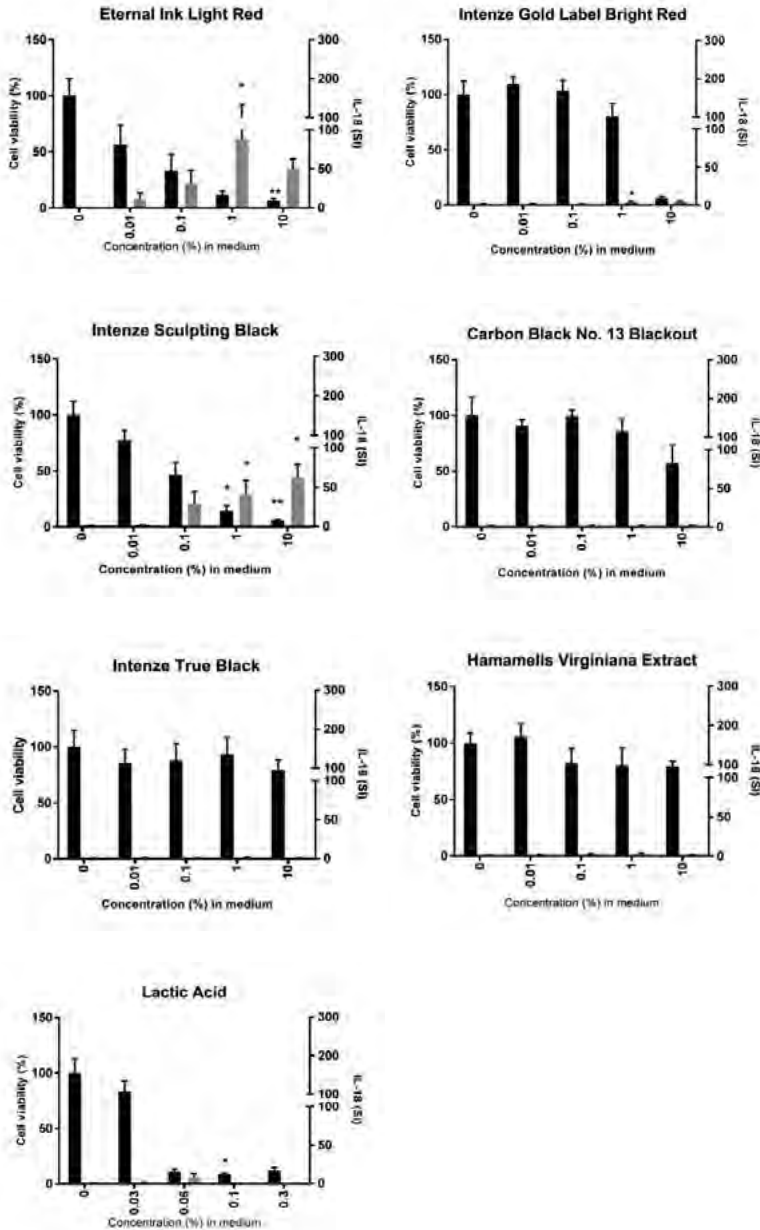
Having determined the cytotoxic/irritant potential of the five tattoo inks, we next determined whether the dyes could also result in an increase in the sensitization biomarker IL-18 release from RhS. Two dyes in particular, Eternal Ink Light Red (SI:  $88 \pm 45$ ) and Intenze Sculpting Black (SI:  $62 \pm 15$ ) resulted in a substantial release of IL-18 into the culture supernatant of RhS compared to the other three tattoo dyes, indicating that these dyes may have sensitizing potential (Fig. 2; Table 3). The tattoo dye vehicles (glycerol and isopropanol), Hamamelis Virginiana extract, and lactic acid did not increase IL-18 release as expected.

### **The extremely strong sensitizer benzo[a]pyrene is present in Intenze Sculpting Black**

To explain the differences in IL-18 release and cytotoxicity observed between Intenze Sculpting Black and the other two black inks, HPLC was performed to screen for PAHs (Fig. 3.). Special attention was paid to benzo[a]pyrene since this compound is classified as extremely strong sensitizer in the Local Lymph Node Assay.<sup>28</sup> HPLC analysis indicated that Intenze Sculpting Black contains three major compounds that co-eluted with peaks 1, 3 and 11 from the PAH identification mixture. Intenze True Black contains mainly compounds that co-eluted with peaks 4 and 13 while Carbon Black mainly contains compound 4. Interestingly, Compound 11 being benzo(a)pyrene (as determined by spiking the ink with a benzo[a]pyrene standard) was only present in Intenze Sculpting Black.

## **DISCUSSION**

From our clinical experience as well as scientific literature it can be concluded that tattoo inks may cause deleterious health effects in the skin.<sup>1,7</sup> This finding therefore calls for much stricter safety assessment of tattoo inks in the future. In this study, using the 3D organotypic RhS model and the sensitization biomarker IL-18, we clearly demonstrate that four of five tested inks were cytotoxic (and therefore have irritant properties) and that two inks may have sensitizing potential. Currently, *in vitro* analysis regarding the toxicity of tattoo inks has focused on cytotoxicity, genotoxicity and reactive oxygen species production.<sup>2-5</sup> Our

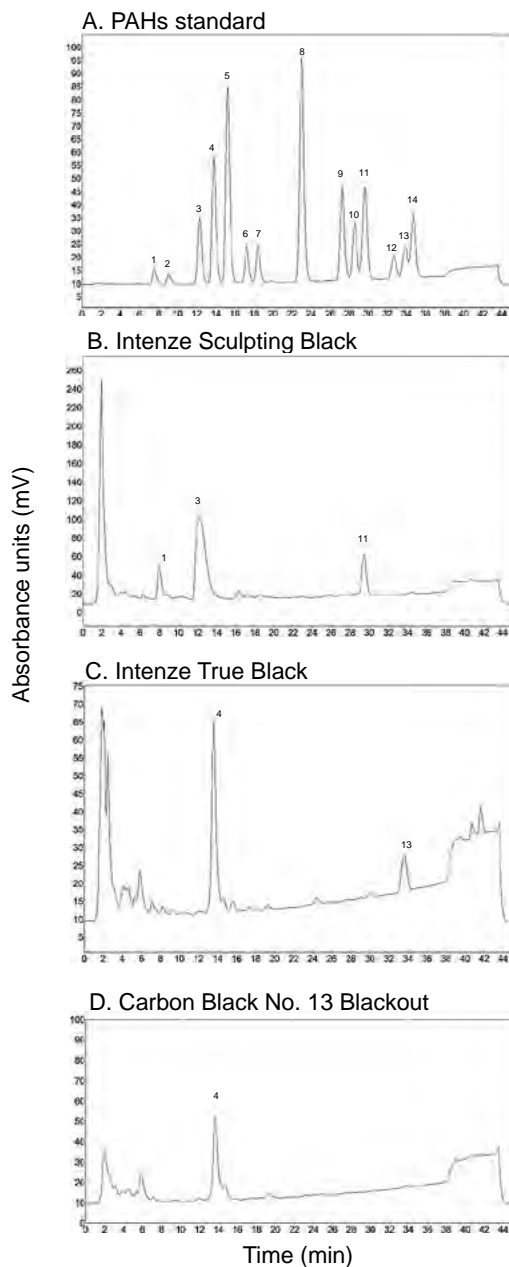


**Figure 2.** Tattoo inks are cytotoxic and result in IL-18 release from RhS. RhS were exposed to test substances for 24 hours, culture supernatants were then analyzed using a specific IL-18 ELISA, and RhS cell viability was determined using the MTT assay. IL-18 stimulation index (grey bars) and cell viability (black bars) are shown as mean  $\pm$  SEM with each experiment (n) representing a different batch of RhS constructed from a different donor skin for Eternal Ink Light Red (n = 5), Intenze Gold Label Bright Red (n = 5), Intenze Sculpting Black (n = 5), Carbon Black No. 13 Blackout (n = 4), Intenze True Black (n = 4), Hamamelis Virginiana extract (n = 4), and lactic acid (n = 3). Statistical significance was determined using one-way ANOVA followed by Dunn's multiple comparison test. \* p < 0.05; \*\* p < 0.01 compared to the vehicle-exposed RhS.

**Table 3.** Summary results of cell viability and IL-18 secretion for inks, additives, and irritants.

Tattoo Ink	Conc.	Cell viability		EC50	IL-18 SI		N
		± SEM (%)	EC50		± SEM	N	
Eternal Ink	0.01 %	57	16	0.04%	<b>11</b>	<b>7.6</b>	5
Light Red	0.1%	33	13		<b>31</b>	<b>17</b>	
	1%	12	3.0		<b>88</b>	<b>45</b>	
	10%	6.4	2.2		<b>50</b>	<b>13</b>	
Intenze Gold Label Bright Red	0.01 %	110	6.1	6.3%	1.2	0.48	5
	0.1%	103	8.5		0.9	0.15	
	1%	80	11		4.1	1.3	
	10%	6.4	1.6		4.1	1.4	
Intenze Sculpting Black	0.01 %	78	7.7	0.09%	1.9	0.37	5
	0.1%	47	10		<b>29</b>	<b>14</b>	
	1%	15	4.0		<b>41</b>	<b>16</b>	
	10%	5.8	1.0		<b>62</b>	<b>15</b>	
Carbon Black No.13 Blackout	0.01 %	90	5.0	12%	1.4	0.23	4
	0.1%	99	4.6		1.5	0.23	
	1%	86	9.4		1.5	0.28	
	10%	57	14		1.3	0.56	
Intenze True Black	0.01 %	85	11	NR	1.1	0.19	4
	0.1%	88	13		0.8	0.18	
	1%	94	13		1.4	0.50	
	10%	79	7.6		0.7	0.28	
Additive:							
Hamamelis	0.01 %	105	10	100%	1.6	0.35	4
Virginiana extract	0.1%	82	11		2.5	0.39	
	1%	80	13		2.8	1.12	
	10%	79	3.8		1.2	0.25	
Control Irritant:							
Lactic Acid	0.03%	84	7.4	0.05%	1.4	0.24	3
	0.06%	11	1.9		8.3	3.9	
	0.1%	9	1.0		0.1	0.02	
	0.3%	12	2.7		0.0	0.01	

N = Number of experiments; NR = Not reached; SEM = Standard Error of the Mean; SI = Stimulation Index. Eternal Ink Light Red and Carbon Black No. 13 Blackout are expressed relative to the vehicle isopropanol (1% w/w), all other exposure conditions are expressed relative to the vehicle glycerol (1% w/w).. IL-18 SI  $\geq 10$  is indicated in bold underline and is indicative of skin sensitizer as this value is higher than that obtained for lactic acid.



**Figure 3.** Black tattoo inks contain PAHs. Comparative HPLC analysis was performed on the black tattoo inks. (A) shows the PAH identification mixture. Peaks correspond to the following substances: (1) naphthalene; (2) acenaphthylene; (3) fluorene; (4) phenanthrene; (5) anthracene; (6) fluoranthene; (7) pyrene; (8) benz[a]anthracene/chrysene; (9) benzo[b]fluoranthene; (10) benzo[k]fluoranthene; (11) benzo[a]pyrene; (12) dibenz[a,h]anthracene; (13) benzo[ghi]perylene; (14) indeno(1,2,3-C,D) pyrene. (B) Intenze Sculpting Black contains naphthalene, fluorene, and benzo[a]pyrene; (C) Intenze True Black contains phenanthrene and benzo[ghi]perylene; and (D) Carbon Black No. 13 Blackout contains phenanthrene.



research is thereby the first to use an advanced *in vitro* RhS model to study tattoo ink-induced complications observed in patients.

It is now generally accepted that skin sensitization will not be established without xenoinflammation, which involves triggering the inflammasome and the innate immune system (Key Events 2 and 3 in the AOP).<sup>20</sup> Furthermore, the irritant potency of a chemical has been shown *in vivo* and *in vitro* to be directly related to sensitizing potency, and it also has been shown that skin irritation conditions the development and severity of allergic contact dermatitis.<sup>29-32</sup> In this study we demonstrate that the inks varied considerably in their irritant potency as illustrated by the broad range of EC50 values obtained after supplementation of inks into the culture medium of RhS (EC50: 0.04% - EC50: not reached). Notably, Eternal Ink Light Red and Intenze Sculpting Black had an EC50 value in the same range as lactic acid (EC50 < 0.1 %) suggesting that both inks have strong skin irritant and corrosive properties. Furthermore these two inks were able to cause significant IL-18 secretion, a key biomarker for the onset of skin sensitization (Key Event 2).

In our RhS (as well as our RhE) assay, cytotoxicity is required as this results in cell membrane permeability which ensures the release of all intracellularly accumulated IL-18 into the culture supernatant.<sup>23</sup> A background level of IL-18 can be measured after exposure to irritants as well as contact sensitizers. However, only upon exposure to a contact sensitizer, can neosynthesis and intracellular accumulation of IL-18 occur in the cell. Therefore, an increase in IL-18 concentration is indicative of a skin sensitizer in the RhS as well as the RhE model.<sup>23</sup> Since our previous studies used RhE (rather than RhS) we cannot directly use the same prediction model for labeling and classifying sensitizers.<sup>22, 23</sup> The current results indicate that the threshold to distinguish between sensitizers and irritants is slightly higher with RhS compared to the RhE IL-18 SI threshold of 5, since lactic acid in RhS has an IL-18 SI of  $8.3 \pm 3.9$ . This may be due to the presence of fibroblasts in RhS and the different method of chemical exposure (dermal rather than topical epidermal). However, it should be noted that even for commercially available and in house RhE, each model needs to define its own threshold.<sup>23</sup> Notably, in comparison to the other tattoo inks and lactic acid, Eternal Ink Light Red and Intenze Sculpting Black had very high RhS SI IL-18 values (SI:  $88 \pm 45$  and SI:  $62 \pm 15$  respectively), indicating that these inks were activating Key Event 2 of the sensitization AOP. Further investigation with a standard panel of chemicals, as was used in the RhE model<sup>23</sup> is now required to validate the RhS dermal exposure model for comparing sensitizer and irritant potency. However, the assessment of tattoo inks in the RhS model will remain a semi-quantitative assay as it will not be possible to extrapolate the EC50 and SI IL-18 values to the *in vivo* tattoo ink concentrations, as we have done in the past for chemical sensitizers, as currently no tattoo ink human or animal (LLNA) chemical concentration data is available for such correlations.<sup>23</sup> The importance of developing a model which includes a dermal exposure route is illustrated by the clinical study performed by Serup and Hutten Carlsen who patch tested seventy nine patients with suspected allergy to red inks with nine red pigments. Only one ink was able to score as positive in nine of the patients.<sup>6</sup> This may be due to the topical application method used

in patch testing with the red pigments not being able to penetrate the stratum corneum to trigger an immune response or it may be due to pigments used in the study not being present in the red tattoos which showed the allergic symptoms. For these reasons, in our study we chose to expose RhS via the more relevant dermal route and to investigate the complete tattoo inks as obtained from the suppliers.

As shown in Table 1, Eternal Ink Light Red contains the skin sensitizer Pigment Red 170. Therefore it was expected that this ink would score positive as a skin sensitizer in our RhS model (high IL-18 SI:  $88 \pm 45$ ). In comparison, Intenze Gold Label Bright Red, which also causes clinical allergy, does not contain any substances with skin sensitizing potential according to its label. However, based on chemical composition of both the preservative Diazolidinyl Urea and the pigment Orange 13 present in Intenze Gold Label Bright Red, one may expect release of oxidation products with skin sensitizing capacity over time (i.e. formaldehyde and 3,3'-chlorobenzidine). This may explain the difference which we found between Eternal Ink Light Red (positive score as skin sensitizer) and Gold Label Bright Red (negative score as skin sensitizer) in our RhS model. We are aware of the fact that 24 hours of exposure is a current limitation of our RhS model, since this excludes possible toxic effects of red ink pro-electrophiles and pre-electrophiles (OECD 2012). These processes can be studied in the RhS model in the future by extending the exposure time, or by co-exposure with UV-light.

In order to investigate the black inks further, HPLC was used to screen for PAHs. The black inks contained a number of compounds correlating to PAHs with Intenze Sculpting Black containing one compound (peak 11) which was confirmed as being benzo[a]pyrene. Considering the sensitizing (and carcinogenic) properties of PAHs, and in particular of benzo[a]pyrene,<sup>17, 28</sup> these PAHs may be related to the cytotoxicity and high IL-18 release observed after RhS exposure to Intenze Sculpting Black. Although reactions to black inks are reported, such as papulo-nodular reactions and phototoxic reactions, allergic reactions to black tattoo ink rarely occur.<sup>1, 6, 33, 34</sup> One possible explanation for this may be that the PAHs are removed from the skin with time, in contrast to the encapsulated ink pigments.<sup>35, 36</sup> Also, whereas a substantial increase in IL-18 secretion was observed in the RhS after exposure to Intenze Sculpting Black, our RhS-IL18 assay only represents keratinocyte activation (Key Event 2) of the sensitization AOP and further downstream key events such as dendritic cell activation and T cell priming may possibly not occur. This will be a subject for further investigation.

## CONCLUSION

Our results contribute to a better understanding of the tattoo induced complications observed in our outpatient tattoo clinic, where we observed most allergic reactions in red pigmented tattoos.<sup>8, 9</sup> The substantial increase of IL-18 which we observed in RhS exposed to Eternal Ink Light Red supports the clinical data that this ink may be responsible for chronic allergic reactions. As the number of people with a tattoo has been increasing

significantly during the past decade, it is important that adequate safety assessment of tattoo inks takes place. Tattoo inks currently do not fall under European harmonized legislation, but under national regulations based on resolution CoE ResAP (2008)<sup>1,12</sup>. These regulatory frameworks differ between countries: some EU countries do not have specific legislation regarding tattoo safety; some countries do regulate tattooing practices but do not transpose the CoE ResAP into the national legislation; and some countries have adopted either CoE ResAP (2003)<sup>2</sup> or CoE ResAP (2008)<sup>1,37</sup>. The European Chemicals Agency (ECHA) is therefore preparing a dossier for restriction of hazardous chemicals in tattoo inks under the Registration, Evaluation, Authorisation, and Restriction of Chemicals Regulation (REACH, Regulation (EC) No. 1907/2006). This document will provide information on all the required toxicology end-points, based on the tonnages of the substances currently used on the European market.

## ACKNOWLEDGEMENTS

The authors want to acknowledge Dr J.G.M Bolscher for critically reading this manuscript and discussions.

The authors have no conflicts to declare. This study was financed by VU University Medical Center.

## AUTHOR CONTRIBUTIONS

S. Gibbs, S.W. Spiekstra, T. Rustemeyer, S.A.S. van der Bent, and W. Bil designed the research; W. Bil, S.W. Spiekstra, and K. Nazmi performed the research; W. Bil, S.W. Spiekstra and S. Gibbs analyzed the data; W. Bil, S. Gibbs, K. Nazmi, and S.A.S. van der Bent drafted the paper, and W. Bil, S. Gibbs, K. Nazmi, S.W. Spiekstra, S.A.S. van der Bent, and T. Rustemeyer approved the submitted version.

## REFERENCES

1. Piccinini P, Pakalin S, Contor L, Bianchi L, Senaldi C. Safety of tattoos and permanent make-up: Final report. EUR27947, 2016.
2. Falconi M, Teti G, Zago M, Galanzi A, Breschi L, Pelotti S, Ruggeri A, Mazzotti G. Influence of a commercial tattoo ink on protein production in human fibroblasts. *Arch Dermatol Res* 2009; 301: 539-47.
3. Regensburger J, Lehner K, Maisch T, Vasold R, Santarelli F, Engel E, Gollmer A, König B, Landthaler M, Baumler W. Tattoo inks contain polycyclic aromatic hydrocarbons that additionally generate deleterious singlet oxygen. *Exp Dermatol* 2010; 19: e275-81.
4. Neale P A, Stalter D, Tang J Y M, Escher B I. Bioanalytical evidence that chemicals in tattoo ink can induce adaptive stress responses. *J Hazard Mater* 2015; 296: 192-200.
5. Wamer W G, Yin J J. Photocytotoxicity in human dermal fibroblasts elicited by permanent makeup inks containing titanium dioxide. *J Cosmet Sci* 2011; 62: 535-47.
6. Serup J, Carlsen K H. Patch test study of 90 patients with tattoo reactions: negative outcome of allergy patch test to baseline batteries and culprit inks suggests allergen(s) are generated in the skin through haptization. *Contact Dermatitis* 2014; 71: 255-63.
7. Serup J, Carlsen K H, Sepehri M. Tattoo complaints and complications: diagnosis and clinical spectrum. *Curr Probl Dermatol* 2015; 48: 48-60.
8. Van Der Bent S A S, Maijer K I, Rustemeyer T. Image Gallery: Hyperkeratotic hypersensitivity reaction to red pigment tattoo. *Br J Dermatol* 2017; 177: e350.
9. Van Der Bent S A S, Wolkerstorfer A, Rustemeyer T. Cutaneous Adverse Reactions to Tattoos. *Ned Tijdschr Geneesk* 2016; 160: A9808.
10. Carlsen K H, Serup J. Chronic tattoo reactions cause reduced quality of life equaling cumbersome skin diseases. *Curr Probl Dermatol* 2015; 48: 71-5.
11. Piccinini P, Contor L, Pakalin S, Raemaekers T, Senaldi C. Safety of tattoos and permanent make-up. State of play and trends in tattoo practices. EUR27528, 2015.
12. Laux P, Tralau T, Tentschert J, Blume A, Dahouk S A, Bäuml W, Bernstein E, Bocca B, Alimonti A, Colebrook H, De Cuyper C, Dähne L, Hauri U, Howard P C, Janssen P, Katz L, Klitzman B, Kluger N, Krutak L, Platzek T, Scott-Lang V, Serup J, Teubner W, Schreiber I, Wilkniß E, Luch A. A medical-toxicological view of tattooing. *The Lancet* 2016; 387: 395-402.
13. Wijnhoven S W P, Ezendam J, Schuur A G, Loveren H V, Engelen J G M V. Allergens in consumer products. In: RIVM Report 320025001/2008, 2008.
14. Ryberg K, Agner T, Andersen K E, Bircher A, Diepgen T, Foti C, Gimenez-Arnau A, Goncalo M, Goossens A, Johansen J D, Le Coz C, Maibach H I, Bruze M. Patch testing with a textile dye mix--a multicentre study. *Contact Dermatitis* 2014; 71: 215-23.
15. Isaksson M, Ale I, Andersen K E, Diepgen T, Goh C L, Goossens R A, Jerajani H, Maibach H I, Sasseville D, Bruze M. Patch testing to a textile dye mix by the international contact dermatitis research group. *Dermatitis* 2015; 26: 170-6.
16. SCCS. Opinion on Carbon Black (nano-form). In: SCCS/1515/13, 2013.
17. IARC. Carbon black, titanium dioxide, and talc. In: Monographs on the evaluation of Carcinogenic Risk to Humans, 2010.
18. OECD. The Adverse Outcome Pathway for Skin Sensitisation Initiated by Covalent Binding to Proteins. Part 1: Scientific Evidence. Paris OECD Publishing 2012.

19. Rovida C, Alepee N, Api A M, Basketter D A, Bois F Y, Caloni F, Corsini E, Daneshian M, Eskes C, Ezendam J, Fuchs H, Hayden P, Hegele-Hartung C, Hoffmann S, Hubesch B, Jacobs M N, Jaworska J, Kleensang A, Kleinstreuer N, Lalko J, Landsiedel R, Lebreux F, Luechtefeld T, Locatelli M, Mehling A, Natsch A, Pitchford J W, Prater D, Prieto P, Schepky A, Schuurmann G, Smirnova L, Toole C, Van Vliet E, Weisensee D, Hartung T. Integrated Testing Strategies (ITS) for safety assessment. *ALTEX* 2015; 32: 25-40.
20. Martin S F, Esser P R, Weber F C, Jakob T, Freudenberg M A, Schmidt M, Goebeler M. Mechanisms of chemical-induced innate immunity in allergic contact dermatitis. *Allergy* 2011; 66: 1152-63.
21. Corsini E, Galbiati V, Mitjans M, Galli C L, Marinovich M. NCTC 2544 and IL-18 production: a tool for the identification of contact allergens. *Toxicol In Vitro* 2013; 27: 1127-34.
22. Galbiati V, Papale A, Marinovich M, Gibbs S, Roggen E, Corsini E. Development of an in vitro method to estimate the sensitization induction level of contact allergens. *Toxicology Letters* 2017; 271: 1-11.
23. Gibbs S, Corsini E, Spiekstra S W, Galbiati V, Fuchs H W, Degeorge G, Troese M, Hayden P, Deng W, Roggen E. An epidermal equivalent assay for identification and ranking potency of contact sensitizers. *Toxicol Appl Pharmacol* 2013; 272: 529-41.
24. Teunis M, Corsini E, Smits M, Madsen C B, Eltze T, Ezendam J, Galbiati V, Gremmer E, Krul C, Landin A, Landsiedel R, Pieters R, Rasmussen T F, Reinders J, Roggen E, Spiekstra S, Gibbs S. Transfer of a two-tiered keratinocyte assay: IL-18 production by NCTC2544 to determine the skin sensitizing capacity and epidermal equivalent assay to determine sensitizer potency. *Toxicol In Vitro* 2013; 27: 1135-50.
25. Spiekstra S W, Toebak M J, Sampat-Sardjoepersad S, Van Beek P J, Boorsma D M, Stoof T J, Von Blomberg B M, Scheper R J, Bruynzeel D P, Rustemeyer T, Gibbs S. Induction of cytokine (interleukin-1alpha and tumor necrosis factor-alpha) and chemokine (CCL20, CCL27, and CXCL8) alarm signals after allergen and irritant exposure. *Exp Dermatol* 2005; 14: 109-16.
26. Kosten I J, Buskermolen J K, Spiekstra S W, De Gruijl T D, Gibbs S. Gingiva Equivalents Secrete Negligible Amounts of Key Chemokines Involved in Langerhans Cell Migration Compared to Skin Equivalents. *J Immunol Res* 2015; 2015: 627125.
27. Mosmann T. Rapid colorimetric assay for cellular growth and survival: application to proliferation and cytotoxicity assays. *J Immunol Methods* 1983; 65: 55-63.
28. Gerberick G F, Ryan C A, Kern P S, Schlatter H, Dearman R J, Kimber I, Patlewicz G Y, Basketter D A. Compilation of historical local lymph node data for evaluation of skin sensitization alternative methods. *Dermatitis* 2005; 16: 157-202.
29. Basketter D A, Kan-King-Yu D, Dierkes P, Jowsey I R. Does irritation potency contribute to the skin sensitization potency of contact allergens? *Cutan Ocul Toxicol* 2007; 26: 279-86.
30. Bonneville M, Chavagnac C, Vocanson M, Rozieres A, Benetiere J, Pernet I, Denis A, Nicolas J F, Hennino A. Skin contact irritation conditions the development and severity of allergic contact dermatitis. *J Invest Dermatol* 2007; 127: 1430-5.
31. Grabbe S, Steinert M, Mahnke K, Schwartz A, Luger T A, Schwarz T. Dissection of antigenic and irritative effects of epicutaneously applied haptens in mice. Evidence that not the antigenic component but nonspecific proinflammatory effects of haptens determine the concentration-dependent elicitation of allergic contact dermatitis. *J Clin Invest* 1996; 98: 1158-64.

32. Mclelland J, Shuster S, Matthews J N. 'Irritants' increase the response to an allergen in allergic contact dermatitis. *Arch Dermatol* 1991; 127: 1016-9.
33. Sepehri M, Hutton Carlsen K, Serup J. Papulo-Nodular Reactions in Black Tattoos as Markers of Sarcoidosis: Study of 92 Tattoo Reactions from a Hospital Material. *Dermatology* 2016; 232: 679-686.
34. Carlsen K H, Serup J. Photosensitivity and photodynamic events in black, red and blue tattoos are common: A 'Beach Study'. *J Eur Acad Dermatol* 2014; 28: 231-237.
35. Lehner K, Santarelli F, Vasold R, Penning R, Sidoroff A, Konig B, Landthaler M, Baumler W. Black tattoos entail substantial uptake of genotoxic polycyclic aromatic hydrocarbons (PAH) in human skin and regional lymph nodes. *PLoS One* 2014; 9: e92787.
36. Kaur R R, Kirby W, Maibach H. Cutaneous allergic reactions to tattoo ink. *J Cosmet Dermatol* 2009; 8: 295-300.
37. Piccinini P, Bianchi L, Pakalin S, Senaldi C. Safety of tattoos and permanent make-up. Compilation of information on legislative framework and analytical methods. EUR27394, 2015.



7



# **QUANTIFICATION OF CUTANEOUS ALLERGIC REACTIONS USING 3D OPTICAL IMAGING: A FEASIBILITY STUDY**

---

Mark D. den Blanken, Sebastiaan A.S. van der Bent, Niels Liberton, Matthijs Grimbergen, Mark B.M. Hofman, Ruud Verdaasdonk, Thomas Rustemeyer

*Skin Research and Technology. 2020;26(1):67-75.*

# ABSTRACT

## Background

User independent quantitative measures of cutaneous allergic reactions can help the physicians manage and evaluate the treatment of cutaneous allergic reactions. In this paper we present and validate a method to quantify the elevation, volume and area of cutaneous allergic reactions to red tattoos.

## Methods

The skin surface of allergic tattoo reactions was imaged using an optical 3D scanner. The in-house developed analysis tool measured the elevation, volume and area of the lesions, compared to a reference surface. This reference surface was created by 3D interpolation of the skin after manual removal of the lesions. The error of the interpolation tool was validated using a digital arm model. The error of our optical scanner was determined using a 3D printed lesion phantom. The clinical feasibility of the method was tested in 83 lesions in 17 patients.

## Results

The method showed clear potential to assess skin elevation, volume change and area of an allergic reaction. The validation measurements revealed that the error due to interpolation increases for larger interpolation areas, and largely determined the error in the clinical measurements. Lesions with a width  $\geq 4$  mm, and an elevation  $\geq 0.4$  mm could be measured with an error below 26%. Patient measurements showed that lesions up to 600 mm<sup>2</sup> could be measured accurately, and elevation and volume changes could be assessed at follow-up.

## Conclusion

Quantification of cutaneous allergic reactions to red tattoos using 3D optical scanning is feasible and may objectify skin elevation and improve management of the allergic reaction.

## INTRODUCTION

The measurement and quantification of cutaneous allergic reactions is important for treatment management and evaluation, since it provides an objective measure free of inter-observer variation, and enables the medical specialist to compare the cutaneous allergic reactions before and after treatment. In current clinical practice the evaluation of the skin is generally performed in a qualitative manner, such as a description of visible signs of inflammation and structure evaluation by touching the skin.<sup>1</sup> Quantitative measurements such as measuring tape or a caliper are used less frequently. Medical photography might be used as a reference in follow-up, however medical photography only provides a relative quantification. These measurements are user dependent, and therefore the reliability and reproducibility are subject to the skill of the investigator. A frequently used semi-invasive method is a skin patch test;<sup>2</sup> a diagnostic tool to determine sensitization or an allergic reaction. However, this test only provides a subjective measure for the severity of the allergic reaction. A user-independent quantitative method to evaluate allergic lesions can be an improvement. Ultrasound<sup>3</sup> is a user-independent quantitative method, however this method is not commonly used in the clinic for the assessment of allergic reactions.

Since handheld 3-dimensional (3D) scanners can produce high resolution 3D surfaces and have become portable, inexpensive and require little training, they are increasingly used in clinical setting. These scanners typically use structured light to measure surfaces.<sup>4</sup> They have been applied to measure body volumes,<sup>5</sup> to compare BMI with 3D,<sup>6</sup> to study growth defects, to design patient-specific prosthetics,<sup>7</sup> as well as measuring wounds<sup>8</sup> and scar height.<sup>9</sup> But up to now they have not been applied to quantify cutaneous allergic reactions. 3D optical scanning techniques may offer an user-independent, non-invasive, quantitative method for the management or evaluation of skin treatment.

Allergic tattoo reactions are suitable to study the feasibility of 3D optical scanning as the allergic area is chronic, well defined and frequently causing a plaque elevation.<sup>10</sup> Chronic allergic tattoo reactions are predominantly caused by red tattoo ink, and the number of allergic tattoo reactions correlate with the increasing number of aesthetic tattoos.<sup>11</sup>

The purpose of this study is to show the feasibility of 3D optical scanning as a tool to quantify allergic reactions of the skin. Therefore, we developed an analysis tool of the 3D images, and tested the method for accuracy and in patients with one or more allergic tattoo reactions.

## METHODS

### Handheld optical 3D scanner

For this study a handheld optical 3D scanner (Artec Spider, Artec 3D, Luxembourg), henceforth called optical scanner, was used, see figure 1. The optical scanner has a 3D resolution of 0.1 mm and 3D point accuracy of 0.05 mm, which is smaller than the smallest visible allergic reactions. Furthermore the optical scanner has a linear field of view ranging

from 90x70 mm (at 0.17 m) to 180x140 mm (at 0.35 m), so even allergic reactions with a diameter up to 100 mm can be assessed. The frame rate of the optical scanner is 7.5 frames per second, while the exposure time of one frame is 0.5 ms<sup>12</sup>. Thus, the typical scan time to obtain a scan of one side of the fore-arm is about 60 seconds, generating 92-338 images. The optical scanner was operated using a regular laptop (HP ZBook 15, Intel Core i7-4700 MQ CPU @ 2.40 GHz, 24 GB RAM, 64-bit OS) running 3D image acquisition software (Artec Studio v.12 professional, Artec 3D, Luxembourg).

The optical scanner generates data when making a 3D scan. This raw scan data is polygonised, and exported as an Surface Tessellation Language (STL) model, using the 3D image acquisition software of the optical scanner, see figure 2.

7



**Figure 1.** Handheld optical 3D scanner: Artec Spider, Artec 3D, Luxembourg.



**Figure 2.** The top panel shows raw 3D scan data of an allergic tattoo reaction on a leg in the 3D image acquisition software. The bottom panel shows a polygonised surface of the raw 3D scan data.

## Analysis algorithm

The analysis algorithm consists of an interpolation tool, which is required to create a reference surface which is used in the analysis tool, which calculates the elevation, volume and area of the lesions on the STL model.

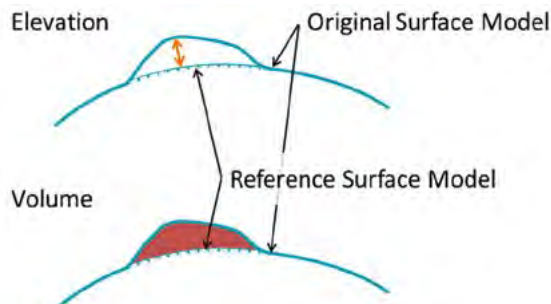
## Interpolation tool

The scanned skin surface, presented by an STL model, is further processed in a software package (GOM Inspect metrology software, Braunschweig, Germany). The surface model is manually positioned such that the z-axis is set perpendicular to the skin surface at the location of the allergic reaction. This is a requirement for the analysis tool. This model is henceforth called original surface model.

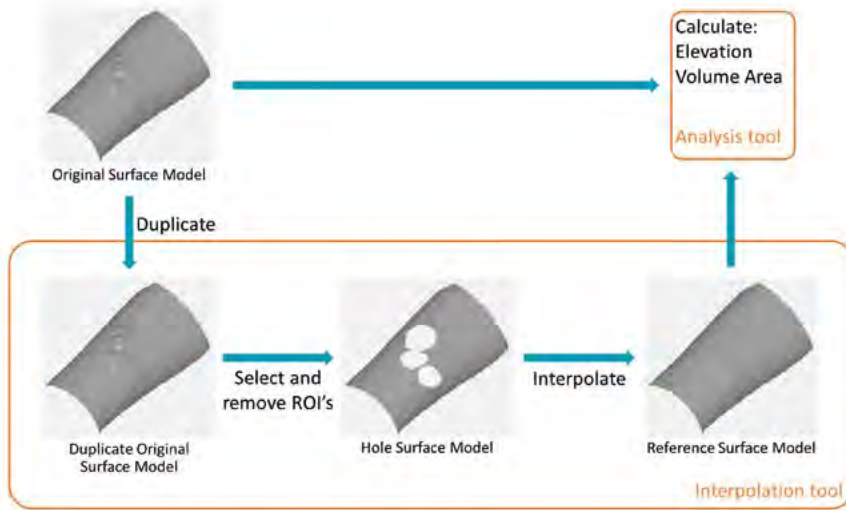
A reference surface model is required to determine the elevation and volume in the analysis tool, see figure 3. The reference surface model represents the shape of the skin without the lesions. To create the reference surface model, regions of interest (ROI's) are selected around the lesions in a duplicate of the original surface model, and removed to create a hole surface model, see figure 4. These ROI's are selected manually closely around the allergic reaction. Subsequently, the surface in the hole surface model is interpolated over the holes using a standard algorithm of the GOM Inspect software (Close Holes Interactively, type Normal, while neighboring polygons were not deleted) to create the reference model. The algorithm interpolates the existing surface based continuity of the surface normal vectors of the surrounding triangles. Both original and reference surface model were exported as ASCII-files containing space coordinates.

## Analysis tool

The analysis tool calculates the elevation, volume and area of lesions from the original surface model and the reference surface model. This tool is in-house developed software within MATLAB (Release 2015b, The MathWorks, Inc., Natick, Massachusetts, United



**Figure 3.** The analysis tool calculates the elevation and the volume of the lesions from the original surface model and the reference surface model. The elevation is given as the maximum distance between the surfaces, whereas the 3D volume is the integrated volume between the surfaces.



**Figure 4.** Flow scheme of the interpolation tool. The tool duplicates the original surface model. ROI's are manually selected around the lesions on the duplicate original surface model, which are subsequently removed to create a hole surface model. The surface is interpolated over the holes to create the reference surface model. The original surface model and the reference surface model are then used to calculate the elevation, volume and area in the analysis tool.

States). The Matlab functions `meshgrid` (resolution of 0.1 mm in x- and y-direction) and `griddata` (linear fit) were used to convert the surface models to a measurable grid (of 0.1x0.1 mm in x- and y-direction), with respective interpolated z-coordinates.

The elevation is assessed by calculating the maximum distance between the two surfaces, see figure 3, based on the normal vector of the reference surface model. The volume is calculated by integrating the volume between the two surfaces. Each gridpoint has a surface area depending on the normal of the surface. The interpolated area is calculated by summation of the areas of all gridpoints in which the original surface model is elevated from the reference surface model. The lesion area is calculated by summation of the areas of all gridpoints in which the elevation (difference between the reference surface model and the original surface model) exceeds a threshold of 0.1 mm.

## Validation

In this section the methods are described for assessing the induced errors by the analysis algorithm and the optical scanner.

## Interpolation induced errors

The interpolation tool creates a reference surface. The accuracy of this algorithm together with the shape of the original surface determines the accuracy of the elevation and volume measurements. The errors induced by the interpolation tool are estimated by applying

the analysis tool to a surface model of a lower arm without any lesions, see figure 5. The lower arm of a volunteer was scanned with the optical scanner. From this data a digital 3D model, henceforth called arm model, was created. The volunteer had no visible lesions on the arm, only a few small naevi.

Duplicates of the arm model were created. In each duplicate an ROI was selected to be removed from the model, in order to create hole surface models. The holes were interpolated to create reference surface models, as described by the interpolation tool. Since the original surface model of the arm had no lesions, the reference surface models intent to be similar to the original surface model. Any deviations between the two surfaces is due to induced errors by the interpolation tool. Using the analysis tool, these errors in the elevation and volume were determined.

ROI's with variable size and position were applied; on 32 positions (8 positions transversally, 4 positions axially) and sizes ranging from 25 to 1200 mm<sup>2</sup>. The ROI's were rectangular for practical reasons. To calculate the standard deviation of the induced error, the results were grouped based on the intended size of the ROI's. The actual size of the ROI's increased somewhat due to the 3D nature of the surfaces, while the selection of the ROI's was performed in a 2D view. The intended sizes of the ROI's were: 5x5mm (25 mm<sup>2</sup>), 10x10 mm (100 mm<sup>2</sup>), 15x15 mm (225 mm<sup>2</sup>), 20x20 mm (400 mm<sup>2</sup>), 20x40 mm (800 mm<sup>2</sup>) and 30x30 mm (900 mm<sup>2</sup>).

The elevation error was measured as the largest distance between the original surface model of the arm and a reference surface per ROI. A positive value was given if the original surface was above the reference surface, and vice versa for a negative value. The same holds for the measurements of the volume error.

### Scanning induced errors

Secondly, the accuracy of the optical scanner in combination with the analysis tool was tested. The measurement errors were quantified using a 3D printed lesion phantom, see figure 6, which was created using MATLAB. The phantom consists of a flat surface with Gaussian shaped lesions. Due to the flat surface, interpolation errors do not contribute. The lesions vary in diameter and in elevation; elevation ranges from 0.1 to 5 mm, and



**Figure 5.** Arm model without any lesions, as applied to quantify the errors induced by the interpolation tool.



7

**Figure 6.** Photo of the 3D printed lesion phantom to quantify the errors induced by using the optical scanner and the analysis tool. The lesion phantom contains Gaussian shaped lesions ranging from 0.1 to 5 mm in elevation and 0.5 to 16 mm in diameter.

the base diameter of the lesion ranges from 0.5 to 16 mm. The standard deviations (SD) defining the Gaussian shaped lesions were chosen such that the height of the Gaussian at the edge of the base area equals the print resolution of the 3D printer (0.1 mm), resulting in a SD ranging from 0.08 to 2.64 mm. The subsequent Gaussian shaped lesions had volumes ranging from 0.004 to 217 mm<sup>3</sup>.

The 3D printed lesion phantom was scanned with the optical scanner, and the analysis algorithm (interpolation tool and analysis tool) was applied to measure the elevation, volume and area of each lesion separately. The 3D printed lesion phantom was scanned 6 times, and the resulting elevation and volume were averaged for each original lesion.

To estimate a total error of a lesion measurement with a specific lesion size, elevation and hole area, the variances (the square of SD's) of the two errors (induced by interpolation and scanning) are added to calculate the combined SD. This total error is shown as the error in the in-vivo results for elevation and volume. The error in the area measurements due to the interpolation tool is not determined in this study.

### **In-vivo feasibility evaluation**

The feasibility of quantification of allergic reactions using the optical 3D scanning method was evaluated in patients with allergic tattoo reactions. Patients were included at The Academic Tattoo Clinic Amsterdam in the period of September 2017 until July



2018. Patients with a constant, chronic cutaneous tattoo reaction, confined to the red area, were included.

After diagnosis was made by the dermatologist, informed consent of the patient was obtained to participate in the study to collaborate voluntarily in the study. If complied, a 3D scan was obtained by moving the optical scanner around the lesion at a skin distance in the range of 17 to 35 cm. Patients with follow-up appointments in the inclusion period were scanned multiple times, typically 2-6 months later.

Patients with allergic tattoo reactions were treated with superpotent topical corticosteroids for several weeks.

The Medical Ethics Review committee of the VU University Medical Center judged that the Medical Research Involving Human Subjects Act did not apply for this study, this is registered at 'Centraal Meldpunt Gegevensverwerking': VUmc\_2017-2434. All patients and the volunteer gave informed consent.

The described analysis algorithm was used to assess elevation, volume and area of lesions caused by allergic tattoo reactions, before and after treatment. In case of multiple distinguishable lesions in a patient, each was measured separately. To evaluate whether individual lesions could be measured accurately, the elevation and volume of each individual lesion are plotted against the lesion area. To evaluate whether changes in elevation and volume of lesions during treatment could be measured significantly, the elevation and volume of individual lesions were plotted for each visit to the outpatient department.

7

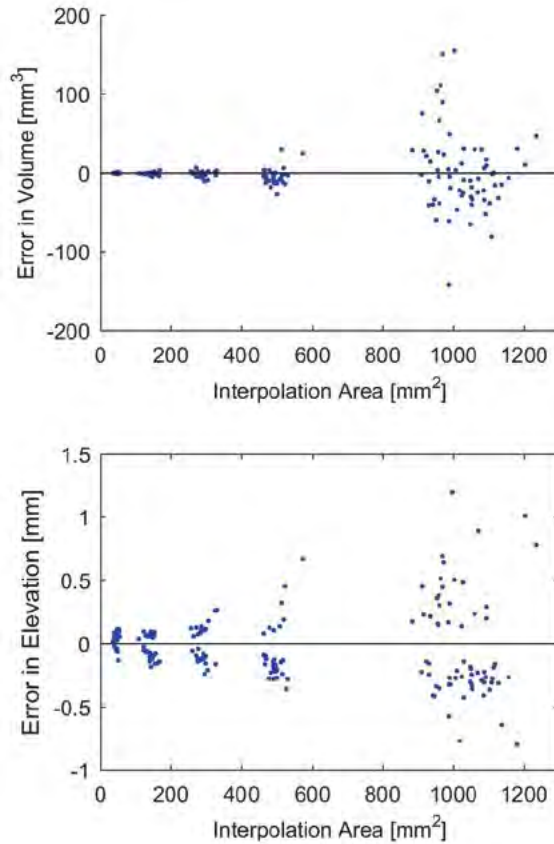
## RESULTS

### Interpolation induced errors

Figure 7 shows the determined error in elevation and volume due to interpolation algorithm in the arm model. The mean error in both elevation and volume enlarges with increasing interpolation area, as also presented in table 1. At large holes, especially rectangular shapes, the interpolation induces large errors.

**Table 1.** Mean error and standard deviations in elevation and volume due to interpolation errors for different size ranges of the interpolation area, as determined from the data of figure 7.

Interpolation area [mm <sup>2</sup> ]	Elevation		Volume	
	Mean [mm]	SD [mm]	Mean [mm <sup>3</sup> ]	SD [mm <sup>3</sup> ]
25 – 100	0.03	0.06	0.02	0.4
100 – 225	-0.03	0.10	-0.5	1.5
225 – 400	-0.02	0.14	-1	3
400 – 800	-0.1	0.2	-4	11
>800 (rectangle)	0.1	0.5	27	83
>800 (square)	-0.1	0.4	-14	29



**Figure 7.** The error in elevation (bottom panel) and the volume (top panel) due to the interpolation tool, plotted against the interpolation area, as assessed in the arm model.

### Scanning induced errors

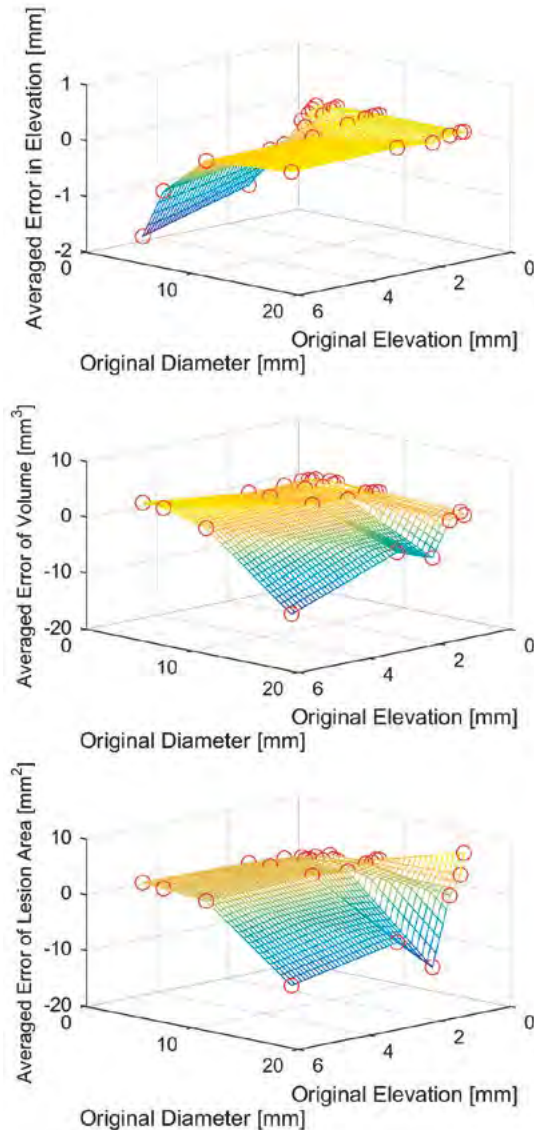
The 3D printed lesion phantom was used to quantify the measurement error induced by the scanning method. Figure 8 shows the average error over 6 measurements of elevation, volume and area for each lesion on the phantom, against the original lesion elevation and diameter. Lesions with a diameter of 4.0 mm and larger, and an elevation 0.2 mm and larger, have a mean error in elevation of  $\leq 26\%$  ( $SD \leq \pm 12\%$ ). Lesions with a diameter of 4.0 mm and larger, and an elevation of 0.5 mm and larger, have a mean error in volume of  $\leq 22\%$  ( $SD \leq \pm 17\%$ ).

### In-vivo feasibility evaluation

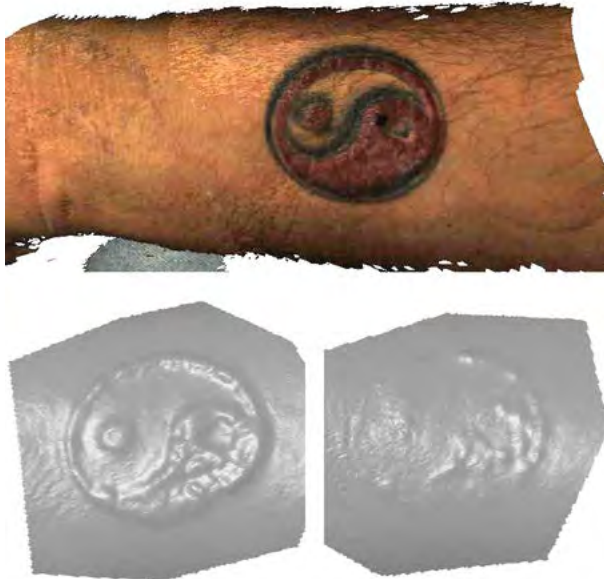17 patients were scanned with the optical scanner. In total 83 lesions were assessed and analyzed. Scanning and analysis was successful in all cases. Making a 3D scan of a lesion using the optical scanner took approximately 60 seconds. The majority of the lesions were on arms (33) and legs (34), others were on the back (10) or elsewhere (6). 6 patients (18

lesions: 7 on arms, 10 on legs, 1 on the back) were scanned during follow-up, 2 patients (8 lesions: 7 on legs, 1 on the back) were scanned during a second follow-up.

The 3D optical scanning method is capable of visualizing the skin elevation effectively as shown in a typical example of a tattoo allergy in figure 9. Especially by removal of the skin and tattoo colors in the 3D surface (in the middle panel) the elevations become clear, as well as the treatment effect in the right panel.



**Figure 8.** The averaged error over 6 measurements in elevation (top panel), volume (middle panel) and area (bottom panel) due to the optical scanner and analysis tool, plotted against the width and elevation of the 3D printed model.



7

**Figure 9.** The images show an allergic tattoo reaction on the lower arm skin of a patient. Shown are the raw 3D scan data the original allergic tattoo reaction (top panel), the 3D surface model prior to treatment (left panel) and the 3D surface at follow-up, after treatment (right panel). Our analysis showed an elevation of 1.2 mm, volume of 390 mm<sup>3</sup>, and area of 1100 mm<sup>2</sup> for this lesion prior to treatment, and an elevation of 0.7 mm, volume of 30 mm<sup>3</sup>, and an area of 380 mm<sup>2</sup> after on follow-up.

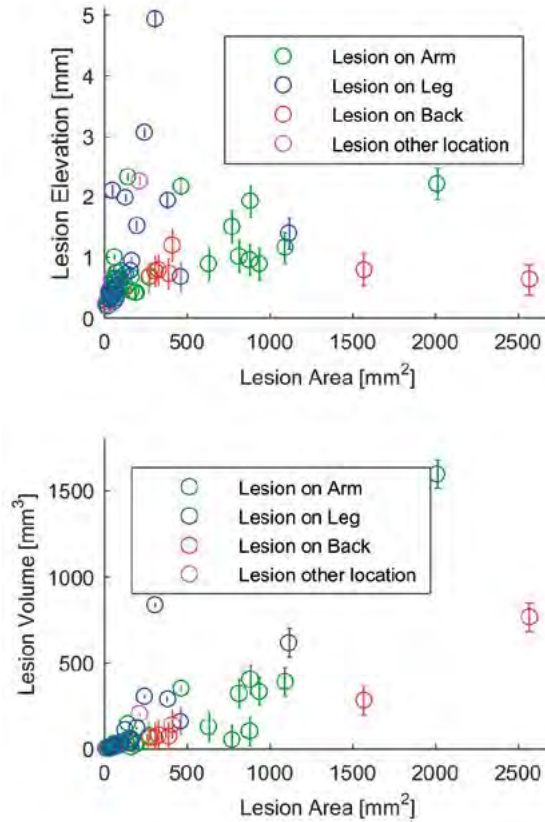
The elevation and volume of all measured lesions against the lesion area is presented in figure 10. The lesions had an elevation between 0.2 and 4.9 mm, a volume between 0.6 and 1600 mm<sup>3</sup>, and an area between 7 and 2600 mm<sup>2</sup>. In this figure the total error due to interpolation and scanning method, as assessed by the validation described above, is shown. Clear is that lesions on arms and legs with an area up to 600 mm<sup>2</sup> can be measured accurately. The total error for in-vivo lesions is dominated by the interpolation induced error.

Figure 11 shows the elevation, volume and area for lesions of patients that had one or more follow-up scans. It shows that changes in elevation, volume and lesion area can be measured significantly.

## DISCUSSION

This paper presents an analysis method to quantify lesions of allergic tattoo reactions using a 3D optical scanner, in terms of elevation, volume and area of a lesion. The method showed to be feasible in a clinical setting, with changes observed in follow-up above the estimated error range.

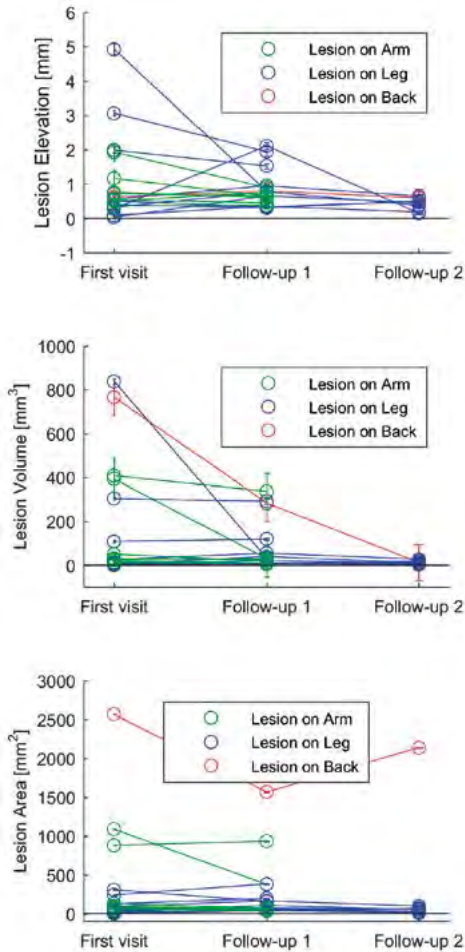
The results show the interpolation algorithm works accurately for arms and legs, with an interpolation area smaller than 600 mm<sup>2</sup>. The shape of skin is determined



**Figure 10.** The measured elevation (top panel) and volume (bottom panel) are plotted against the lesion area for all measured in-vivo lesions. The error bars show the total error due to the interpolation tool and the optical scanning method.

by the underlying structures, such as bone, veins, muscle and fat. If these underlying structures express themselves in the ROI, and are smaller or of a similar size of the ROI, the interpolation tool will not be able to take these into account perfectly, and therefore introduces larger errors. The interpolation tool is able to reconstruct the skin surface as long as all 'information' about the ROI is present in the surrounding skin. Therefore the analysis algorithm worked well on most lesions of the arms and legs, and it showed more difficulties for lesions of an ankle or back (due to the shoulder blades). Therefore the location of lesions in allergic reactions should be researched in the future to minimize the errors made by the interpolation tool. The interpolation tool also seemed vulnerable to physiological skin surface anomalies such as underlying veins and tendons on the edge of the ROI. ROI's were chosen as such to minimize these problems. Patients could be asked to take certain stance to minimize this effect.

The interpolation tool showed a larger SD for rectangular holes compared to square holes, see table 1. The interpolation tool seems dependent on the shape of the hole. Since



**Figure 11.** The measured elevation (top panel), volume (middle panel) and area (bottom panel) for lesions of patients with follow-up 3D scans. The error bars show the total error due to the interpolation tool and the optical scanning method.

tattoos appear in all kind of shapes and sizes, no default shape could be used. Therefore, in the future the dependence of the interpolation tool on shape of the tattoo should be further studied. In the evaluation in patients (figures 7-10) the SD as assessed with ROI's over the whole fore-arm is applied, which is an overestimation of the error in case of lesions in less irregular shaped parts of the skin.

As shown by the results, the optical scanner works accurately for lesions with a diameter of 4 mm and larger. We expect the error for lesions smaller than 4 mm to be caused by the combination of the optical scanner and the analysis algorithm. Lesions with a diameter smaller than 4 mm, typically have an elevation of 0.1-0.2 mm, and 0.1 mm is the resolution of the applied optical scanner.<sup>12</sup>

Most of the evaluated lesions had a diameter above 3 mm and an interpolation area below 600 mm<sup>2</sup>, see figure 10. This study shows that the method is relevant for most, but not all allergic tattoo reactions.<sup>13</sup>

The 3D optical scan method shows in follow-up significant changes in elevation and volume, as can be seen in figure 11. These results were not compared to the clinical outcome of the treatment as assessed by the dermatologist, since the clinical outcome is greatly dependent on the subjective parameter itch,<sup>13</sup> and itch is not measured using our method. However, the quantification of lesions could be used as an objective marker in the evaluation of treatment. This should be further studied in a larger patient cohort. This technique could also be promising as a marker in evaluation of new treatments. This 3D optical scanning method will also be useful for the quantification of allergic reactions in skin patch and prick tests, since the size these lesions are within the limits of the optical scanner and the analysis algorithm.

The acquisition of the 3D data takes approximately 60 seconds. 3D scanning is therefore workable in a clinical setting. However the post processing of the data and the analysis algorithm were applied partial manually in this study, taking about 1 to 2 hours per patient. For clinical use the time for post-processing and the analysis algorithm needs to be reduced to a few minutes. This can be done by combining the analysis in one software environment and further automation.

The optical scanner we applied in this study is an industrial scanner with high specifications. The optical scanner showed potential to quantify measures such as elevation and volume for allergic reactions. Since optical 3D scanners are currently rapidly developing and are becoming more widely available, this technique shows great promise to become a commonly used application.

Follow-up of this work should include a test of reproducibility and inter- or intra-observer variability. Also the clinical value should be studied in a larger patient cohort. Furthermore, the diagnostic value of 3D scanning can be explored in other dermatological fields. All skin lesions with an altered skin surface such as psoriasis, skin tumors, hemangioma, hypertrophic scars<sup>9</sup> and keloids might be assessed and followed in time by this new technology.

## CONCLUSIONS

In this study we developed a method to quantify lesions of allergic tattoo reactions in terms of elevation, volume and area using a 3D optical scanner. The measurement error was quantified using an arm model and a lesion phantom, showing good measurement for lesion with diameters above 2.5 mm and areas smaller than 600 mm<sup>2</sup>. Significant changes in elevation and volume of lesions on arms and legs could be measured over time.

Therefore, we conclude that quantification of lesions of allergic reactions using a 3D optical scanner is feasible. 3D optical scanning is a promising technique for the evaluation and quantification of the effectiveness of (new) therapies.

## REFERENCES

1. Griffiths CEM, Barker J, Bleiker TO, Rook's Textbook of Dermatology, Ninth edition, 2016, Wiley Blackwell.
2. Wilkinson M, Gonçalo M, Aerts O, et al. The European baseline series and recommended additions: 2019, Contact Dermatitis, 2019;80:1-4.
3. Hutton Carlsen K, Tolstrup J, Serup J. High-frequency ultrasound imaging of tattoo reactions with histopathology as a comparative method. Introduction of preoperative ultrasound diagnostics as a guide to therapeutic intervention. *Skin Research and Technology* 2014; 20: 257-264.
4. Georgopoulos A, Ioannidis C, Valanis A. Assessing the performance of a structured light scanner, *International Archives of Photogrammetry, Remote Sensing and Spatial Information Sciences*, Vol. XXXVIII, Part 5, Commission V Symposium, Newcastle upon Tyne, UK. 2010.
5. Wang J, Gallagher D, Thornton JC, et al. Validation of a 3-dimensional photonic scanner for the measurement of body volumes, dimensions, and percentage body fat. *Am J Clin Nutr* 2006;83:809-16.
6. Wells JCK, Treleaven P, Cole TJ. BMI compared with 3-dimensional body shape: the UK National Sizing Survey. *Am J Clin Nutr* 2007;85:419-25.
7. Liacouras P, Garnes J, Roman N et al. Designing and manufacturing an auricular prosthesis using computed tomography, 3-dimensional photographic imaging, and adaptive imaging: a clinical report. *J Prosthet Dent* 2011;105:78-82.
8. Pavlovčič U, Jezeršek M. Handheld 3-dimensional wound measuring system. *Skin Res Technol* 2018;24:326-333.
9. Tyack Z, Simons M, Kimble RM, et al. The reproducibility and clinical utility of the 3D camera for measuring scar thickness, with a protocol for administration. *Skin Res Technol* 2017;23:463-470.
10. Serup J, Hutton Carlsen K. Patch test study of 90 patients with tattoo reactions: Negative outcome of allergy patch test to baseline batteries and culprit inks suggests allergen(s) are generated in the skin through haptization. *Contact Dermatitis* 2014, 71, 255-263.
11. De Cuyper C, Pérez-Cotapos M-L. *Dermatologic Complications with Body Art*. Berlin, Heidelberg, Springer-Verlag, 2010.
12. Artec 3D, Luxembourg. Professional 3D scanning solutions, specifications Artec Spider, 001-05/2016-EUR-ENG. <https://docplayer.net/23932432-Professional-3d-scanning-solutions.html>. Accessed September 4, 2018.
13. Van der Bent SAS, De Winter RW, Wolkerstorfer A, et al. Red tattoo reactions, a prospective cohort on clinical aspects. *J Eur Acad Dermatol Venereol* 2019 May 12. doi: 10.1111/jdv.15677.







**TREATMENT**

8

**ABLATIVE LASER SURGERY FOR  
ALLERGIC TATTOO REACTIONS:  
A RETROSPECTIVE STUDY**

---

Sebastiaan A.S. van der Bent, Sanne Huisman,  
Thomas Rustemeyer, Albert Wolkerstorfer

*Lasers in Medical Science. 2020.*

# ABSTRACT

## Purpose

Patients with allergic tattoo reactions are burdened with itch and have a reduced quality of life. Conservative treatment is often insufficient and little is known about treatment options to remove the responsible allergen.

We aimed to address the effectiveness and safety of ablative laser therapy including measurement of patient's satisfaction, in patients with allergic reactions to tattoos.

## Methods

A retrospective study was conducted including patients with allergic tattoo reactions who were treated with a 10600 nm ablative CO<sub>2</sub> laser, either by full surface ablation or fractional ablation. Clinical information originated from medical files and a 25-item questionnaire.

## Results

Sixteen tattoo allergy patients were treated with a CO<sub>2</sub> laser between January 2010 and January 2018. Fourteen patients completed the questionnaire. Ten patients were satisfied with laser treatment. On a visual analogue scale, pruritus and burning improved with a median of 5,5 and 4 points in the full surface ablation group and 3 points on both parameters in the fractional ablation group.

## Conclusion

Despite the relatively small group of patients, our results suggest that CO<sub>2</sub> laser ablation improves itching, burning and impact on daily life in tattoo allergy.

Key words: red tattoo, contact dermatitis, ablative laser, CO<sub>2</sub> laser, patient reported outcome

## INTRODUCTION

Tattooing is a worldwide popular form of body art with an overall prevalence in Europe and the USA of approximately 10-20%.<sup>1</sup> Although it is regarded safe, adverse reactions may occur, including allergic reactions. Many dyes are used for tattooing, but the red dye is most frequently associated with allergic reactions.<sup>2,3</sup> These reactions are chronic and persistent, characterized by itch, burning and pain and can develop months to many years after getting a tattoo. Regardless of size and location of the affected area, allergic reactions can result in a significantly reduced quality of life.<sup>4</sup> Several clinical subtypes can be recognized of which the 'plaque type' is most common. Other, less common types are the 'excessive hyperkeratotic reaction' or the 'ulcero-necrotic reaction'.<sup>5,6</sup> Thus far, the responsible allergens have not been identified and the exact patho-mechanism remains unknown.<sup>7-9</sup>

Treatment of these allergic reactions is difficult, as tattoo pigments are permanently stored in the dermis. Topical or intralesional corticosteroids are indicated as first line treatment but effects are often temporary and unsatisfactory.<sup>10</sup> Allopurinol was reported to be effective in one patient, however symptoms recurred after withdrawal of the drug.<sup>11</sup> Likewise, hydroxychloroquine caused complete regression of pseudolymphomatous tattoo reaction on the trunk and a granulomatous reaction to a red cosmetic tattoo.<sup>12,13</sup> To achieve permanent remission, the causative allergen needs to be removed. However, the best treatment option to remove the responsible allergen is unknown. Surgical excision, dermatome shaving, Q-switched lasers and ablative CO<sub>2</sub> lasers are reported as treatment options with permanent results.<sup>14,15</sup> Nevertheless, each treatment option has its disadvantages, such as possible scarring, infection, risk of generalized allergic reactions and treatment imprecision.

Millán Cayetano et al. considered the continuous wave CO<sub>2</sub> laser as an effective, safe and precise treatment for improving red tattoo reactions in six patients.<sup>16</sup> Fractional ablation was effectively and safely used for removal of allergic tattoo reactions in three patients.<sup>17,18</sup> Apart from these small studies, clinical efficacy has been studied insufficiently. Furthermore, patient reported outcome measures (PROMs) have not been thoroughly investigated in this field. PROMs are crucial as quality of life and symptom reduction are best assessed by patients themselves.<sup>19</sup> The aim of this study was to report real life data using ablative laser treatment and to assess PROMs regarding the effectiveness and safety of ablative CO<sub>2</sub> laser treatment for allergic tattoo reactions.

## MATERIAL AND METHODS

We performed a retrospective study in which we included patients with allergic tattoo reactions treated with the 10600 nm ablative CO<sub>2</sub> laser (Lumenis Ultrapulse Encore, Lumenis Ltd., Santa Clara, CA, USA) using a handpiece for full surface ablation (2 mm true spot) and/or a handpiece for fractional ablation (DeepFx handpiece, 120 µm beam diameter). Patients were treated between January 2010 and December 2017.

Patients were eligible for inclusion if clinically an allergic reaction was diagnosed and if they were treated with the ablative CO<sub>2</sub> laser. Allergic tattoo reactions were defined as chronic inflammatory reactions, manifesting in one single colour and persisting for at least 3 months.<sup>5,19</sup> As there are currently no routine patch tests, the distinction between an allergic tattoo reaction, sarcoidosis and foreign body reaction is mostly clinical (the allergic tattoo reaction is localized to one specific color).<sup>21,22</sup> Furthermore, the histopathology of allergic tattoo reactions is frequently granulomatous as well<sup>20</sup>. Nevertheless, if histologically a granulomatous reaction was observed, laboratory test (including ACE and in some cases sIL-2R) and chest X-ray were performed to exclude sarcoidosis. However, as there is no routine patch test, the distinction between an allergic tattoo reaction, sarcoidosis and foreign body reactions is mostly clinical.

Based on the clinical information provided by the physician, patients and physician made a shared decision about the preferred treatment, either fractional or full surface ablation.

All patients received a test treatment 3 months before the full treatment was started to assess effectiveness and cosmetic outcomes on a small test area.

All patients received infiltration anaesthesia (lidocaine 2% + adrenaline 1:80000).

Fractional ablation settings ranged from 25-40 mJ/microbeam and 15-25% density. Full surface ablation was performed with a 2 mm spot, 225 mJ and 10-30W combined with wet gauzes to remove carbonized tissue between laser passes. The clinical endpoint of the full surface ablation was the complete removal of red pigments.

After fractional ablation, patients received fucidic acid 20mg/g cream twice daily for 1 week. After full surface ablation, patients received silver sulfadiazine 10 mg/g cream under hydrofiber absorbent dressings for 1 week. After 1 week when the dressings were removed, patients applied silver sulfadiazine 10 mg/g cream twice daily until healing of the wound was observed. In the case of large areas treated with full surface ablation, systemic antibiotics were used.

Clinical information was obtained from patient's records and a 25-question questionnaire, addressing 3 topics. The questionnaire was performed retrospectively in December 2017 and January 2018. Overall primary end point was patient satisfaction. The questionnaire focused on 3 topics; clinical baseline information, symptoms and outcomes.

*Clinical baseline information:* time interval between placement of tattoo and complaints, previous treatments. The time interval was based on an ordinal scale. Previous treatment options were given and could either be answered with yes or no. If patients received previous treatment, effects were analysed on an ordinal scale (from no effect to excellent effect).

*Symptoms:* subjective symptoms before and after laser therapy, such as itch and burning. These questions were based on a visual analogue scale (VAS, 0-10), with 0 meaning no itch or burning and 10 meaning the worst itch or burning.

*Outcomes:* overall satisfaction, cosmetic outcome and satisfaction with improvement of pruritus, burning, inflammation and influence on daily life were based on an ordinal



scale (from highly unsatisfied to highly satisfied). Evaluation of pain and discomfort during treatment was based on a VAS (0-10), with 0 meaning no pain or discomfort and 10 meaning the worst pain or discomfort. Scar formation and pigment variation could be answered with either yes or no. If present, the burden of scars and pigment variation were based on a VAS (0-10), with 0 meaning no burden and 10 meaning the worst burden.

A statistical analysis was performed. Outcomes between groups were compared using the student's t-test, Mann-Whitney-U test or Kruskal-Wallis test depending on distribution and the number of groups. Categorical data was compared using the Chi2 test or the Fisher's exact test depending on group sizes.

## RESULTS

### Patient characteristics

Sixteen patients (11 women, 5 men) were treated with an ablative CO<sub>2</sub> laser. Two patients were first treated with the fractional CO<sub>2</sub> laser without clinical improvement and were therefore also treated with full surface ablation. Therefore, 10 patients were treated with the fractional CO<sub>2</sub> laser and 8 patients were treated with the full-surface CO<sub>2</sub> laser.

The median age was 44.5 years. Red or nuances of red made up for 94% of all responsible pigments. Other patient characteristics are shown in **Table 1**.

All patients had received prior treatment, such as topical and/or intralesional corticosteroids and Q-switched laser therapy. Prior treatment either failed or patients desired a more permanent solution.

The number of sessions needed varied between both groups, with a median of 1 in the full-surface CO<sub>2</sub> laser group and a median of 4 in the fractional CO<sub>2</sub> laser group ( $P < 0,01$ ).

### Results from medical files

The medical files indicated complete remission of symptoms, such as itching, burning or swelling, in six patients (33,3%), which was maintained until the last follow-up. Nine patients had partial remission (50%) and maintained occasional itching or burning. Potent topical corticosteroids were prescribed in some patients to control these residual symptoms. Results of medical files are shown in **table 2**.

Two adverse events were reported. One patient with skin type 4 developed a keloidal scar after full surface ablation on his upper arm. The other patient developed a generalized allergic reaction one day after the fifth fractional CO<sub>2</sub> laser treatment. Eczema developed around the tattoo, on arms, face and knees. She was treated with oral antihistamines and topical potent corticosteroids resulting in gradual improvement of the eczematous reaction. This case was reported previously.<sup>18</sup>

**Table 1.** Baseline characteristics of 18 treatments in 16 patients.

	All (n=18)	GROUP A (Full surface ablation) n = 8	GROUP B (Fractional ablation) n=10
Age (years)			
Median [Q1 - Q3]	44,5 [36 - 52,25]	44,5 [36,25 - 57,75]	44,5 [35,75 - 52,25]
Gender, n			
Male	6	5	7
Female	12	3	3
Time between placement of tattoo and complaints, n			
<2 weeks	7	2	5
> 2 - < 4 weeks	3	2	1
> 1 - < 3 months	3	2	1
> 3 - < 6 months	4	2	2
>6 - < 12 months	0	0	0
> 12 months	1	0	1
Histopathological pattern, n			
Pseudolymphomatous	4	4	0
Granulomatous	4	2	2
Pseudolymphomatous/ granulomatous	1	1	0
Not available	9	1	8
Location, n			
Lower leg/ankle	12	6	6
Upper leg	1	0	1
Forearm	3	1	2
Upper arm	2	1	1
Colour, n			
Red	17	7	10
Black	1	1	0
Previous treatment, n			
Potent topical corticosteroids	6	1	5
Potent topical and intralesional corticosteroids	7	5	2
Intralesional corticosteroids	3	1	2
Potent topical corticosteroids and other laser treatment	2	1	1

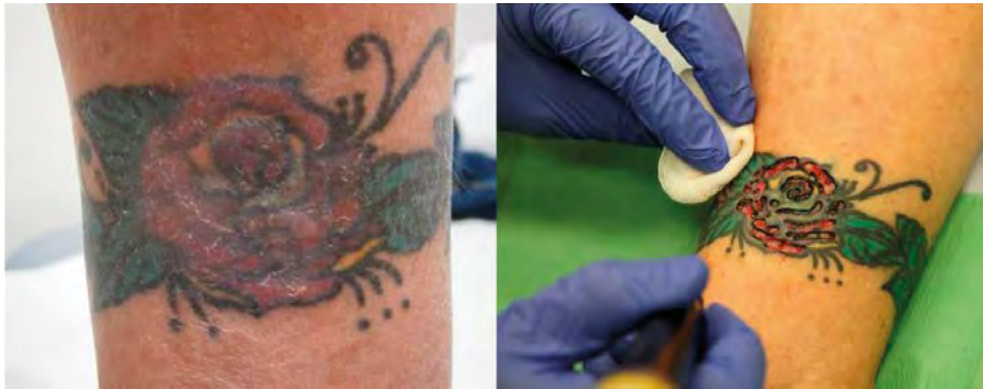Q1-Q3 = interquartile range

## Patient reported outcomes

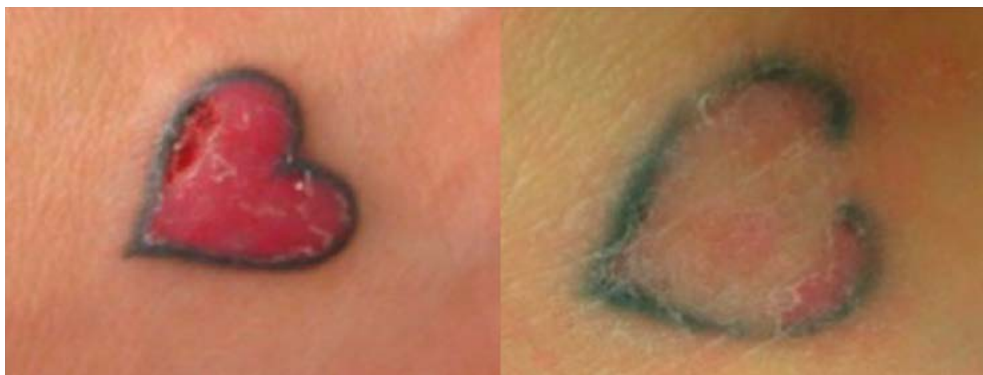Two patients did not complete the questionnaire. Thus, 16 patients responded (88%). PROMs are shown in **table 3**. From the responding patients, ten patients reported to be either satisfied or highly satisfied with ablative laser treatment (62,5%). Six patients reported to be satisfied with the cosmetic aspect after ablative laser treatment (37,5%), 4 patients were neutral (25%), 6 patients were unsatisfied or highly unsatisfied (37,5%).

**Table 2.** Results from medical files, not patient reported.

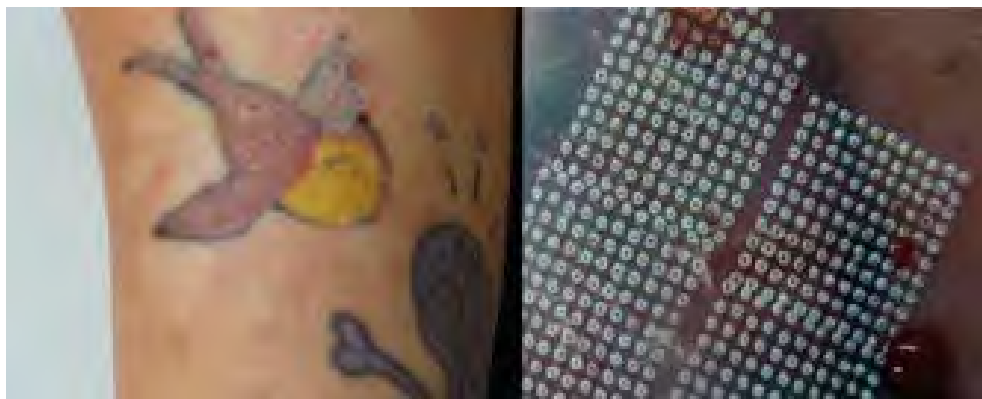
	All (n=18)	GROUP A (Full surface ablation) n = 8	GROUP B (Fractional ablation) n=10
Number of sessions			
Median [Q1 - Q3]	2,5 [1 – 4,25]	1 [1 – 1,75]	4 [3 – 6,25]
Follow-up (months)			
Median [Q1 - Q3]	14 [9,25 – 39,75]	8,5 [4,75 – 11,75]	31 [20,5 - 60]
Result after treatment, n (%)			
Complete remission	6 (33,3)	3 (37,5)	3 (30)
Partial remission	9 (50)	4 (50)	5 (50)
No improvement	3 (16,7)	1 (12,5)	2 (20)



**Figure 1.** Before and during treatment of a tattoo reaction ('plaque type') to red dye in a multi-coloured tattoo on the lower leg.

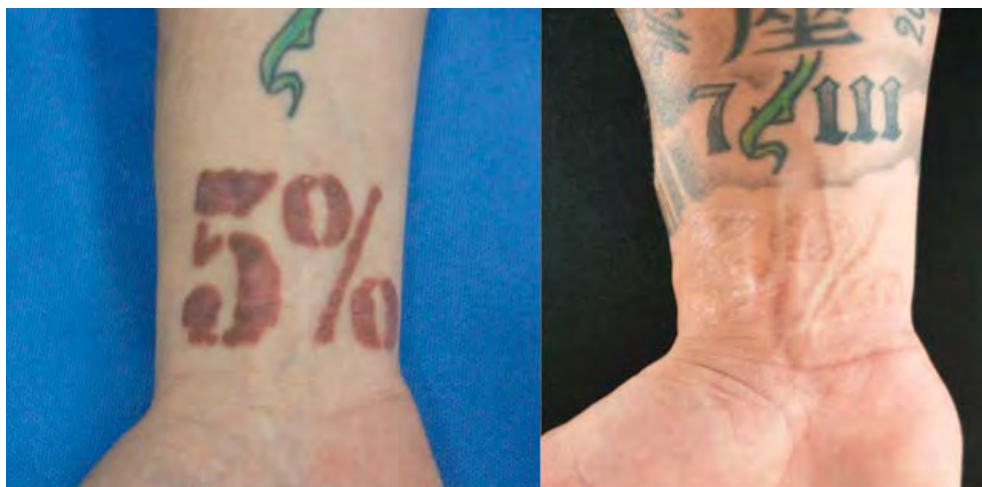

**Figure 2.** Before and after treatment of a red tattoo reaction treated with fractional ablation.



**Figure 3.** A red tattoo reaction ('plaque type') during treatment with fractional ablation.

8



**Figure 4.** Before and after of a red tattoo reaction ('plaque type') on the wrist treated with full surface ablation.

Patients rated pain and discomfort of ablative laser therapy with a median VAS score of 3 on both parameters ( $P = 0,67$  and  $0,83$ , respectively for pain and discomfort).

Scar formation was reported in 6 patients in the full surface ablation group and 5 patients in the fractional ablation group ( $P = 1,00$ ). Variation in pigment was reported in 7 patients in the full surface ablation group and 4 patients in the fractional ablation group ( $P = 0,28$ ).

Common complaints before starting laser treatment were a burning sensation (93%) and pruritis (100%). Improvement on a VAS scale (0-10) was found, for both, burning sensation and pruritis. When comparing improvement of itch and burning between the full

**Table 3.** Patient reported outcome of 16 treated tattoos in 14 patients.

	All (N=16)	GROUP A (Full surface ablation) N = 8	GROUP B (Fractional ablation) N = 8	P value
Satisfaction with				
Laser treatment, n (%)				0,45
Highly satisfied	3 (18,8)	2 (25)	1 (12,5)	
Satisfied	7 (43,8)	4 (50)	3 (37,5)	
Neutral	3 (12,5)	0	3 (37,5)	
Unsatisfied	2 (12,5)	1 (12,5)	1 (12,5)	
Highly unsatisfied	1 (6,3)	1 (12,5)	0	
Cosmetic aspect, n (%)				0,59
Highly satisfied	0	0	0	
Satisfied	6 (37,5)	4 (50)	2 (25)	
Neutral	4 (25)	1 (12,5)	3 (37,5)	
Unsatisfied	3 (18,8)	2 (25)	1 (12,5)	
Highly unsatisfied	3 (18,8)	1 (12,5)	2 (25)	
Improvement itch and burning, n (%)				0,93
Highly satisfied	4 (25)	3 (37,5)	1 (12,5)	
Satisfied	2 (12,5)	1 (12,5)	1 (12,5)	
Neutral	2 (12,5)	1 (12,5)	1 (12,5)	
Unsatisfied	4 (25)	1 (12,5)	3 (37,5)	
Highly unsatisfied	4 (25)	2 (25)	2 (25)	
Improvement inflammation, n (%)				0,52
Highly satisfied	3 (18,8)	2 (25)	1 (12,5)	
Satisfied	6 (37,5)	3 (37,5)	3 (37,5)	
Neutral	2 (12,5)	0	2 (25)	
Unsatisfied	3 (18,8)	1 (12,5)	2 (25)	
Highly unsatisfied	2 (12,5)	2 (25)	0	
Evaluation of laser therapy				
Pain (median [Q1-Q3])*	3 [1,25 - 5]	3 [2,25-4,5]	3,5 [0,25-5]	0,67
Discomfort (median [Q1-Q3])*	3 [1- 5]	2,5 [1,25-3,75]	3,5 [0,25-5,75]	0,83
Adverse effects				
Scars, n (%)	11 (68,8)	6 (75)	5 (62,5)	1,00
Level of inconvenience (median [Q1-Q3])*	2,5 [1-6,75]	2,5 [0,75-7,75]	5 [0,5-7]	1,00
Variation in pigment, n (%)	11 (68,8)	7 (87,5)	4 (50)	0,28
Level of inconvenience (median [Q1-Q3])*	4 [1-5]	4 [0 - 7]	4,5 [1,75-5]	0,92
Improvement of symptoms				
Itch (median [Q1 - Q3]) *	4.5 [7,75-0,25]	5,5 [8 - 0]	3 [7,25-0,25]	0,71
Burning (median [Q1 - Q3]) *	4 [7-0]	4 [7 - 0]	3 [7,75-0,75]	0,91
Influence on daily life (median [Q1 - Q3]) *	2 [4 - 0]	3 [4 - 0]	2 [3,75 - 0,25]	1,00
Recommendation, n (%)	11 (68,8)	7 (87,5)	4 (50)	0,28

Q1-Q3 = interquartile range.

surface ablation group (median of 5.5 for itch and 4 for burning) and fractional ablation group (median of 3 for both itch and burning), it should be noted that more improvement was observed in full surface ablation. However, the difference is not statistically significant ( $P = 0,71$  and  $0,91$ , respectively for itch and burning).

The vast majority of the full surface ablation group would recommend this therapy to others (87.5%), in the fractional ablation group 4 patients (50%) gave a recommendation ( $P = 0,28$ )

## DISCUSSION

Patients suffering from allergic tattoo reactions are burdened with chronic itch and discomfort.<sup>4</sup> Treatment is challenging. Topical or intralesional corticosteroids are convenient options, however effectiveness varies and is frequently temporary or insufficient. A safe treatment modality with permanent results is needed. Removal of all culprit pigment by surgery or laser ablation is thought to be the best approach. However, there are variable techniques to remove the pigments and little is known about efficacy, side effects and PROMs. In our study, we found that CO<sub>2</sub> laser therapy can improve the symptoms of allergic tattoo reactions when topical or intralesional corticosteroids are insufficiently effective. Six allergic tattoo reactions showed complete remission (33,3%), 9 showed partial remission (50%) and 3 lesions showed no improvement (16,7%) after a median follow-up of 14 months. Remarkably, in some cases with satisfactory outcome, we observed some residual red pigment questioning the necessity of complete removal of pigment.

### Fractional and full surface ablation

Patients were overall satisfied with the treatment and reported marked improvement of their symptoms. When comparing our treatment groups, more improvement was reported in the full surface ablation group. Fractional ablation is less invasive with less side effects in comparison to full surface ablation, however at the cost of multiple treatments and possibly lower efficacy. The difference could not be significantly confirmed. Because of this, the study design and the relatively small group of patients, it cannot be concluded that full surface ablation is superior in effectiveness to fractional ablation.

### Adverse events

It should be noted that adverse effects, such as scarring and allergic reactions, may occur. Full surface ablation has a higher risk of scarring compared to fractional ablation.<sup>16</sup> This could be explained by the fact that conventional CO<sub>2</sub> lasers ablate the full surface of the skin, while fractional CO<sub>2</sub> lasers ablate a fraction of the skin at a time by emitting microbeams that create microthermal ablation and coagulation zones leaving unaffected tissue around these zones. In our study, no significant difference in scarring between both groups were observed.

In one patient a generalized eczematous allergic reaction was observed after fractional ablation, treated in our Academic Tattoo Clinic. More cases of generalized allergic reactions after fractional laser therapy to treat allergic tattoo reactions have been reported.<sup>18,23</sup> We assume that full surface ablation completely eliminates pigment containing cells, thereby preventing systematic uptake. However, in fractional ablation the ablative channels are small and surrounded by coagulation zones which may be responsible for systemic uptake of allergens.<sup>18</sup> In addition, dyspigmentation is reported several times.

### Other treatment options

Other surgical treatment options are conventional full-thickness excision and dermatome shaving. Conventional excision is only favourable in certain anatomical locations and small size tattoos. In addition, scarring is inevitable. Dermatome shaving is an excellent permanent treatment option. However, in this procedure an experienced plastic surgeon or dermatologist is crucial. Furthermore, in our opinion, CO<sub>2</sub> lasers have the possibility of treating more accurately in a horizontal plane, resulting in better preservation of the original tattoo design. The pigment-loaded tissue can be removed layer by layer until the desired endpoint, removal of pigment, is achieved. As the depth of the tattoo inks in the skin differs, it is an advantage that the depth of laser treatment can be adjusted.

Dermatome shaving may also elicit complications such as scarring, hyper- and hypopigmentation, which required additional treatments with intralesional corticosteroids in almost 20% to control scarring.<sup>14</sup> Furthermore, in contrary to dermatome shaving, ablative laser therapy is not a bloody procedure due to surrounding coagulation. Experienced laser surgeons can take advantage of this phenomenon and vary the ratio between ablation and coagulation by adjusting the pulse energy. Therefore, the risk of post-procedure bleeding is smaller.

Another treatment option for allergic tattoo reactions is the Q-switched laser. Unlike ablative lasers, Q-switched lasers are the gold standard for removal of uncomplicated tattoos.<sup>24</sup> Q-switched lasers selectively damage pigment containing cells, after which pigment particles are released into systemic circulation. The photomechanical breakdown of pigments may also produce and systemically spread new allergens and harmful chemicals. Several cases of localized, generalized and even anaphylactic allergic reactions have been reported following Q-switched laser tattoo removal in patients with a pre-existent allergic reaction to tattoo pigments or even in prior non-allergic patients.<sup>25-28</sup> Besides the risk of inducing systemic allergic reactions, treatment efficacy for allergic tattoo reactions to red pigment with a Q-switched-laser is compromised because of the limited penetration depth at 532 nm, whilst in 'plaque reactions' an evident thickening arises with deeply located pigments. Moreover, Q-switched lasers may require more than ten treatments.

Thus far this is the largest study of ablative laser therapy in allergic tattoo reactions. Another strength of this study is the long follow-up and the presence of real life data. Limitations of this study are its retrospective nature, the limited number of included patients

and the descriptive analysis. Also, patients were not laser-naïve. The response rate of the questionnaire was 88%, which is high. However, it should be noted that some patients had to assess their clinical symptoms years after the initial diagnosis and treatment.

Unfortunately, two patients were lost to follow-up. Furthermore, no validated outcome measures could be used due to a lack of research in this field. Future research should be prospective and include an objective evaluation of improvement of skin inflammation.

Despite the relatively small group of patients, our results suggest that CO<sub>2</sub> laser ablation (either fractional or full surface ablation) improves itching, burning and impact on daily life in tattoo allergy. It may be implemented as third line treatment, when topical or intralesional corticosteroids are insufficiently effective. Patients seem to prefer the full surface ablation above fractional ablation, which may result from higher effectiveness and less treatment sessions. However, this could not be statistically confirmed. Patients should be thoroughly informed about the possible risks, especially scar and keloid formation. More evidence is needed before final recommendations can be given.



## REFERENCES

1. Kluger N. Epidemiology of tattoos in industrialized countries. *Curr Probl Dermatol.* 2015;48:6-20.
2. De Cuyper C. Cosmetic and Medical Applications of Tattooing. In: Cuyper C.D., Pérez-Cotapos S M.L. (eds) *Dermatologic Complications with Body Art.* Springer, Berlin, Heidelberg, 2009.
3. Van der Bent SA, Wolkerstorfer A, Rustemeyer T. Cutaneous adverse reactions to tattoos. *Ned Tijdschr Geneesk.* 2016;160:A9808.
4. Hutton Carlsen K, Serup J. Patients with tattoo reactions have reduced quality of life and suffer from itch. *Skin Res Technol.* 2014;21:101-107.
5. Serup J, Carlsen KH, Sepehri M. Tattoo complaints and complications: diagnosis and clinical spectrum. *Curr Probl Dermatol.* 2015;48:48-60.
6. Van der Bent SAS, Maijer KI, Rustemeyer T. Image Gallery: Hyperkeratotic hypersensitivity reaction to red pigment tattoo. *Br J Dermatol.* 2017;177:e350.
7. Serup J, Hutton Carlsen K. Patch test study of 90 patients with tattoo reactions: negative outcome of allergy patch test to baseline batteries and culprit inks suggests allergen(s) are generated in the skin through haptentization. *Contact Dermatitis.* 2014;71:255-63.
8. Bil W, van der Bent SAS, Spiekstra SW, Nazmi K, Rustemeyer T, Gibbs S. Comparison of the skin sensitization potential of 3 red and 2 black tattoo inks using interleukin-18 as a biomarker in a reconstructed human skin model. *Contact Dermatitis.* 2018; 79:336-345.
9. Van der Bent SAS, de Winter RW, Wolkerstorfer A, Rustemeyer T. Red tattoo reactions, a prospective cohort on clinical aspects. *Journal of the European Academy of Dermatology and Venereology.* 2019; May 12.
10. Wambier CG, Cappel MA, Wambier SPF. Treatment of reaction to red tattoo ink with intralesional triamcinolone. *An Bras Dermatol.* 2017;95:748-50.
11. Godinho MM, Aguinaga F, Grynszpan R, Lima VM, Azulay DR, Cuzzi T, Ramos-E-Silva M, Manela-Azulay M. Granulomatous reaction to red tattoo pigment treated with allopurinol. *J Cosmet Dermatol.* 2015;14:241-5.
12. Patrizi A, Raone B, Savoia F, Bacci F, Pileri A, Gurioli C, Neri I. Tattoo-associated pseudolymphomatous reaction and its successful treatment with hydroxychloroquine. *Acta Derm Venereol.* 2009;89(3):327-8.
13. De Winter RW, van der Bent SAS, van Esch M, Wolkerstorfer A, Rustemeyer T. Allergic Reaction to Red Cosmetic Lip Tattoo Treated With Hydroxychloroquine. *Dermatitis.* 2019;30(1):82-83.
14. Sepehri M, Jørgensen B, Serup J. Introduction of dermatome shaving as first line treatment of chronic tattoo reactions. *J Dermatolog Treat.* 2015;26:451-455.
15. Forbat E, Al-Niaimi F. Patterns of Reactions to Red Pigment Tattoo and Treatment Methods. *Dermatol Ther.* 2016;6:13-23.
16. Millán-Cayetano, J.F., Alegre-Sánchez, A. & Boixeda, P. Treatment of red tattoo reactions using CO<sub>2</sub> laser. *Lasers Med Sci.* 2017;1-3.
17. Ibrahim OA, Syed Z, Sakamoto FH, Avram MM, Anderson RR. Treatment of tattoo allergy with ablative fractional resurfacing: a novel paradigm for tattoo removal. *J Am Acad Dermatol.* 2011;64:1111-1114.
18. Meesters AA, De Rie MA, Wolkerstorfer A. Generalized eczematous reaction after fractional carbon dioxide laser therapy for tattoo allergy. *J Cosmet Laser Ther.* 2016;18:456-458.

19. Prinsen CAC, Mokkink LB, Bouter LM, Alonso J, Patrick DL, de Vet HCW, Terwee CB. COSMIN guideline for systematic reviews of patient-reported outcome measures. *Qual Life Res.* 2018.
20. Van der Bent SAS, Oyen EMM, Rustemeyer T, Jaspars EH, Hoekzema R. Histopathology of red tattoo reactions. *American Journal of Dermatopathology.* Accepted.
21. Kluger N. Cutaneous Complications Related to Tattoos: 31 Cases from Finland. *Dermatology.* 2017;233:100-109.
22. Maijer KI, van der Bent SAS, Vercootere W, Rustemeyer T1. Granulomatous Tattoo reaction with Associated Uveitis successfully treated with methotrexate. *J Eur Acad Dermatol Venereol.* 2018. doi: 10.1111/jdv.14854.
23. Zemtsov A, Wilson L. CO<sub>2</sub> laser treatment causes local tattoo allergic reaction to become generalized. *Acta Derm Venereol.* 1997;77:497.
24. Prinz BM, Vavricka SR, Graf P, et al. Efficacy of laser treatment of tattoos using lasers emitting wavelengths of 532 nm, 755 nm and 1064 nm. *Br J Dermatol.* 2004;150:245-251
25. England RW, Vogel P, Hagan L. Immediate cutaneous hypersensitivity after treatment of tattoo with Nd:YAG laser: a case report and review of the literature. *Ann Allergy Asthma Immunol.* 2002;89:215-217.
26. Harper J, Losch AE, Otto SG, Zirwas M, Delaney KO, Wakelin JK, 3rd. New insight into the pathophysiology of tattoo reactions following laser tattoo removal. *Plast Reconstr Surg.* 2010;126:313e-314e.
27. Ashinoff R, Levine VJ, Soter NA. Allergic reactions to tattoo pigment after laser treatment. *Dermatol Surg.* 1995;21:291-294.
28. Yorulmaz A, Onan DT, Artuz F, Gunes R. A case of generalized allergic contact dermatitis after laser tattoo removal. *Cutan Ocul Toxicol.* 2015;34:234-236.



9a

**GRANULOMATOUS TATTOO  
REACTION WITH ASSOCIATED  
UVEITIS SUCCESSFULLY TREATED  
WITH METHOTREXATE**

---

Karen I. Majjer, Sebastiaan A.S. van der Bent,  
Ward Vercootere, Thomas Rustemeyer

*Journal of the European Academy of Dermatology and Venereology. 2018;32(9):e338-e339.*



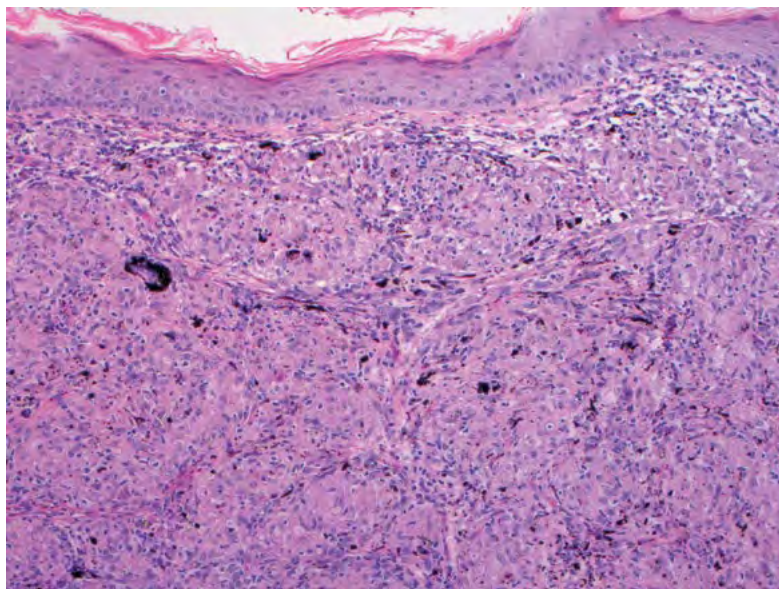
Few reports describe tattoo granulomas with the simultaneous development of intraocular inflammation without any evidence of systemic sarcoidosis at the time of presentation.<sup>1-4</sup> Here, we present a patient with no prior diagnosis of sarcoidosis who developed inflammation of the tattooed skin and shortly after bilateral uveitis.

A 52-year-old previously healthy woman presented with an 8-month history of swelling and itching located in all of her 11 black tattoos. Approximately 5 months later, she developed complaints of blurred vision, diagnosed as recurrent uveitis anterior by an ophthalmologist. The last tattoo was performed 8 years ago. On physical examination, she presented with confluent papules and nodules in all black tattoos (Fig. 1). Histopathologic evaluation of a skin biopsy from a black tattoo on the left shoulder revealed a non-necrotizing granulomatous giant cell reaction with black tattoo pigment in the dermis (Fig. 2). The patient was referred to the rheumatologist, who could not find any evidence for other uveitis-associated diseases, such as sarcoidosis or spondyloarthritis, both on clinical and serological or imaging findings; C-reactive protein, comprehensive chemistry panel, HLA-B27, serum ACE/ANA/ANCA, chest X-ray and X-rays of spine and sacroiliac joints all showed results interpreted as normal. The patient was treated with high-dose oral prednisone and with methotrexate that led to the simultaneous improvement of the ocular inflammation and complete resolution of the skin lesions.

9a



**Figure 1.** In (a) initial presentation of the skin reaction; papulonodular reaction in all black tattoos. In (b) resolution of the skin lesions after treatment with high-dose oral prednisone and later methotrexate.



9a

**Figure 2.** Histopathologic evaluation of a skin biopsy from a black tattoo on the left shoulder revealed a non-necrotizing granulomatous giant cell reaction with black tattoo pigment in the dermis. Magnification 100x.

We describe a patient who presented with granulomatous inflammation of the tattooed skin and the onset of bilateral uveitis shortly thereafter. No additional evidence of sarcoidosis or other uveitis-associated diseases on examination, serological tests or imaging was found. Other studies found similar results.<sup>1-4</sup> The majority of those reports showed that inflammation of tattooed skin coincided with the onset of uveitis. However, few reports showed delayed ocular involvement, the same as in our case.<sup>2</sup>

Tattoo granulomas and uveitis, or tattoo-associated uveitis, are increasingly recognized phenomena, in which inflammation is limited to tattooed skin and the uveal tract. The underlying pathophysiology remains unclear, although several hypotheses have been described. First, it has been suggested that this condition represents a specific granulomatous-delayed type of hypersensitivity reaction to ink.<sup>2</sup> Moreover, the manufacturing of black tattoo ink is based on soot, which may contain toxic, mutagenic or carcinogenic compounds.<sup>5</sup> The injection of tattoo pigments into the skin results in a relatively large antigenic and/ or toxic load, initiating a local cutaneous response that in some way seems to be involved in the later development of ocular inflammation. Identification of the specific tattoo pigments that may trigger such a condition in susceptible individuals is therefore of interest. Secondly, another hypothesis suggested that chronic, mild antigenic stimulation from the tattoo in genetically predisposed individuals may lead to a systemic granulomatous reaction, consistent with sarcoidosis.<sup>6</sup> Many cases have been attributed to sarcoidosis because non-necrotizing granulomas are often seen on



skin biopsy.<sup>7</sup> However, pulmonary involvement is uncommon, and in many cases, no other clinical, serological or imaging features are found.

The first line of treatment includes topical corticosteroids and intraocular pressure lowering drops. However, in many cases systemic treatment with oral prednisone is needed, generally leading to simultaneous improvement of the ocular as well as the skin inflammation. To enable successful tapering of oral prednisone, initiation of immunosuppressive therapy, such as methotrexate or mycophenolate mofetil, has been described, just as in our case.<sup>1</sup>

Greater alertness among tattoo artists of the potential complications of certain inks may reduce the number of tattoo associated uveitis. For the dermatologist treating granulomatous inflammation of the tattooed skin, we would emphasize the importance of thorough systemic evaluation in all cases, including specific interest of the eyes, to identify this rare condition.

## REFERENCES

1. Ostheimer TA, Burkholder BM, Leung TG, Butler NJ, Dunn JP, Thorne JE. Tattoo-associated uveitis. *Am J Ophthalmol* 2014; 158: 637–643.
2. Rorsman H, Brehmer-Andersson E, Dahlquist I et al. Tattoo granuloma and uveitis. *Lancet* 1969; 2: 27–28.
3. Adam MK, Rahimy E, Dunn JP. Tattoo-associated uveitis. *JAMA Ophthalmol* 2015; 133: e144543.
4. Reddy AK, Shildkrot Y, Newman SA, Thorne JE. T-lymphocyte predominance and cellular atypia in tattoo-associated uveitis. *JAMA Ophthalmol* 2015; 133: 1356–1357.
5. Wenzel SM, Rittmann I, Landthaler M, Baumler W. Adverse reactions after tattooing: review of the literature and comparison to results of a survey. *Dermatology* 2013; 226: 138–147.
6. Sepehri M, Hutton Carlsen K, Serup J. Papulo-Nodular Reactions in Black Tattoos as Markers of Sarcoidosis: Study of 92 Tattoo Reactions from a Hospital Material. *Dermatology* 2016; 232: 679–686.
7. Anolik R, Mandal R, Franks AG Jr. Sarcoidal tattoo granuloma. *Dermatol Online J* 2010; 16: 19.



9b

**ALLERGIC REACTION TO RED  
COSMETIC LIP TATTOO TREATED  
WITH HYDROXYCHLOROQUINE.**

---

Ruben W. de Winter, Sebastiaan A.S. van der Bent, Marline van Esch,  
Albert Wolkerstofer, Thomas Rustemeyer.

*Dermatitis.* 2019;30(1):82-83.



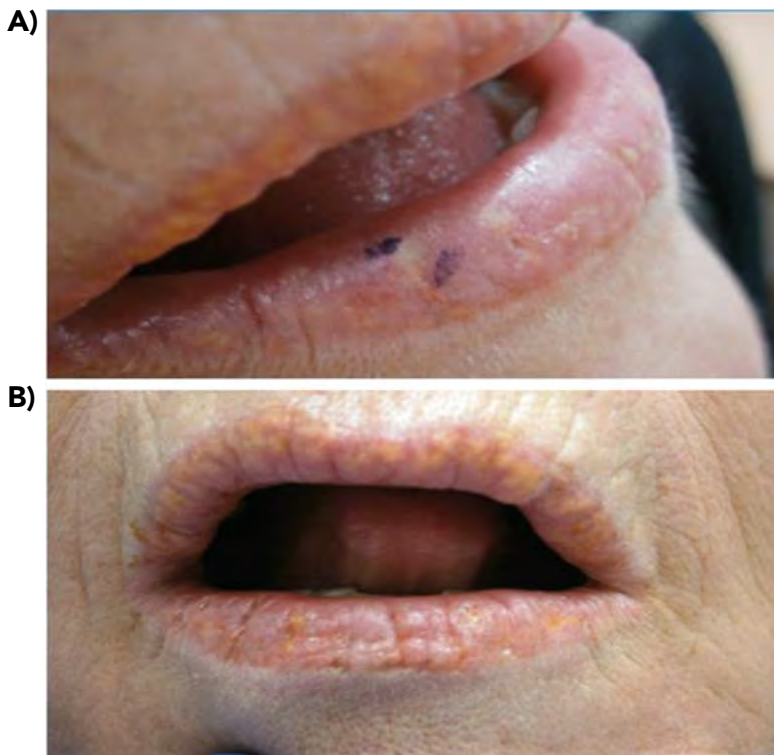
## PRECIS

We present a case of a patient with a cutaneous allergic reaction to red tattoo pigments in a cosmetic lip tattoo, successfully treated with hydroxychloroquine.

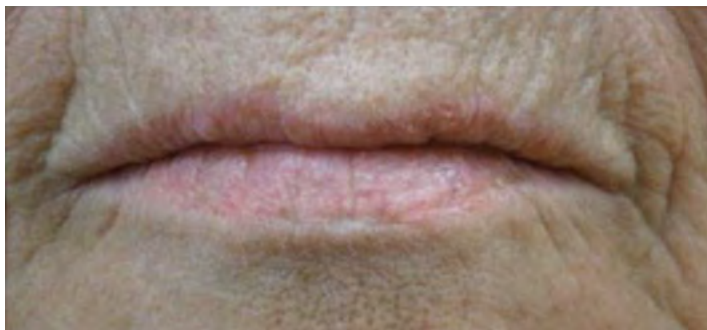
## DISCUSSION

A 73-year old woman visited the dermatology department with painful and itching skin lesions and a discoloration of the lips since 6 months. Two years earlier, both her entire lips were tattooed with red tattoo ink, for cosmetic reasons. Her eyebrows, tattooed with black tattoo ink simultaneously, were unproblematic. She had no further medical history. On physical examination we observed a slightly elevated plaque, confined to the red tattooed area, with yellow acneiform-like inclusions (Figure 1A & 1B). There was no lymphadenopathy. Skin biopsy showed a lymphohistiocytic, granulomatous inflammation surrounding the red tattoo pigment. Ziehl-Neelsen and PAS-D staining were negative. A chest X-ray and serum angiotensin converting enzyme were performed, which showed no abnormalities, especially no signs of sarcoidosis. The used tattoo ink could not be retrieved and patch testing was not performed. Based on the clinical and histological findings we diagnosed a delayed allergic reaction to the red tattoo pigment.

Because of potential cutaneous atrophy and limited penetration depth, therapy with topical or intralesional corticosteroids was not considered. Surgical procedures, such as dermatome shaving, were rejected because of potential scarring. Therefore, treatment with hydroxychloroquine 200 mg twice daily was initiated. After 3 months, we noticed a significant clinical improvement. After 18 months, there was a complete remission of all symptoms (Figure 2). The dosage of the hydroxychloroquine was slowly tapered and finally discontinued after 3 months without reoccurrence of symptoms till thus far. No adverse effects occurred.



**Figure 1A and 1B.** Pictures of the patient before treatment with hydroxychloroquine: showing slightly elevated plaque and yellowish papules on both the upper and lower lip, sharply confined to the tattooed area. The location of skin biopsy is marked.



**Figure 2.** Picture of the patient after 18 months of treatment with hydroxychloroquine: showing complete resolution of the reaction.



Cosmetic tattoos, when applied facially sometimes referred to as permanent makeup (PMU), are used to enhance facial appearance.<sup>1</sup> Frequently eyebrows, eyelids and lips are tattooed. Furthermore, these tattoos can camouflage lesions of skin diseases, such as alopecia of the eyebrows, hypopigmentation and vitiligo. Potential complications include infections, allergic reactions, autoimmune skin diseases, scarring, pigment migration and fanning/fading of the tattoo.<sup>1</sup>

In allergic reactions to tattoo pigments, red pigments are most frequently involved.<sup>2</sup> These reactions are chronic and can cause tenderness, pain, swelling and severe itch.<sup>3</sup> Onset of symptoms may vary, ranging from days to several years after tattooing.<sup>4</sup> These reactions can lead to a reduced quality of life.<sup>5</sup> Clinical patterns observed are: plaque elevation, ulcero-necrotic and hyperkeratotic pattern.<sup>6</sup> In allergic reactions to tattoo pigments occluded epidermal cysts can occur, as in our case. Patch testing was not performed because the tattoo ink was not retrievable and it would not have influenced treatment in our patient. In addition, patch testing results are generally negative and the diagnose is generally made clinically.<sup>7</sup>

During the past decennia, the composition of inks has changed. Inks are less likely than before to contain mainly inorganic pigments, such as mercury salt as a red pigment. Modern inks mostly contain organic pigments such as azo-pigments. In reactions to red tattoo ink, red azo pigments are the suspected sensitizers.

Treatment of allergic reactions to tattoo pigments is difficult because the pigments are permanently located in the dermis. In most cases, first line treatment consists of topical or intralesional corticosteroids. However, frequently a temporary effect is observed. Systemic corticosteroids can be used to treat more severe allergic reactions in red tattoos. Furthermore, allopurinol is reported as a successful treatment option for a granulomatous reaction to red tattoo pigment.<sup>8,9</sup> More permanent treatment options include dermatome shaving, surgical excision or treatment with carbon dioxide laser.<sup>6</sup> Until now, little is known about the optimal treatment modality in allergic reactions to tattoo pigments located facially. In some cases, spontaneous resolution of the lesions is reported. Because of physical complaints and cosmetic reasons, treatment is desired. In this case, hydroxychloroquine was used, as it is reported to be a successful treatment in granulomatous skin reactions.<sup>10</sup> In addition, it was reported previously as an effective option in the treatment of a pseudolymphomatous reaction to a green pigment tattoo on the trunk.<sup>11</sup> To our knowledge, this is the first reported case of the successful treatment of a granulomatous allergic reaction to a red pigment cosmetic tattoo with hydroxychloroquine.

## PEARL

In granulomatous allergic tattoo reactions on the lips, hydroxychloroquine can be considered a promising treatment option.

## REFERENCES

1. De Cuyper C. Permanent makeup: indications and complications. *Clin Dermatol.* 2008;26(1):30–4.
2. van der Bent SAS, Wolkerstorfer A, Rustemeyer T. [Extended abstract Cutaneous Adverse Reactions to Tattoos]. *Ned Tijdschr Geneeskd. Netherlands;* 2016;160(0):A9808.
3. Kluger N. Cutaneous and systemic complications associated with tattooing. *Press Medicale [Internet]. Elsevier Masson SAS;* 2016;45(6):567–76. Available from: <http://dx.doi.org/10.1016/j.lpm.2016.02.016>
4. van der Bent SAS, Maijer KI, Rustemeyer T. Image Gallery: Hyperkeratotic hypersensitivity reaction to red pigment tattoo. *Br J Dermatol [Internet].* 2017;177(6):e350–e350. Available from: <http://doi.wiley.com/10.1111/bjd.16040>
5. Hutton Carlsen K, Serup J. Patients with tattoo reactions have reduced quality of life and suffer from itch Dermatology Life Quality Index and Itch Severity Score measurements. *Ski Res Technol.* 2015;21(1):101–7.
6. Serup J, Bäuml W. *Diagnosis and Therapy of Tattoo Complications.* vol. 52. 2017. 78–80 p.
7. Serup J, Hutton Carlsen K. Patch test study of 90 patients with tattoo reactions: Negative outcome of allergy patch test to baseline batteries and culprit inks suggests allergen(s) are generated in the skin through haptization. *Contact Dermatitis.* 2014;(4):255–63.
8. Martin JM, Revert A, Monteagudo C, et al. Granulomatous reactions to permanent cosmetic tattoos successfully treated with topical steroids and allopurinol. *J Cosmet Dermatol. England;* 2007 Dec;6(4):229–31.
9. Godinho MM, Aguinaga F, Grynszpan R, et al. Granulomatous reaction to red tattoo pigment treated with allopurinol. *J Cosmet Dermatol. England;* 2015 Sep;14(3):241–5.
10. Jones E, Callen JP. Hydroxychloroquine is effective therapy for control of cutaneous sarcoidal granulomas. *J Am Acad Dermatol. United States;* 1990 Sep;23(3 Pt 1):487–9.
11. Patrizi A, Raone B, Savoia F, et al. Tattoo-associated pseudolymphomatous reaction and its successful treatment with hydroxychloroquine. Vol. 89, *Acta dermato-venereologica. Sweden;* 2009. p. 327–8.



9c

**SPONTANEOUS RESOLUTION  
OF MULTIDRUG-RESISTANT  
MYCOBACTERIUM ABSCESSUS  
INFECTION IN TATTOO**

---

Ellen Oyen, Karen I. Maijer, Sebastiaan A.S. van der Bent, Jan M. Prins,  
Saskia Janssen, Saskia Kuipers, Henry J.C. De Vries

*Journal of the European Academy of Dermatology and Venereology. 2020 Dec 8*



A 56-year-old, otherwise healthy, man was referred to the Academic Tattoo Clinic Amsterdam because of pain and itch in a multicoloured tattoo on his right arm since 1-month. Two weeks before the start of the complaints the tattoo had been placed on Bali, Indonesia. The patient had no fever or other physical complaints. Physical examination revealed multiple erythematous papules and pustules, especially in the black and white coloured parts of the tattoo (Fig. 1). The red, orange and green parts of the tattoo were not affected. He had no axillary or cervical lymphadenopathy. Histopathology of a skin biopsy in the black part of the tattoo showed a purulent granulomatous inflammation. Auramine stain of the punch biopsy showed acid-fast rods. Chest X-Ray showed no abnormalities, serum C-reactive protein (CRP) and erythrocyte sedimentation rate (ESR) were not elevated. Culture of another biopsy of the affected skin was positive for *Mycobacterium abscessus*. Cutaneous *Mycobacterium abscessus* infection after tattooing was diagnosed. Treatment options were limited, as *in-vitro* resistance was shown for ciprofloxacin and moxifloxacin, clarithromycin, co-trimoxazole, doxycycline, imipenem, and linezolid. Tigecyclin MIC was 2 mg/liter, clofazimine MIC was 2 mg/liter. The strain tested susceptible to amikacin, and intermediate susceptible to ceftioxin using Sensititre RAPMYCO (ThermoFischer Scientific, Waltham, MA, USA). The patient was planned for admission to the hospital, to start treatment with oral clarithromycin and intravenous amikacin and ceftioxin. However, in the meantime, the patient reported significant improvement of symptoms. He experienced less pain, itch and the skin manifestations abated. Therefore, antibiotic treatment was put on hold and a watchful waiting policy implemented. After 1,5 months, total clearance of the symptoms and skin manifestation was observed (Fig. 2). Follow-up 8 months later showed no clinical signs of recurrence of the infection.

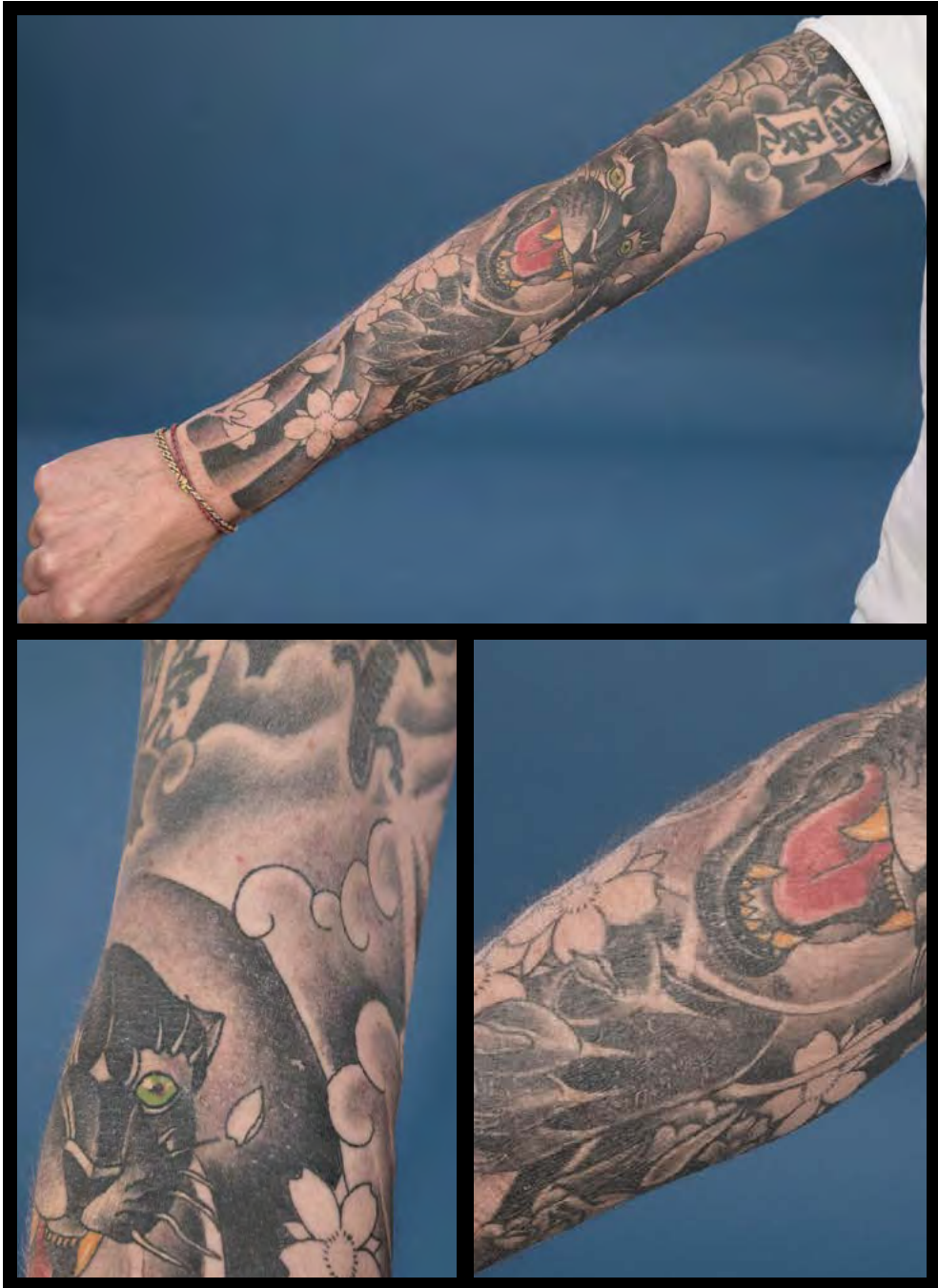Tattoos are currently one of the most popular forms of body art worldwide. Despite its popularity, complications such as infections, allergic reaction, auto-immune skin disease and scarring can occur.<sup>1</sup> Although bacterial tattoo infections such as *Staphylococcus aureus* induced impetigo occur frequently, they are generally mild, superficial and self-limiting. Other reported pathogens inducing tattoo infections include herpes simplex virus, *Streptococcus pyogenes* and *Pseudomonas aeruginosa*. Mycobacterial infection located in a tattoo is rare. However, *Mycobacterium chelonae*, *Mycobacterium abscessus subspecies massiliense* and *Mycobacterium fortuitum* infections have been reported.<sup>2,3</sup> *Mycobacterium abscessus*, a multidrug-resistant, rapidly growing non-tuberculous species consisting of *Mycobacterium abscessus subspecies abscessus* and *subspecies bolletii* with inducible macrolide resistance via the *erm(41)* gene, and the macrolide-susceptible *Mycobacterium abscessus subspecies massiliense*, has rarely been reported in tattoos before.<sup>4,6</sup> Reliable data are lacking but the prevalence of *Mycobacterium abscessus* infections seems to be increasing.<sup>5</sup> Transmission occurs through contaminated tattoo ink or water used in the tattooing process, and lack of hygiene of the tattoo artist or the client. In our opinion, most likely the black tattoo ink or water used during tattooing was contaminated. Unfortunately, the ink could not be retrieved and the tattoo artist could not be reached.

9c



**Figure 1.** Picture of the patient's right arm showing multiple erythematous and erythematous squamous papules and pustules: cutaneous infection with *Mycobacterium abscessus*.





**Figure 2.** Picture of the patient's right arm showing spontaneous clearance 1,5 months later in follow-up.

Different regimens of various durations have been tried for *Mycobacterium abscessus* cutaneous infections.<sup>4,7</sup> However, spontaneous remission of tattoo infection has not been reported in the literature yet. Our patient had no comorbidities and was immunocompetent at the time of being infected, which probably has contributed to an adequate immune response resulting in clearance of the infection. The toxicity of the intended treatment, the cutaneous limitation of disease and patient's motivation has driven the decision to implement a watchful waiting policy.

This case demonstrates spontaneous resolution of a *Mycobacterium abscessus* infection in a tattoo of a 56-year old patient. Clinicians should be aware of the possibility of a mycobacterial infection if persistent pustules or erythematous papules are observed in a tattoo. Since treatment of these mycobacterial skin infections is difficult because of antibiotic resistance patterns, hygienic standards and regulations for tattoo artists are important. Finally, watchful waiting can be considered in immunocompetent patients who show clinical improvement and no signs of disseminated disease.

## REFERENCES

1. van der Bent SAS, de Winter RW, Wolkerstorfer A, Rustemeyer T. Red tattoo reactions, a prospective cohort on clinical aspects. *J Eur Acad Dermatol Venereol*. 2019.
2. Velez L, Harb J, Anuszewski S, Wesson S. Cutaneous *Mycobacterium massiliense* infection from tattooing: a common yet under-reported and persistent epidemic hazard for dermatologists. *BMJ Case Rep*. 2018;2018.
3. Philips RC, Hunter-Ellul LA, Martin JE, Wilkerson MG. *Mycobacterium fortuitum* infection arising in a new tattoo. *Dermatol Online J*. 2014;20(6).
4. Kerkemeyer KL, Darby JD, Green J. *Mycobacterium abscessus* infection of a new tattoo in an Australian traveller returning from Bali, Indonesia. *J Travel Med*. 2020.
5. Falsey RR, Kinzer MH, Hurst S, Kalus A, Pottinger PS, Duchin JS, et al. Cutaneous inoculation of nontuberculous mycobacteria during professional tattooing: a case series and epidemiologic study. *Clin Infect Dis*. 2013;57(6):e143-7.
6. Griffin I, Schmitz A, Oliver C, Pritchard S, Zhang G, Rico E, et al. Outbreak of Tattoo-associated Nontuberculous Mycobacterial Skin Infections. *Clin Infect Dis*. 2019;69(6):949-55. Leto Barone AA, Grzelak MJ, Frost C et al. Atypical Mycobacterial Infections After Plastic Surgery Procedures Abroad: A Multidisciplinary Algorithm for Diagnosis and Treatment. *Annals of plastic surgery*. 2020;84(3):257-62.

10

# GENERAL DISCUSSION

---

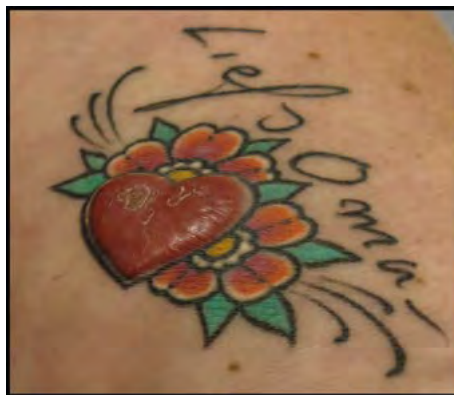
Sebastiaan A.S. van der Bent



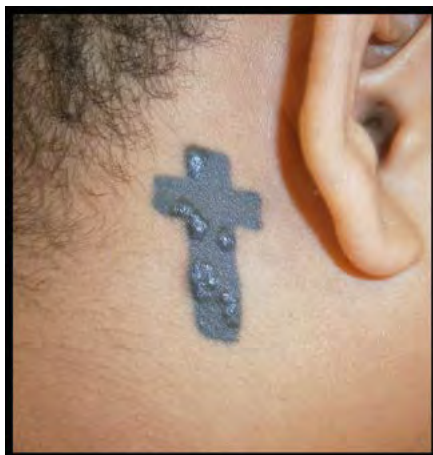Tattoos are a popular and growing form of body art. In contrast, the scientific literature comprises only few studies regarding tattoo complications and mainly consists of case-reports and case-series. This might be ascribed to the wide dispersion of these patients among healthcare workers: for the same medical tattoo associated problem, patients are referred to different healthcare professionals: general practitioners, dermatologists, internists, general surgeons, plastic surgeons, municipal health services, skin therapists etc. This makes it difficult for an individual researcher to perform large studies. This was one of the reasons to found the Academic Tattoo Clinic Amsterdam on January 13th of 2017.<sup>1,2</sup> It was done in the footsteps of the Tattoo Clinic in Bispjerg, Denmark, founded in 2009 and followed by a specialized tattoo consultation in France in 2017.<sup>3</sup> By this means, patients with tattoo complications can be referred to a highly specialised department, aiming at an efficient way to combine high quality dermatological care and research.

As we have experienced in our Tattoo Clinic and as previously reported, the majority of patients with tattoo complications visiting a dermatologist, presents with two types of reactions: firstly, the most common chronic tattoo complication, an allergic tattoo reaction to red pigment. In a large study of 493 tattoo complications, allergic reactions accounted for 37% of all tattoo complications and were predominantly associated with red pigments (85%) and typically presented with a plaque type elevation (figure 1).<sup>4</sup> In our clinic, these red allergic tattoo reactions accounted for 53% of all tattoo complications (unpublished data).

Secondly, chronic inflammatory non-allergic reactions to black tattoo account for a significant part of all tattoo complications, previously reported to account for 14.3% of all tattoo complications.<sup>4</sup> The clinical presentations typically include papules and nodules in the black tattooed skin, and are therefore sometimes named papulo-nodular black tattoo reactions (figure 2).<sup>5</sup> In our clinic, these reactions accounted for around 17% of all patients with tattoo complications (unpublished data), the second largest group after red tattoo reactions.



**Figure 1.** A typical 'plaque like' allergic red tattoo reaction on the left forearm.



**Figure 2.** A typical 'papulo-nodular' chronic inflammatory non-allergic black tattoo reaction, right retro auricular.

In total, these two reactions accounted for the vast majority of tattoo complications (70%) in our clinic. Notably, black, followed by red are the most frequently used tattoo colours. For these reasons, these two complications will be discussed extensively and separately regarding clinical aspects, diagnostics, pathomechanisms and treatment options.

## 10

## RED TATTOO REACTIONS

### Clinical aspects of red tattoo reactions

Red tattoo reactions play a major role in the field of tattoo complications as they are the most frequent chronic tattoo reactions and cause persistent symptoms resulting in a lowered quality of life.<sup>6</sup> However, until today, the exact pathomechanisms of red tattoo reactions remain unknown. It is thought to be a delayed allergic reaction, yet the clinical differential diagnoses include a phototoxic or irritant reaction, cutaneous sarcoidosis and localized lichen planus. Although, as reported in **chapter 2**, several clinical aspects indicate an allergic reaction: confined to exclusively the red tattooed skin, the substantial time span between tattooing and onset of symptoms and concomitant occurrence of red tattoo reactions in older red tattoos. On the other hand, there are several clinical aspects which might not directly correlate with an allergic reaction. For example, in patients with a contact dermatitis to p-phenylenediamine (PPD), the severity of the reactions increases with repetitive exposure to the allergen by stimulation of memory and effector T cells. In severe cases, this may lead to angio-oedema, generalized reactions or even blistering and ulceration.<sup>7</sup> However, in red tattoo reaction this rarely occurs and ulceration is reported in only 5% in our study. This is remarkably, since the allergen (tattoo ink) is permanently present in the dermis. However, this continuous type of exposure in tattoos as opposed to



intermittent exposure may well be responsible for a very different type of clinical course. This immunological process of continuous exposure with damping excessive reactions is called “hardening” and has been well documented in construction workers sensitized to chromium in cement.<sup>8</sup> Furthermore, as reported in **chapter 2**, various red tattoo ink brands were used in the studied 101 red tattoo reactions. This could indicate: i) all the reported brands contain the identical pigment or its breakdown products or additive; ii) multiple allergens are involved or; iii) these reactions are not allergic in nature at all. Also, the suggested role of sun exposure in forming the causative allergen is remarkable. In the studied cases, tattoos were located on sun exposed areas in 83% and worsening of symptoms was reported by patients in 32% after sun exposure. The latter was defined as unprotected exposure of the tattoo in the outdoor sun for a non-specified period of time. However, this definition is also applicable for phototoxic and other light-induced reactions. Furthermore, light-induced reactions are also frequently reported in black and blue tattoos.<sup>9</sup> On the other hand, a phototoxic reaction seems unlikely because its general occurrence is just minutes after sun exposure. This is in contrast to what patients with red tattoo reactions reported to us in practice: worsening of symptoms occurring hours to days after sun-exposure. Furthermore, cross-reactive red tattoo reactions would not fit in the diagnosis of a phototoxic reaction. For example, itch in a patient with a recent red tattoo simultaneously occurring with itch in an 8-year-old red tattoo without any symptoms in the past, would not fit in the diagnosis of a phototoxic reaction. The other two autoimmune skin dermatoses mentioned in the differential diagnosis include lichen planus and sarcoidosis. However, it is very unlikely that these dermatoses would Köbnerize only in one specific colour in a multi-coloured tattoo. Nevertheless, cases of cutaneous sarcoidosis restricted to one colour have been reported.<sup>10,11</sup> An irritant reaction in a tattoo is also unlikely, since one would expect a direct, instead of a delayed, reaction. Furthermore, as in phototoxic reactions, cross-reactive red tattoo reactions, would be theoretically inexplicable.

### **Diagnostics and pathomechanism in red tattoo reactions**

Although the diagnosis of a red tattoo reaction can frequently be made clinically, diagnostics such as histopathology can be used to exclude other diagnosis such as sarcoidosis, lichen planus, psoriasis or a mycobacterial tattoo infection. Other diagnostics such as patch testing can be used to confirm the diagnosis of an allergy and specify the culprit allergen. In this way, it is known what tattoo ink not to use for further tattooing, for example in medical tattoos. These diagnostics and other analytical methods such as the reconstructed human skin model can also be used to gain more knowledge about the aetiology of red tattoo reactions. These will be discussed further on. Other recent studied diagnostical and analytical methods in human material concerning tattoos will not be discussed, such as Raman spectroscopy, micro ( $\mu$ ) and nano ( $v$ ) scale X-ray fluorescence ( $\mu/v$ -XRF), matrix-assisted laser desorption/ionization tandem or laser ablation-inductively

coupled plasma-mass spectrometry (MALDI-MS/MS or LA-ICP-MS) and synchrotron-based Fourier transform infrared ( $\mu$ -FTIR) spectroscopy.<sup>12-15</sup>

## 1) Histopathology and pathomechanism

In the past literature, red tattoo reactions are frequently described and categorized by their histological pattern, despite their similar clinical presentation. For example 'lichenoid red tattoo reaction', 'pseudolymphomatous reaction on the red pigmented areas of a tattoo' or 'granulomatous tattoo reaction confined to red pigment'.<sup>16-18</sup> This may cause confusion, as a clearly defined diagnosis is frequently missing. On the other hand, the number of terms describes the great variety in histological patterns; lichenoid, granulomatous, spongiotic and pseudolymphomatous are all reported.

Thus far, only few and small histological studies have been performed regarding allergic tattoo reactions.<sup>19-21</sup> As we discussed in **chapter 5**, histiocytes were the predominant inflammatory cells in 74.3% of our study population. Interface involvement was observed in 64.8%, which is line with a previous study.<sup>21</sup> The most frequent inflammatory pattern was a predominant histiocytic reaction with interface dermatitis. Remarkably, eosinophils were observed in only 8.1%. The abundance of histiocytes could be explained by their role as major component of the innate immune system. The combination of a histiocytic pattern and interface dermatitis may contribute to find the right diagnosis and indicates a specific immunologically mediated red tattoo reaction. Because of the inflammation patterns and cells found in this study, it is suggested that these reactions are most likely a combination of a subtype IVa and IVc delayed hypersensitivity reaction.<sup>22</sup> However, it remains remarkable that the variety in histological patterns has no influence on severity of symptoms, choice of treatment or prognosis.

## 2) Patch testing, possible allergens and skin sensitization potential

As previously mentioned, red tattoo reactions are thought to be delayed allergic reactions, however the culprit allergens remain unknown. Tattoo inks generally contain a mixture of insoluble pigments and soluble ingredients such as solvents, thickeners and preservatives. Pigments dominate the analytical focus because of its high concentrations in tattoo inks, in contrast to the much lower concentrations of preservatives and impurities.<sup>23</sup> Furthermore, potential sensitizers such as preservatives, solvents and impurities are more biodegradable and therefore will be removed quickly from the tattooed skin after the tattooing procedure. Because red tattoo reactions are chronic, these soluble substances are therefore less likely to cause the reactions.

In the past, mercury was thought to be the causative allergen, since several cases were published with positive patch test results.<sup>18,24</sup> However, in the last decades, inorganic metallic pigments, such as mercury, chromium and cadmium salts, have largely been replaced by organic pigments like azo pigments, quinacridones, and phthalocyanines.<sup>25</sup> Therefore, in red tattoo reactions, mercury sulfide (cinnabar) is no longer thought to be

the causative allergen. However, in some inks, these substances are still detected in small concentrations, be it as chromophores (appendix), shading additives or contaminants.<sup>25</sup>

In the last decade, one large study was performed regarding patch testing in patients with allergic tattoo reactions.<sup>26</sup> In this study, baseline allergens, disperse dyes/textile allergens and a selection of tattoo ink stock products were tested in 90 patients with an allergic tattoo reaction. Additionally, in 25 cases the culprit inks could be obtained from the tattooist and these patients were tested with their respective ink. Remarkably, the majority of all the patch tests were negative. Even in the 25 patients who were tested with their individual culprit ink, only 2 patients (8%) reacted. Again, this raises the question whether these red tattoo reactions are truly allergic in nature. However, there are several possible explanations for the negative patch test results: i) the potential allergens may insufficiently penetrate the skin; ii) the potential allergens may have been tested in incorrect concentrations; iii) the incorrect ink may have been tested; iv) the declaration of content on the label may deviate from its actual content (proven by analysis in several studies) or; v) the causative allergen may be a breakdown product from the original pigments and therefore not present in the tattoo ink bottle. The latter supports the current hypothesis that the allergen is formed in the dermis through a slow process of haptization.<sup>26</sup> Tattoo pigments may undergo enzymatic processes in the dermis. This may be induced by light, as light is known to cause photochemical cleavage of tattoo pigments *in vitro*. Also, cases of a tattoo allergies induced by the use of Q-switched laser are reported.<sup>27,28</sup> These degradation products may form the allergen that induces a T cell-mediated reaction. This hypothesis is further supported by the observation that tattoos fade over time, hence the concentration of the original pigment decreases. Also, clinically, this could clarify the great variation in time of onset of symptoms. For these reasons, to enhance the sensitivity of future patch testing, new patch test series should be developed and studied, including all ingredients and breakdown products of the pigments in the tattoo inks.

In a recent study, chemical analysis of human skin biopsies from chronic allergic reactions in red tattoos was performed to identify pigments and metals.<sup>15</sup> In this study, mainly azo pigments were found, including Pigment Red 22 (35%), Pigment Red 210 (24%) and Pigment Red 170 (12%). These pigments are all naphthol AS azo pigments. Naphthol AS is an organic compound with the gross formula  $C_{10}H_6(OH)C(O)NHC_6H_5$  and was found in more than 55% of the biopsies in this study. As previously mentioned, these pigments are known to be cleaved upon sunlight exposure or laser irradiation. These data suggest that naphthol AS are potential causative allergens as the majority of the found pigments are capable of sensitization. However, it still cannot be concluded what the precise azo pigment-related fragment is that is causing the allergy.

Further allergic research should be performed for further determination. Of course, it would be interesting to inject tattoo dyes into the skin to perform intradermal allergy testing, however this might result in permanent skin discolouration (i.e. tattoo) and reactions and therefore will not be appreciated by the patients. Therefore, patch testing

and photo-patchtesting should be performed, with all the ingredients and breakdown products of the pigments in the tattoo inks. In this way, the aetiology and causative allergens in these red tattoo reactions can be revealed. As a result, these pigments could be banned in the tattoo industry and other suggestions for alternative red tattoo pigments could be made. Hopefully, in this way, tattooing will cause less complications.

Next to patch testing, *in vitro* sensitization tests could be used to identify potential dermal sensitizers in tattoo inks. In **chapter 6**, the sensitization potential of 5 tattoo inks was investigated by using interleukin-18 as a biomarker in a reconstructed human skin model. One of the tested inks was Eternal Ink Light Red, which according to the label contains Pigment Red 170, showing significant secretion of IL-18 in comparison to other tattoo inks. This confirms the pigment as a skin sensitizer and is in line with the study of Schreiber et al. where the specific pigment was found in the affected skin of patients with allergic red tattoo reaction. Using a reconstructed human skin (RHS) model would be a promising method for screening of sensitizing potential of tattoo inks. However, this is the first study where an advanced *in vitro* RHS model is used to study tattoo ink-induced complications. Other limitations include the 24 hours of exposure of the substances and no exposure of UV-light is used. Also, although IL-18 secretion is crucial in the adverse outcome pathway (AOP) the process of skin sensitization and developing an allergic reaction, it includes only one of the several other events such as dendritic cell activation and T cell priming. Further validation of the RHS model for its unique type of application should be performed, by testing an extended panel of chemicals which exposed via the dermal side rather than stratum corneum to precisely set the threshold in the future.

## 10

### Treatment of red tattoo reactions

Treatment of allergic tattoo reactions is difficult, as tattoo pigments are permanently stored in the dermis. Few studies about the treatment of allergic red tattoo reactions are published.<sup>29-31</sup> Objective and validated outcomes, such as discussed in **chapter 7**, should be used to assess the effectivity of the treatment. Topical or intralesional corticosteroids are indicated as a first line treatment and their therapeutic potential should not be underestimated. As is illustrated in figure 3, a hyperkeratotic allergic red tattoo reaction was intermittently treated with betamethasone 0.05% with salicylic acid 3% ointment pulse therapy. After 3-4 months, the excessive hyperkeratosis has disappeared and the typical 'pseudo-epidermal cysts' became visible.<sup>32,33</sup> Therapy was continued and complete resolution was obtained in 8 months without any adverse events. In general, local corticosteroids have to be used for a longer period and sometimes additional occlusion is required.

If topical corticosteroids fail, intralesional corticosteroids can be used.<sup>34</sup> As previously mentioned, the effect of these therapies is generally temporary and therefore prolonged treatment is necessary. The duration of these treatments depends on the treatment efficacy, adverse events and the patients preference to keep the original tattoo design.



**Figure 3.** Hyperkeratotic red tattoo reaction on the right lower leg, intermittently treated with betamethasone 0.05% with salicylic acid 3% ointment pulse therapy, photographs taken after 0 (left), 3 (middle) and 8 (right) months.

Namely, if the symptoms persist or the patients prefer long lasting treatment results, other treatments that remove the allergen should be considered such as dermatome shaving, ablative CO<sub>2</sub> laser and surgical excision. In **chapter 8**, a retrospective study shows that CO<sub>2</sub> laser ablation improves itching, burning and impact on daily life in tattoo allergy. An advantage of the CO<sub>2</sub> laser is the possibility of treating more accurately in a horizontal and vertical plane which spares the surrounding tissue and results in a better preservation of the original tattoo design. Furthermore, in contrary to dermatome shaving, ablative laser therapy is not a bloody procedure due to surrounding coagulation. The main downside of this treatment, as in dermatome shaving and surgical excision, is the formation of scars. Thus far, no safe and scarless treatment is available for removing the ink in red tattoo reactions.

To avoid scarring, one could consider using the fractional CO<sub>2</sub> laser or a Q-switched laser. The Q-switched laser is the current gold standard for removal of uncomplicated tattoos.<sup>35</sup> However, the Q-switched lasers can cause a generalized allergic reaction by breakdown of tattoo pigments being released into systemic circulation, as shown in several case reports.<sup>36-39</sup> This reaction can be eczematous, indicating a type IV allergic reaction, or urticarial, indicating a type I reaction. On the other hand, these laser-induced reactions are thought to be temporary and generally well treatable. Moreover, the Q-switched 532 nm Nd:YAG laser is the only type of laser that affects red ink, and at this specific wavelength, the penetration into tissue is limited to 0.5 mm. Consequently, this type of laser can reach only the superficial part of the tattoo. And finally, Q-switched lasers do not remove the tattoo ink but result in redistribution of the ink particles in the body. Nevertheless,

to my knowledge, the Q-switched laser is used frequently by several dermatologists in the Netherlands and abroad in the treatment of allergic tattoo reaction. One could discuss the effectiveness of the Q-switched laser as its penetration depth is about 0.5-1 mm and, an allergic tattoo reaction may show abundant dermal thickening by far more than 1 mm. On the other hand, as observed in our study with the fractional laser, not all the pigments have to be removed for improvement of the symptoms. Another disadvantage of the Q-switched lasers is that it may require more than ten treatments.

Other therapeutic options could be considered in patients with specific tattoo locations or contra-indications for the previously discussed treatments. These alternative treatments include allopurinol, cyclosporine and hydroxychloroquine. As described in **chapter 9 B**, complete resolution was achieved in a patient with an allergic tattoo reaction on her lips. However, after cessation of these systemic medications, the symptoms may reoccur. In our patient, the symptoms did not reoccur. A possible explanation for this could be that, during the 18 months treatment with hydroxychloroquine, natural breakdown of the causative pigment took place, leading to tissue concentrations below the threshold for a symptomatic allergy. Further research has to be performed for assessment of safe and permanent treatment options. Ablative CO<sub>2</sub> laser is an effective and efficient treatment but can cause scars. The Q-switched lasers may have the best aesthetic outcome, but generalized skin reactions can occur and multiple treatments are needed. Further research, adopting a split lesion randomized comparative study using objective and validated outcomes, should be used to assess and compare the different therapeutic options.

## BLACK TATTOO REACTIONS

### Clinical aspects of black tattoo reactions

Black is by far the most frequently used tattoo colour. The risk of developing chronic symptoms in black tattoos is rather low. Though, due to the large population tattooed with black tattoo ink, patients with chronic reactions in black tattoos are frequently observed in the dermatology clinic.<sup>4</sup> The diagnosed dermatoses generally not include psoriasis, infections or phototoxic reactions but rather present a still largely unknown inflammatory dermatologic entity. The clinical presentation generally includes papules, nodules or larger plaques, confined to the black tattooed skin (**chapter 4**).<sup>5</sup> Remarkably, other parts of the similar tattoo, made with the same tattoo ink, may appear completely normal. Also, generally the itch or pain is mild and evident erythema or secondary infection is rare. These clinical aspects differ significantly from previously discussed red tattoo reactions. On the other hand, the onset of symptoms after tattoo placement differs widely and can go up many years, as in red tattoo reactions.

It is known for many years that reactions in black tattoos can be a manifestation of (systemic) sarcoidosis and can even be the presenting symptom.<sup>40</sup> Another peculiar, rarely reported, medical entity is 'tattoo associated uveitis': i.e. a granulomatous cutaneous reaction restricted to tattoos with the simultaneous development of recurrent uveitis, all

in the absence of systemic sarcoidosis. Although the skin and eyes are the most common extrapulmonary organs to be involved in sarcoidosis, it remains unclear whether this is a specific clinical subtype of sarcoidosis or a separate disease entity.<sup>41</sup>

A review of tattoos and sarcoidosis found an association between the male gender and sarcoidosis, and black and red tattoos.<sup>11</sup> Thus far, only one large clinical study on black tattoo reactions has been performed.<sup>5</sup> This study shows that papulo-nodular black tattoo reactions are an important marker for sarcoidosis: of the total of 72 patients, sarcoidosis was diagnosed in 19 patients (26%). Of these 19 patients, 8 (11%) had cutaneous sarcoidosis and 11 (15%) systemic sarcoidosis. Moreover, in this study a new clinical clue was suggested: the 'rush phenomenon'. This is the clinical observation when an affected papulo-nodular tattoo reaction precedes the development of similar reactions in other black tattoos. The authors suggest that this is in favour of sarcoidosis. More studies should be performed to evaluate this phenomenon and whether it is possible to differentiate between a chronic black tattoo reaction by sarcoidosis or non-sarcoidosis on the basis of clinic aspects. Furthermore, in the concerning study, the majority of these patients were described as having non-sarcoidosis black tattoo reactions. However, these patients may still develop sarcoidosis later in life. Therefore, clinical studies with a longer follow-up are essential.

### **Diagnosics and pathomechanism in black tattoo reactions**

As described above, a significant part of inflammatory black tattoo reactions is caused by sarcoidosis and therefore sarcoidosis has to be excluded. For the screening on sarcoidosis a skin biopsy, chest X-ray can be performed and blood testing for, angiotensin-converting enzyme (ACE) and soluble interleukin 2 receptor (sIL-2R). Other diagnostic procedures include chest computed tomography (CT) and magnetic resonance imaging (MRI) and, depending on possible other organs involved, specific diagnostic procedures are needed.<sup>42</sup> If the clinical suspicion of sarcoidosis is high, referral to a pulmonologist is recommended.

A possible explanation for the occurrence of sarcoidosis in tattoos is the Köbner phenomenon: the trauma of the tattooing procedure may trigger the autoimmune disease. This may even occur many years after the tattoo was placed. However, most patients with auto-immune diseases do not experience symptoms in their tattoo, as is described in sarcoidosis patients in **chapter 3**. This is also shown in other studies regarding tattoos and other auto-immune diseases such as psoriasis and lupus erythematosus.<sup>43,44</sup> The pathomechanisms of sarcoidosis are unknown but it is believed to be an abnormal inflammatory immune response to an antigen or immunological trigger. Likely, genetic and environmental factors, such as tattoo pigments, play a role.<sup>45</sup>

On the other hand, the majority of patients with chronic inflammatory black tattoo reactions has no sarcoidosis.<sup>5</sup> The aetiology of these non-sarcoidosis reactions remains unknown and differentiation between an allergic reaction, foreign body reaction or cutaneous sarcoidosis is difficult. Therefore, in my opinion, these black tattoo reactions are one of the most interesting tattoo reactions.

## 1) Histology

No large studies have been performed focusing on the histopathology of chronic black tattoo reactions. In case reports, mainly granulomatous reactions have been described and to a lesser extent, pseudolymphomatous and lichenoid reactions.<sup>46-50</sup> In the study cited earlier, histopathology included sarcoid granuloma, 'inflammation' and granulomatous inflammation.<sup>5</sup> However, they did not define the term 'inflammation' or elaborate on the type of inflammation. Furthermore, cutaneous sarcoidosis was diagnosed in 11% of these black tattoo reactions. In my opinion and according to current practice and guidelines, it is debatable whether the diagnosis sarcoidosis can be made solely on tattoo related dermatological clinical findings and a skin biopsy. Namely, the histopathology of a foreign body reaction and cutaneous sarcoidosis can be similar.<sup>51-53</sup> In addition, a tattoo pigment is a foreign body per definition. Furthermore, for the diagnosis of sarcoidosis, the presence of multiorgan involvement enhances the diagnostic certainty.<sup>54</sup> This study also suggests that the non-sarcoidosis reactions are by aetiology foreign body reactions. It suggested that these reactions are elicited by the tendency of carbon black nanoparticles to agglomerate, forming large clusters of black pigments resulting in a foreign body reactions, although this is still dependent on individual predisposition.<sup>5</sup> While pigment agglomeration was found in patients with sarcoidosis and tattoo reactions, no comparison was made with uncomplicated black tattoos in healthy individuals.<sup>55</sup> Furthermore, the formation of pigment agglomeration might be due to the inflammation itself, caused by sarcoidosis.

Further histological studies should be performed for assessment of the inflammatory patterns and cells involved in chronic black tattoo reactions. Preferably, this histopathology should be combined with a long-term follow-up with repetitive screening on sarcoidosis. It would be interesting to see whether the presence of non-sarcoidal granulomas in a skin biopsy can be found in patients with systemic sarcoidosis presenting with symptomatic nodules in the tattooed skin.

## 2) Allergy

An allergic pathomechanism is thought to be unlikely, as the main pigment used in black tattoo ink, 'Carbon black', is inert. Carbon itself has never been reported as an active allergen in the medical literature.<sup>5</sup> Furthermore, except one case-report, no positive patch test results have been reported in the literature in patients with chronic black tattoo reactions.<sup>56</sup> Some authors even suggest that allergies to black tattoo pigments are non-existing. On the other hand, no large patch test studies have been performed in patients with these reactions, so evidence is lacking. An immunological mechanism is likely to play a role. This is supported by an interesting case report describing a patient with a recurrent papulo-nodular black tattoo reactions that disappeared within a weeks after surgical removal of metal osteosynthesis implants from his spine.<sup>57</sup> Patch testing with extracts of these implants and titanium on the tattooed skin evoked flare-up of the symptoms.



Nickel, chromium, titanium and aluminum were detected in both the tattooed skin biopsy and the implants. These findings suggest that the pigments could play a role in the pathogenesis of black tattoo reactions. Moreover, cases of cutaneous sarcoidosis restricted to one tattoo colour are reported and therefore raise the question whether these reactions are aetiologically a sarcoidal hypersensitivity reaction to a specific tattoo pigment or ink additive, or the first manifestation of a systemic disease.

Till today, the exact pathomechanism of chronic inflammatory black tattoo reactions is unknown. It may be a delayed type hypersensitivity reaction or a manifestation of sarcoidosis. One could even further debate whether there is a difference between sarcoidosis and a granulomatous hypersensitivity reaction to a specific agent. On the other hand, there might be distinct diagnoses involved in these chronic black tattoo reactions.

In my opinion, it is indeed possible that black tattoo pigments can elicit an inflammatory response. However, the inflammatory response may depend on the individual (genetic) predisposition. Different environmental factors may be involved, such as targeted therapies and immune checkpoint inhibitors used for advanced cancers. These drugs are known to elicit black tattoo reactions.<sup>58</sup> These new therapeutic modalities are expected to be used more frequently in the future and as a consequence, adverse reactions in tattoos might be seen more often. In addition, these immunomodulatory therapies might also shed light on underlying immunological pathomechanisms.

### Treatment of black tattoo reactions

Except for a few case-reports, no studies have been published regarding the treatment of chronic black tattoo reactions.<sup>48,59</sup> If sarcoidosis is diagnosed, corticosteroids, hydroxychloroquine and methotrexate can be considered as treatment options.<sup>60,61</sup> However, adequate controlled trials of these therapies are lacking.<sup>62</sup> In tattoo-associated uveitis, the advantage of systemic treatment is that multiple affected organs can be treated with one drug. Methotrexate, as discussed in **chapter 9 A**, is a possible treatment option. Other reported treatment options include systemic corticosteroids and mycophenolate mofetil.<sup>41</sup>

Concerning the non-sarcoidosis black tattoo reactions, it is stated that these reactions are generally self-limiting and topical or intralesional corticosteroids are generally sufficient.<sup>63</sup> This is also our experience in the Academic Tattoo Clinic Amsterdam. The self-limiting aspect supports the theory that pigment concentration might be involved in these reactions.

Based on our experience and the weak evidence from clinical studies, local corticosteroids are the first therapy of choice in both the sarcoidosis and non-sarcoidosis chronic black tattoo reactions. In case of insufficient effect, the second choice is intralesional corticosteroids, followed by hydroxychloroquine and methotrexate. However, the choice depends on the severity and extent of the skin lesions, the symptoms and the involvement of other organs.

## Conclusion

Tattoos are a popular form of body art with a great variety of potential complications. To date, little research has been performed. Allergic red tattoo reactions and chronic inflammatory black tattoo reactions are the most frequent chronic tattoo complications. Red tattoo reactions are likely to be a delayed type allergic reaction and UV exposure seems to play a role. The culprit allergens are still unknown, but azo pigments may be involved. Further research should be performed by patch testing and photo-patchtesting with the potential causative allergens, including all ingredients and breakdown products of the pigments in the tattoo inks. Treatment options with permanent effect include CO<sub>2</sub> laser ablation, dermatome shaving and surgical excision. Other treatment options should be studied for less invasive and safe removal with less downtime and better cosmetic outcomes. Chronic black tattoo reactions are an important marker for sarcoidosis, and therefore screening should be performed. However, the majority of these chronic inflammatory black tattoo reactions are non-sarcoidosis and their exact etiology remains unknown.

In my opinion, despite all potential complications mentioned in this thesis, we should not be fundamentally opposed to tattoos. In fact, tattoos can be beneficial and even have several medical purposes as well. Furthermore, in my experience, tattoos can bring 'joy' in the life of people and may contribute to the self-esteem and body image.<sup>64-66</sup> For the future, the development of a 'hypoallergenic' tattoo ink would be interesting and potential beneficial to all involved in the tattoo industry. In any case, clients always should be well aware and advised about possible risks of getting a tattoo.

## REFERENCES

1. NOS. Speciale tattoopoli voor pijnlijke probleemtatoeages. Hilversum, Netherlands: NOS; 2017 Jan 13. Retrieved from <https://nos.nl/artikel/2152776-speciale-tattoopoli-voor-pijnlijke-probleemtatoeages.html>. Accessed January 13, 2018.
2. Boersma EA. Tattoopoli gaat pijnlijke tatoeages verwijderen. Amsterdam, Netherlands: De Volkskrant; 2017 Jan 13. Retrieved from <https://www.volkskrant.nl/nieuws-achtergrond/tattoopoli-gaat-pijnlijke-tatoeages-verwijderen~b4aa2c12/>. Accessed January 13, 2018.
3. Kluger N, Descamps V. Usefulness of a specialized « tattoo » consultation in a tertiary care hospital: a one-year experience. *J Eur Acad Dermatol Venereol*. 2019;33(4):e182-e183. doi:10.1111/jdv.15435
4. Serup J, Sepehri M, Hutton Carlsen K. Classification of Tattoo Complications in a Hospital Material of 493 Adverse Events. *Dermatology*. 2016;232(6):668-678. doi:10.1159/000452148
5. Sepehri M, Hutton Carlsen K, Serup J. Papulo-Nodular Reactions in Black Tattoos as Markers of Sarcoidosis: Study of 92 Tattoo Reactions from a Hospital Material. *Dermatology*. 2016;232(6):679-686. doi:10.1159/000453315
6. Carlsen KH, Serup J. Chronic tattoo reactions cause reduced quality of life equaling cumbersome skin diseases. *Curr Probl Dermatol*. 2015;48:71-75. doi:10.1159/000369644
7. Mukkanna KS, Stone NM, Ingram JR. Para-phenylenediamine allergy: current perspectives on diagnosis and management. *J Asthma Allergy*. 2017;10:9-15. Published 2017 Jan 18. doi:10.2147/JAA.S90265
8. Watkins SA, Maibach HI. The hardening phenomenon in irritant contact dermatitis: an interpretative update. *Contact Dermatitis*. 2009;60(3):123-130. doi:10.1111/j.1600-0536.2009.01507.x
9. Hutton Carlsen K, Serup J. Photosensitivity and photodynamic events in black, red and blue tattoos are common: A 'Beach Study'. *J Eur Acad Dermatol Venereol*. 2014;28(2):231-237. doi:10.1111/jdv.12093
10. Sowden JM, Cartwright PH, Smith AG, Hiley C, Slater DN. Sarcoidosis presenting with a granulomatous reaction confined to red tattoos. *Clin Exp Dermatol*. 1992;17(6):446-448. doi:10.1111/j.1365-2230.1992.tb00257.x
11. Kluger N. Sarcoidosis on tattoos: a review of the literature from 1939 to 2011. *Sarcoidosis Vasc Diffuse Lung Dis*. 2013;30(2):86-102. Published 2013 Aug 1.
12. van der Bent SAS, Berg T, Karst U, Sperling M, Rustemeyer T. Allergic reaction to a green tattoo with nickel as a possible allergen. *Contact Dermatitis*. 2019;81(1):64-66. doi:10.1111/cod.13226
13. Hutton Carlsen K, Køcks M, Sepehri M, Serup J. Allergic reactions in red tattoos: Raman spectroscopy for 'fingerprint' detection of chemical risk spectra in tattooed skin and culprit tattoo inks. *Skin Res Technol*. 2016;22(4):460-469. doi:10.1111/srt.12287
14. Schreiber I, Hesse B, Seim C, et al. Synchrotron-based  $\nu$ -XRF mapping and  $\mu$ -FTIR microscopy enable to look into the fate and effects of tattoo pigments in human skin. *Sci Rep*. 2017;7(1):11395. Published 2017 Sep 12. doi:10.1038/s41598-017-11721-z
15. Serup J, Hutton Carlsen K, Dommershausen N, et al. Identification of pigments related to allergic tattoo reactions in 104 human skin biopsies. *Contact Dermatitis*. 2020;82(2):73-82. doi:10.1111/cod.13423
16. Malki S, Onnis G, Lissia A, Montesu MA, Satta R. Cutaneous T pseudolymphoma on the red pigmented areas of a tattoo. *Int J Dermatol*. 2017;56(8):e172-e173. doi:10.1111/ijd.13659

17. Haber R, Farid S. Réaction granulomateuse confinée à l'encre rouge de tatouage [Granulomatous tattoo reaction confined to red pigment]. *Ann Dermatol Venereol*. 2016;143(1):79-80. doi:10.1016/j.annder.2015.09.001
18. Taaffe A, Knight AG, Marks R. Lichenoid tattoo hypersensitivity. *Br Med J*. 1978;1(6113):616-618. doi:10.1136/bmj.1.6113.616
19. Thum CK, Biswas A. Inflammatory complications related to tattooing: a histopathological approach based on pattern analysis. *Am J Dermatopathol*. 2015;37(1):54-66. doi:10.1097/DAD.0b013e3182974558
20. Shinohara MM, Nguyen J, Gardner J, Rosenbach M, Elenitsas R. The histopathologic spectrum of decorative tattoo complications. *J Cutan Pathol*. 2012;39(12):1110-1118. doi:10.1111/cup.12023
21. Høgsberg T, Thomsen BM, Serup J. Histopathology and immune histochemistry of red tattoo reactions. Interface dermatitis is the lead pathology, with increase in T-lymphocytes and Langerhans cells suggesting an allergic pathomechanism. *Skin Res Technol*. 2015;21(4):449-458. doi:10.1111/srt.12213
22. Uzzaman A, Cho SH. Chapter 28: Classification of hypersensitivity reactions. *Allergy Asthma Proc*. 2012;33 Suppl 1:96-99. doi:10.2500/aap.2012.33.3561
23. 23. Nederlandse Voedsel- en Warenautoriteit. Resultaten onderzoek van kleurstoffen voor tatoeages en permanente make-up in de periode 2008-2013. Utrecht: NVWA; 2014, 16 p.
24. Bhardwaj SS, Brodell RT, Taylor JS. Red tattoo reactions. *Contact Dermatitis*. 2003;48(4):236-237. doi:10.1034/j.1600-0536.2003.00090.x
25. Laux P, Tralau T, Tentschert J, et al. A medical-toxicological view of tattooing. *Lancet*. 2016;387(10016):395-402. doi:10.1016/S0140-6736(15)60215-X
26. Serup J, Hutton Carlsen K. Patch test study of 90 patients with tattoo reactions: negative outcome of allergy patch test to baseline batteries and culprit inks suggests allergen(s) are generated in the skin through haptenization. *Contact Dermatitis*. 2014;71(5):255-263. doi:10.1111/cod.12271
27. Engel E, Spannberger A, Vasold R, König B, Landthaler M, Bäuml W. Photochemical cleavage of a tattoo pigment by UVB radiation or natural sunlight. *J Dtsch Dermatol Ges*. 2007;5(7):583-589. doi:10.1111/j.1610-0387.2007.06333.x
28. Ashinoff R, Levine VJ, Soter NA. Allergic reactions to tattoo pigment after laser treatment. *Dermatol Surg*. 1995;21(4):291-294. doi:10.1111/j.1524-4725.1995.tb00175.x
29. Sepehri M, Jørgensen B, Serup J. Introduction of dermatome shaving as first line treatment of chronic tattoo reactions. *J Dermatolog Treat*. 2015;26(5):451-455. doi:10.3109/09546634.2014.999021
30. Millán-Cayetano JF, Alegre-Sánchez A, Boixeda P. Treatment of red tattoo reaction using CO2 laser. *Lasers Med Sci*. 2018;33(5):1171-1173. doi:10.1007/s10103-017-2229-3
31. Forbat E, Al-Niaimi F. Patterns of Reactions to Red Pigment Tattoo and Treatment Methods. *Dermatol Ther (Heidelb)*. 2016;6(1):13-23. doi:10.1007/s13555-016-0104-y
32. van der Bent SAS, Maijer KI, Rustemeyer T. Image Gallery: Hyperkeratotic hypersensitivity reaction to red pigment tattoo. *Br J Dermatol*. 2017;177(6):e350. doi:10.1111/bjd.16040
33. Kluger N. Eruptive milia and acneiform hyperkeratosis with comedones (pseudo-epidermal cysts) within tattoos. *Ann Dermatol Venereol*. 2019;146(12):801-806. doi:10.1016/j.annder.2019.01.026
34. Wambier CG, Cappel MA, Wambier SPF. Treatment of reaction to red tattoo ink with intralesional triamcinolone. *An Bras Dermatol*. 2017;92(5):748-750. doi:10.1590/abd1806-4841.20176678

35. Prinz BM, Vavricka SR, Graf P, Burg G, Dummer R. Efficacy of laser treatment of tattoos using lasers emitting wavelengths of 532 nm, 755 nm and 1064 nm. *Br J Dermatol.* 2004;150(2):245-251. doi:10.1111/j.1365-2133.2004.05658.x
36. England RW, Vogel P, Hagan L. Immediate cutaneous hypersensitivity after treatment of tattoo with Nd:YAG laser: a case report and review of the literature. *Ann Allergy Asthma Immunol.* 2002;89(2):215-217. doi:10.1016/S1081-1206(10)61942-4
37. Harper J, Losch AE, Otto SG, Zirwas M, Delaney KO, Wakelin JK 3rd. New insight into the pathophysiology of tattoo reactions following laser tattoo removal. *Plast Reconstr Surg.* 2010;126(6):313e-314e. doi:10.1097/PRS.0b013e3181f63fde
38. Ashinoff R, Levine VJ, Soter NA. Allergic reactions to tattoo pigment after laser treatment. *Dermatol Surg.* 1995;21(4):291-294. doi:10.1111/j.1524-4725.1995.tb00175.x
39. Yorulmaz A, Onan DT, Artuz F, Gunes R. A case of generalized allergic contact dermatitis after laser tattoo removal. *Cutan Ocul Toxicol.* 2015;34(3):234-236. doi:10.3109/15569527.2014.933972
40. van der Bent SA, Wolkerstorfer A, Rustemeyer T. Huidafwijkingen bij tatoeages [Extended abstract Cutaneous Adverse Reactions to Tattoos]. *Ned Tijdschr Geneeskd.* 2016;160:A9808.
41. Kluger N. Tattoo-associated uveitis with or without systemic sarcoidosis: a comparative review of the literature. *J Eur Acad Dermatol Venereol.* 2018;32(11):1852-1861. doi:10.1111/jdv.15070
42. Soto-Gomez N, Peters JI, Nambiar AM. Diagnosis and Management of Sarcoidosis. *Am Fam Physician.* 2016;93(10):840-848.
43. Grodner C, Beauchet A, Fougousse AC, et al. Tattoo complications in treated and non-treated psoriatic patients. *J Eur Acad Dermatol Venereol.* 2020;34(4):888-896. doi:10.1111/jdv.15975
44. Sabio JM, Betolaza S, Vargas-Hitos JA. Characteristics and safety of tattoos in patients with systemic lupus erythematosus. *Lupus.* 2019;28(10):1250-1254. doi:10.1177/0961203319867395
45. Ali MM, Atwan AA, Gonzalez ML. Cutaneous sarcoidosis: updates in the pathogenesis. *J Eur Acad Dermatol Venereol.* 2010;24(7):747-755. doi:10.1111/j.1468-3083.2009.03517.x
46. Brown H, Hannaford R. Recurrent lichenoid reaction to black tattoo ink: A case report and brief review of the literature. *Australas J Dermatol.* 2020;61(2):e238-e240. doi:10.1111/ajd.13231
47. Campolmi P, Bassi A, Bonan P, et al. Cutaneous pseudolymphoma localized to black tattoo. *J Am Acad Dermatol.* 2011;65(5):e155-e157. doi:10.1016/j.jaad.2011.06.039
48. Morales-Callaghan AM Jr, Aguilar-Bernier M Jr, Martínez-García G, Miranda-Romero A. Sarcoid granuloma on black tattoo. *J Am Acad Dermatol.* 2006;55(5 Suppl):S71-S73. doi:10.1016/j.jaad.2005.12.022
49. Valbuena MC, Franco VE, Sánchez L, Jiménez HD. Sarcoidal granulomatous reaction due to tattoos: report of two cases. *An Bras Dermatol.* 2017;92(5 Suppl 1):138-141. doi:10.1590/abd1806-4841.20175860
50. Ghorpade A. Inoculation sarcoidal granulomas on blue-black tattoos in seven ladies. *J Eur Acad Dermatol Venereol.* 2006;20(3):349-350. doi:10.1111/j.1468-3083.2006.01410.x
51. Schewach-Millet M, Ziv R, Trau H, Zwas ST, Ronnen M, Rubinstein I. Sarcoidosis versus foreign-body granulomas. *Int J Dermatol.* 1987;26(9):582-585. doi:10.1111/j.1365-4362.1987.tb02310.x
52. Tukenmez Demirci G, Mansur AT, Yıldız S, Güleç AT. Is it a sarcoidal foreign-body granuloma or a cutaneous sarcoidosis on a permanent eyebrow make-up?. *J Cosmet Laser Ther.* 2016;18(1):50-52. doi:10.3109/14764172.2015.1052516

53. Scofield-Kaplan SM, Patel SY, Mueller A, et al. Foreign-Body Granulomata Caused by Injected Permanent Filler Masquerading as Cutaneous Sarcoidosis. *Ophthalmic Plast Reconstr Surg*. 2019;35(3):e82-e84. doi:10.1097/IOP.0000000000001385
54. Bickett AN, Lower EE, Baughman RP. Sarcoidosis Diagnostic Score: A Systematic Evaluation to Enhance the Diagnosis of Sarcoidosis. *Chest*. 2018;154(5):1052-1060. doi:10.1016/j.chest.2018.05.003
55. Hutton Carlsen K, Larsen G, Serup J. Tattoo pigment agglomerates measured in skin biopsies by computerised light microscopy: Study of 161 patients with adverse reactions in black and red tattoos. *Skin Res Technol*. 2020;26(2):284-291. doi:10.1111/srt.12798
56. Gallo R, Parodi A, Cozzani E, Guarrera M. Allergic reaction to India ink in a black tattoo. *Contact Dermatitis*. 1998;38(6):346-347. doi:10.1111/j.1600-0536.1998.tb05779.x
57. de Cuyper C, Lodewick E, Schreiver I, et al. Are metals involved in tattoo-related hypersensitivity reactions? A case report. *Contact Dermatitis*. 2017;77(6):397-405. doi:10.1111/cod.12862
58. Kluger N. Tattoo Reactions Associated with Targeted Therapies and Immune Checkpoint Inhibitors for Advanced Cancers: A Brief Review. *Dermatology*. 2019;235(6):522-524. doi:10.1159/000501590
59. Sheu J, Saavedra AP, Mostaghimi A. Rapid response of tattoo-associated cutaneous sarcoidosis to minocycline: case report and review of the literature. *Dermatol Online J*. 2014;20(8):13030/qt6dd1m2j9. Published 2014 Aug 17.
60. Haimovic A, Sanchez M, Judson MA, Prystowsky S. Sarcoidosis: a comprehensive review and update for the dermatologist: part I. Cutaneous disease. *J Am Acad Dermatol*. 2012;66(5):699.e1-718. doi:10.1016/j.jaad.2011.11.965
61. Doherty CB, Rosen T. Evidence-based therapy for cutaneous sarcoidosis. *Drugs*. 2008;68(10):1361-1383. doi:10.2165/00003495-200868100-00003
62. Baughman RP, Lower EE. Evidence-based therapy for cutaneous sarcoidosis. *Clin Dermatol*. 2007;25(3):334-340. doi:10.1016/j.clindermatol.2007.03.011
63. Serup J, Carlsen KH, Sepehri M. Tattoo complaints and complications: diagnosis and clinical spectrum. *Curr Probl Dermatol*. 2015;48:48-60. doi:10.1159/000369645
64. Kluger N. Tattooing and psoriasis: demographics, motivations and attitudes, complications, and impact on body image in a series of 90 Finnish patients. *Acta Dermatovenerol Alp Pannonica Adriat*. 2017;26(2):29-32. doi:10.15570/actaapa.2017.9
65. Braverman S: One in Five U.S. Adults Now Has a Tattoo. New York, NY, Harris Polls, 2012. Retrieved from <http://www.harrisinteractive.com/NewsRoom/HarrisPolls/tabid/447/mid/1508/articleId/970/ctl/ReadCustom%20Default/Default.aspx>. Accessed April 22, 2014.
66. Swami V. Marked for life? A prospective study of tattoos on appearance anxiety and dissatisfaction, perceptions of uniqueness, and self-esteem. *Body Image*. 2011;8(3):237-244. doi:10.1016/j.bodyim.2011.04.005



11



**GENERAL SUMMARY /  
ALGEMENE SAMENVATTING**

---

Sebastiaan A.S. van der Bent



## GENERAL SUMMARY

Tattoos are a popular form of body art. In Europa and the USA, the prevalence varies between 10-20%. The number and sort of usages of tattoos are rising. Despite its popularity, little is known about tattoo complications and its clinical aspects, pathomechanism and treatment.

In the **General introduction** an overview of cutaneous tattoo complications is presented. These complications can be divided in infectious, inflammatory, neoplastic and miscellaneous complications. Infections are mainly superficial and of bacterial origin. Inflammatory complications include allergic reactions and auto-immune skin diseases. Of all allergic reactions to tattoo pigments, red pigments are most frequently involved. Auto-immune skin disease that may be related to tattoos include psoriasis, lichen planus, sarcoidosis, vitiligo and lupus erythematosus. They may be locally triggered by the procedure of tattooing which is referred to as Köbner phenomenon. Not rarely, the affected tattooed skin is the first manifestation of a systemic autoimmune disease. Although tattoo ink is thought to contain potential carcinogenic substances, the association between tattoos and skin cancer is interpreted to be coincidental because of the low reported number of cases. Miscellaneous complications include misapplication, pigment changes, blow-outs, neurosensory reactions, scars and keloids.

Of all chronic tattoo reactions, red tattoo reactions are the most frequent. **Chapter 2** includes the clinical aspects of red tattoo reactions: chronic itch, pain or swelling affecting one or more tattoos and restricted to red or nuances of red. In a prospective study in the Academic Tattoo Clinic Amsterdam, clinical information of 101 patients with a red tattoo reaction was collected during four years. This study revealed that the mean time of onset of symptoms is 12 months. Clinically, a plaque type reaction was observed in 92%, a hyperkeratotic reaction in 3% and an ulcero-necrotic pattern in 5%. A high percentage of reactions was located on sun-exposed areas; the distal extremities and face accounted for 83%. Symptoms worsened after sun exposure in 32%. Although the exact pathomechanism is unknown, these clinical aspects indicate a delayed allergic reaction and a potential role for sunlight in forming the allergen.

In **Chapter 3** the prevalence of tattoos and associated adverse events in sarcoidosis patients is studied. The demand of tattoos is high, also under patients with auto-immune diseases. However, little is known about the percentage of adverse events in sarcoidosis patients as no previous studies have been performed. A multicentre cross-sectional study was conducted, using an online survey amongst sarcoidosis patients. Of all eligible patients who completely filled in the questionnaire, 22.2% reported to have a tattoo. Of these, 21.3% experienced adverse events, mainly in black tattoos (90%). Papules and nodules were reported in 70%. For reasons still unknown, darker skin types were associated with the risk of adverse events in tattoos.

**Chapter 4** concerns a case-series of 5 patients with a granulomatous reaction to permanent makeup of the eyebrows. The clinical presentation includes elevated and

yellowish plaques in the cosmetic tattoo. Remarkably, these patients had 2 to 15 sessions of tattooing before developing adverse reactions. Time of onset of symptoms varied between 1 and 18 months. Differentiation between sarcoidosis, a foreign body reaction or allergic tattoo reaction is difficult, as all these diagnoses can histologically present as a granulomatous inflammation. In 1 of the 5 patients, systemic sarcoidosis was diagnosed. In this case, the affected tattoo was the first manifestation of the disease. Furthermore, we suggest that an association may exist between the number of tattoo sessions and the risk for developing a granulomatous reaction.

In **Chapter 5** we studied the histopathology of red tattoo reactions. Skin biopsies of 74 patients with allergic red tattoo reactions were reviewed, focusing on inflammation patterns, inflammatory cells and pigments. Thus far, no large studies concerning the histopathology of tattoo complications have been performed. The results showed that histiocytes were the predominant inflammatory cells in 74.3% of the patients. Remarkably, eosinophils were observed in only 8.1%. In 37.9%, the most frequent inflammation pattern, a predominant histiocytic reaction with interface dermatitis was detected. Interface involvement itself was observed in 64.8%. Moreover, in six cases (8.1%), we were unable to detect any tattoo pigment particles microscopically, which is remarkable since the biopsies were taken from macroscopically affected tattooed skin. Furthermore, an association was found between the severity of inflammation and the depth of the pigment. This could be explained by a stronger inflammatory stimulus if pigment depositions are more abundant throughout the skin. The large presence of histiocytes could be explained by their role as a major component of the innate immune system. Because the red pigment particles were abundant throughout all the skin layers, including the basal layer of the epidermis, they may have contributed to the interface dermatitis by formation of neo-antigens. The combination of a histiocytic pattern and interface dermatitis may point to a specific immunologically mediated red tattoo reaction. Because of the clinical aspects of red tattoo reactions and the inflammatory pattern and cells found in this study, we suggest these reactions are most likely a combination of a subtype IVa and IVc delayed hypersensitivity reaction.

**Chapter 6** concerns the comparison of the skin sensitization potential of 3 red and 2 black tattoo inks using interleukin-18 as a biomarker in a reconstructed human skin model. In this in vitro study, 3 red and 2 black tattoo inks, 1 additive (Hamamelis virginiana extract) and 1 irritant control (lactic acid) were tested. The culture medium of RHS (reconstructed epidermis on a fibroblast-populated collagen hydrogel) was supplemented with test substances in a dose dependent manner for 24 hours, after which cytotoxicity and skin sensitization potential were assessed by histology (thiazolyl blue tetrazolium bromide assay) and IL-18 secretion (enzyme-linked immunosorbent assay) respectively. Results: 4 of 5 tattoo inks showed cytotoxicity. Notably, 1 red ink and 1 black ink were able to cause an inflammatory response, indicated by substantial release of IL-18. We concluded that the model showed that 4 tattoo inks were cytotoxic (and therefore have irritant properties) and 2 were able to cause an inflammatory IL-18 mediated response, indicating that an

individual may develop allergic contact dermatitis when exposed to these tattoo inks, as they contain contact sensitizers.

In **Chapter 7** a feasibility study is performed for using 3D optical imaging in the quantification of cutaneous allergic tattoo reactions. User independent measures of cutaneous allergic reactions can help in management and treatment evaluation of cutaneous allergic reactions. The skin surface of allergic tattoo reactions was imaged using an optical 3D scanner, measuring elevation, volume and area compared to a reference surface. The clinical feasibility of the method was tested in 83 lesions in 17 patients. The measurement error was quantified using an arm model and a lesion phantom, showing good measurement for lesions with diameters above 2.5 mm and areas smaller than 600 mm<sup>2</sup>. Significant changes in elevation and volume of lesions on arms and legs could be measured over time. Therefore, we conclude that quantification of lesions of allergic reactions using a 3D optical scanner is feasible and a promising technique for the evaluation and quantification of the effectiveness of therapies.

**Chapter 8** concerns a retrospective study of ablative CO<sub>2</sub> laser therapy of allergic red tattoo reactions. Treatment of allergic tattoo reactions is difficult, as tattoo pigments are permanently stored in all layers of the dermis. Topical or intralesional corticosteroids are indicated as first line treatment but results are frequently insufficient or temporary. Thus far, the continuous wave CO<sub>2</sub> laser was only studied in six patients with allergic tattoo reactions. Even less is known about the efficacy of the fractional CO<sub>2</sub> laser.

The study was performed by using clinical chart information and a 25-item questionnaire concerning symptoms and satisfaction. Sixteen patients were treated, either by full surface ablation or fractional ablation. Of these, 15 patients (94%) achieved improvement of their symptoms. The vast majority of the full surface ablation group was satisfied or very satisfied with the outcome of laser treatment (75%) and would recommend this therapy to others (87.5%). Eleven of 16 patients reported scars, however the level of inconvenience was low. The advantages of the CO<sub>2</sub> laser include the permanent removal of the pigments, the possibility of treating more accurately along the borders of the tattoo and the coagulation which limits the bleeding during the procedure. We concluded that CO<sub>2</sub> laser therapy can improve the symptoms of allergic tattoo reactions when topical or intralesional corticosteroids are insufficiently effective. Furthermore, other reported treatment options are discussed such as conventional full-thickness excision, dermatome shaving, allopurinol, hydroxychloroquine and Q-switched laser.

**Chapter 9** defines the treatment and course of tattoo complications in specific cases. **Chapter 9 A** describes the treatment of a cutaneous allergic reaction to a red pigment tattoo on the lips of a 73-year old patient. The symptoms occurred 1.5 years after her entire lips were tattooed. Treatment with hydroxychloroquine 200 mg twice daily was initiated, showing clear improvement within 3 months. After 18 months, there was a complete remission of all symptoms. **Chapter 9 B** shows the successful treatment of a granulomatous tattoo reaction with associated uveitis in a 52-year-old woman. The clinical presentation included swelling and itch located in all of her 11 black tattoos with the onset of bilateral

recurrent uveitis shortly thereafter. No evidence was found for other uveitis-associated diseases such as sarcoidosis. The patient was treated with high-dose oral prednisone and with methotrexate that led to the simultaneous improvement of the ocular inflammation and complete resolution of the skin lesions. Tattoo-associated uveitis is a frequently unrecognized entity and its underlying pathophysiology remains unclear. However, it has been suggested to be related to a specific granulomatous-delayed hypersensitivity reaction to tattoo ink or a specific presentation of sarcoidosis. **Chapter 9 C** concerns a patient with spontaneous resolution of a multidrug-resistant *Mycobacterium abscessus* infection in a tattoo of a 56-year-old immunocompetent man. The presentation included multiple erythematous papules and pustules, especially in the black and white tattooed skin. Culture of a skin biopsy showed *Mycobacterium abscessus*. Resistance was shown for ciprofloxacin, clarithromycin, co-trimoxazole, doxycycline, imipenem, linezolid and moxifloxacin. Remarkable, the patient reported spontaneous clinical improvement. After 1.5 months, total clearance of the symptoms and skin manifestation were observed. Follow-up 8 months later showed no clinical signs of recurrence of the infection.

## ALGEMENE SAMENVATTING

De wetenschappelijke inhoud van dit proefschrift is tot stand gekomen tijdens de opleiding tot dermatoloog in het Amsterdam UMC. De klinische basis voor al de wetenschappelijke werkzaamheden vormden de Tattoo poli die is opgericht op 13 januari 2017 in het VU medisch centrum. Naast de reguliere patiëntenzorg konden hierdoor de klinische complicaties van tatoeages in kaart worden gebracht en onderzoek worden verricht naar pathomechanismen en therapiemodaliteiten, wat uiteindelijk heeft geleid tot nationale en internationale samenwerkingen.

Tatoeages zijn een populaire vorm van body art. De prevalentiecijfers in Europa en de VS variëren tussen de 10 en 20%. Het aantal getatoeëerden en de soorten toepassingen van tatoeages zijn stijgende. Ondanks de populariteit is weinig bekend over de mogelijke complicaties van tatoeages, diens klinische aspecten, pathomechanisme en behandeling.

In de **algemene introductie** wordt een overzicht gegeven van de dermatologische complicaties bij tatoeages. Deze kunnen worden onderverdeeld in infectieus, inflammatoir, neoplasma en overige complicaties. De gerapporteerde infecties zijn voornamelijk oppervlakkig en van bacteriële origine. Tot de inflammatoire reacties behoren de allergieën en auto-immuun huidziekten. Van alle allergische reacties op tattoo pigmenten, zijn de rode pigmenten het meest frequent betrokken. Tot de auto-immuun huidziekten behoren onder andere psoriasis, lichen planus, sarcoïdose en lupus erythematoses. Deze kunnen een lokale opvlamming geven in de getatoeëerde huid door de procedure van het tatoeëren; dit kan verklaard worden door het Köbner fenomeen. Niet zelden is de aangedane getatoeëerde huid de eerste manifestatie van een (systemische) auto-immuun ziekte. Tatoeage-inkt bevat mogelijk potentieel carcinogene stoffen, echter wordt de relatie tussen huidkanker en tatoeages als co-incidenteel beschouwd gezien het lage aantal gepubliceerde casus. Tot de overige complicaties horen onder andere misapplicatie, pigment veranderingen, blow-out, neurosensorische reacties, littekens en keloïd.

Van alle chronische tattoo reacties zijn allergische reacties op rode tattoo pigmenten het meest voorkomend. In **hoofdstuk 2** worden de klinische aspecten van deze reacties besproken: chronische jeuk, pijn of zwelling in één of meer tatoeages, scherp begrensd rondom de rood (of diens spectrum) getatoeëerde huid. In een 4 jaar durend prospectief onderzoek van de Tattoo poli werden 101 patiënten met een allergische reactie op rode tatoeage geïnccludeerd. De studie toonde aan dat de tijd voor het ontstaan van klachten gemiddeld 12 maanden is. De klinische presentatie was in 92% een 'plaque-type' reactie, in 3% een hyperkeratotische en in 5% ulceratief. Een hoog percentage van de reacties werd gevonden op zon geëxposeerde lichaamsdelen: distale extremiteiten en het gelaat (83%). Verergering van de klachten na zonexpositie werd door 32% van de patiënten gerapporteerd. Het exacte pathomechanisme van deze reacties is vooralsnog onbekend, maar deze klinische bevindingen duiden op een vertraagde allergische reacties en dat zonlicht mogelijk een rol speelt in de vorming van allergenen.

In **hoofdstuk 3** onderzochten we de prevalentie van tatoeages en geassocieerde klachten in patiënten met sarcoïdose. Tegenwoordig is er een grote vraag naar tatoeages, ook onder patiënten met een auto-immuun ziekte. Er is echter weinig bekend hierover aangezien er hierna geen eerdere onderzoeken zijn verricht. Een multicenter cross-sectioneel onderzoek werd verricht met gebruik van een online vragenlijst onder patiënten met sarcoïdose. Van alle geschikte patiënten die de vragenlijst compleet hadden ingevuld, had 22.2% een tatoeage. Hiervan gaven 21.3% aan klachten te hebben ervaren van de tattoo. In 90% van de gevallen betrof het een zwarte tatoeage en in 70% werden papels en nodi gerapporteerd. Een donkere huid was geassocieerd met klachten in de tatoeages, de reden hiervoor is nog onbekend.

**Hoofdstuk 4** omvat een case-serie van 5 patiënten met een granulomateuze reactie op permanente make-up van de wenkbrauwen. Klinisch uitte deze reactie zich in elevatie en gelige plaques in de cosmetische tatoeages. Het aantal tattoo sessies varieerde van 2 tot 15 voordat de klachten zich ontwikkelden. De tijd voor ontstaan van de klachten varieerde tussen de 1 en 18 maanden. Diagnostische differentiatie tussen sarcoïdose, vreemdlichaamreactie en allergische tattoo reactie is lastig, aangezien al deze diagnoses histologisch een granulomateuze reactie kunnen tonen. In één van de vijf patiënten werd systemische sarcoïdose gediagnosticeerd, hierbij was de tattoo de eerste manifestatie van de aandoening. We opperden dat er mogelijk een associatie bestaat tussen het aantal malen tatoeëren en het ontwikkelen van een granulomateuze tattoo reactie.

In **hoofdstuk 5** onderzochten we de histopathologie van allergische reacties op rode tatoeages. De huidbiopten van 74 patiënten werden geanalyseerd, gericht op het inflammatie patroon, cellen en pigmenten. Tot dusver zijn geen grote studies verricht naar de histopathologie bij tattoo complicaties. De resultaten toonden dat histiocyten de dominante inflammatoire cellen waren in 74.3%. Eosinofiele granulocyten werden geobserveerd in slechts 8.1%. Het meest voorkomende histologische inflammatie patroon (37.9%) was een histiocyten dominante inflammatie met een grensvlak ontsteking. Een grensvlakontsteking op zichzelf werd geobserveerd in 64.8%. In 6 casus (8.1%) werden microscopisch geen tattoo pigmenten waargenomen. Dit is opmerkelijk aangezien uit een macroscopisch aangedane getatoeëerde huid is gebiopteerd. Een associatie werd aangetoond tussen de diepte van de tattoo pigmenten en de ernst van de inflammatie. De grote aanwezigheid van histiocyten kan verklaard worden door diens grote rol in het aangeboren immuunsysteem. Aangezien rode pigmenten aanwezig waren in alle huidlagen, inclusief rondom de basale epidermis, is het mogelijk dat deze pigmenten hebben bijgedragen aan de vorming van een of meerdere neo-antigenen, resulterend in een grensvlakontsteking. De bijzondere combinatie van een dominant histiocytair inflammatie en een grensvlakontsteking duidt mogelijk op een specifiek immuun gemedieerde reactie op tattoo pigmenten. Op basis van de klinische aspecten van reacties op rode tatoeages en de gevonden inflammatie patronen en cellen in deze studie, operen we dat deze reacties mogelijk een combinatie zijn van een subtype IVa en IVc vertraagde overgevoelighedsreacties.



**Hoofdstuk 6** omvat de vergelijking van de potentie tot huidsensibilisatie van 3 rode en 2 zwarte tattoo inkten door middel van het gebruik van interleukine-18 als biomarker in een gereconstrueerd menselijk huidmodel. In deze in vitro studie werden getest: 3 rode en 2 zwarte tattoo inkten, 1 hulpstof (Hamamelis virginiana extract) en 1 controle irritativum (melkzuur). Het kweekmedium van RHS (gereconstrueerde epidermis met fibroblast-bevattende collageen hydrogel) werd dosisafhankelijk aangevuld met de testsubstanties in 24 uur. Hierna werden cytotoxiciteit en potentie tot huidsensibilisatie beoordeeld door middel van respectievelijk histologie (Thiazolyl Blue Tetrazolium Bromide-test) en IL-18 secretie (enzymgebonden immunosorbensbepaling).

Resultaten: 4 van de 5 tattoo inkten toonden cytotoxiciteit. Tevens toonde 1 rode en 1 zwarte tattoo inkt een inflammatoire respons, geduid op basis van substantieel secretie van IL-18. Op basis van de resultaten van dit model concludeerden we dat 4 tattoo inkten cytotoxisch zijn (en derhalve irritatieve eigenschappen hebben) en 2 inkten in staat waren om een inflammatoire IL-18 respons te produceren. Dit laatste wijst erop dat een individu een contactallergische reactie kan ontwikkelen na expositie aan een van deze tattoo inkten omdat deze contact-sensibilisatoren bevatten.

**Hoofdstuk 7** is een haalbaarheidsonderzoek voor het gebruik van 3D optische beeldvorming in de kwantificering van allergische huidreacties op tatoeages. Gebruikersonafhankelijke metingen van cutane allergische reacties kunnen helpen in diens beoordeling, management en evaluatie van behandeling. Het huidoppervlak van de allergische reacties werd in beeld gebracht door een optische 3D scanner waarbij de elevatie, volume en oppervlak werd vergeleken met een referentieoppervlak. De klinische haalbaarheid van deze methode werd getest in 83 laesies in 17 patiënten. De meetfout werd gekwantificeerd door middel van het gebruik van een arm- en fantoommodel. Dit toonde betrouwbare metingen voor laesies met een diameter boven de 2.5 mm en oppervlakten kleiner dan 600 mm<sup>2</sup>. Significante veranderingen in elevatie en volume van laesies van extremiteiten konden worden waargenomen. We concludeerden dat de kwantificatie van allergische huidreacties haalbaar is en tevens een veelbelovende methode voor de evaluatie en kwantificatie van diens behandelingen.

**Hoofdstuk 8** betreft een retrospectief onderzoek naar gebruik van de ablatieve CO<sub>2</sub> laser als behandeling van allergische reacties op rode tatoeages. De behandeling van deze reacties is lastig, aangezien de tattoo pigmenten permanent en tot diep in de dermis aanwezig zijn. Lokale en intralesionale corticosteroïden zijn de eerstelijnsbehandelingen, echter is hierbij het effect vaak tijdelijk of beperkt. Tot dusver was de full surface ablatieve laser, bij een allergische tattoo reactie, onderzocht in slechts 6 patiënten. In het onderzoek werd klinische informatie verkregen uit de status en tevens werd gebruik gemaakt van een 25-delige vragenlijst wat betreft symptomen en tevredenheid. In totaal werden 16 patiënten behandeld door middel van full surface of fractionele ablatieve CO<sub>2</sub> laser. Bij 15 patiënten (94%) werd verbetering van de symptomen waargenomen. Het merendeel van de patiënten die behandeld was met de full surface CO<sub>2</sub> laser was tevreden tot erg tevreden met het resultaat van de laser behandeling (75%) en zou deze behandeling aanbevelen

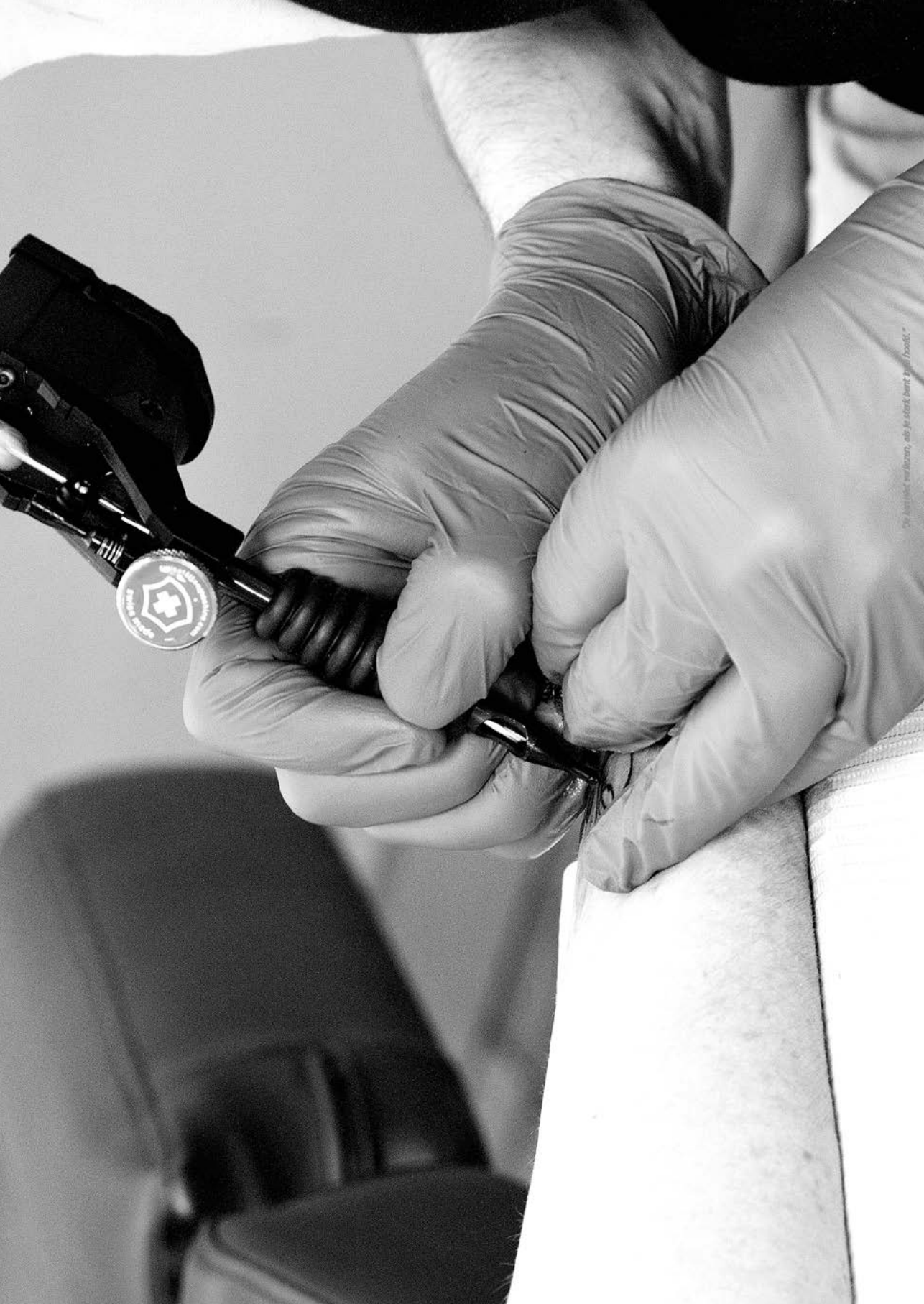aan anderen (87,5%). Bij 11 van de 16 patiënten werden littekens gerapporteerd, de mate van het hieruit voortvloeiende ongemak was echter laag. Voordelen van de CO<sub>2</sub> laser zijn dat het een permanent, accurate en een niet-bloederige behandeling betreft. We concludeerden dat de CO<sub>2</sub> laser verbetering kan geven in de klachten bij allergische tattoo reacties indien lokale corticosteroïden niet toereikend zijn. Tevens worden andere behandelingsmogelijkheden kort belicht in dit hoofdstuk: conventionele excisie, dermatome shaving, allopurinol, hydroxychloroquine en de Q-switched laser.

In **hoofdstuk 9** wordt de behandeling en beloop van verschillende tattoo complicaties in specifieke patiënten besproken. In **Hoofdstuk 9 A** wordt de behandeling beschreven van een 73-jarige patiënte met een contactallergische reactie op een rode tatoeage van haar lippen. De klachten ontstonden 1.5 jaar nadat patiënte haar gehele lippen had laten tatoeëren. Behandeling met hydroxychloroquine 200 mg 2dd werd gestart waarna de klachten verbeterden in 3 maanden. Na 18 maanden werd een complete remissie van de huidafwijkingen waargenomen. In **hoofdstuk 9 B** werd de succesvolle behandeling beschreven van een 52-jarige patiënt met een granulomateuze tatoeagereactie met geassocieerde uveïtis. De klinische presentatie bestond uit het acuut ontstaan van zwelling en jeuk in al haar 11 zwarte tatoeages met simultaan een bilaterale recidiverende uveïtis. Geen aanwijzingen werden gevonden voor andere uveïtis-geassocieerde aandoeningen zoals sarcoïdose. De behandeling bestond uit hoge dosis prednison oraal en methotrexaat, dit leidde tot verbetering van de oog- en huidklachten. Een granulomateuze tatoeagereactie met geassocieerde uveïtis is een veelal onbekende entiteit en diens onderliggende pathomechanisme is nog onbekend. Gesuggereerd wordt dat deze aandoening een granulomateuze vertraagde allergische reactie (type IV) op de tatoeage-inkt is of toch een uiting in het spectrum van sarcoïdose. In **hoofdstuk 9 C** wordt de spontane remissie beschreven van een multiresistente Mycobacterium abscessus infectie in de tattoo van een 56-jarige immunocompetente man. De klinische presentatie bestond uit multipole erythematosquameuze papels en pustels, voornamelijk gelokaliseerd in de zwart en wit getatoeëerde huid. Een kweekbiopt toonde Mycobacterium abscessus. Resistentie werd gevonden voor ciprofloxacin, clarithromycine, co-trimoxazol, doxycycline, imipenem, linezolid en moxifloxacin. Opmerkelijk genoeg werd tussentijds spontane klinische verbetering door de patiënt gerapporteerd. Na 1.5 maand werd totaal remissie van de huidafwijkingen waargenomen. Follow-up na 8 maanden toonde geen klinische aanwijzingen voor recidief van de infectie.



&

**PHD PORTFOLIO  
DANKWOORD  
LIST OF PUBLICATIONS  
CURRICULUM VITAE**



The information contained herein is the property of the manufacturer.

## PHD PORTFOLIO

Name PhD student: Sebastiaan A.S. van der Bent

PhD Period: 2014-2021

### Education

2015-2020 Dermatology residency, Amsterdam UMC (locations VUmc and AMC)

### Courses

- 2019 Euroderm Excellence Training Program, 16th Edition, Rome, Italy
- 2019 Hugh Greenway's 36th Annual Superficial Anatomy & Cutaneous Surgery Course. San Diego California, United States of America
- 2018 European Academy of Dermatology and Venereology Course - Cosmetic Dermatology Brussels, Belgium
- 2015 Media training course by journalist Liesbeth Groenendijk, VU University, Amsterdam
- 2011 Masterclass clinical research and epidemiology, LUMC, Noordwijk

### Presentations and abstracts

- 2020 Complicaties bij permanente make-up en tattoos. Dag van de Huidtherapeut – Nederlandse Vereniging van Huidtherapeuten. Online congres.
- 2020 De Tattoopoli: kliniek en onderzoek. Wetenschappelijke Vergadering Dermatologie 2020 door het Amsterdam UMC. Online congres.
- 2020 Abstract: Identifying Tattoo Pigments in Human Skin Samples with Adverse Reactions Based on Mass Spectral Library Matching and  $\mu$ XRF. C. Brungs, R. Schmid, C. Wolf, S. van Der Bent, U. Karst. 53rd annual conference of the Deutschen Gesellschaft für Massenspektrometrie, Münster, Germany. *Postponed due to COVID-19.*
- 2020 Abstract: Identifying Tattoo Pigments in Human Skin Samples with Adverse Reactions Based on Mass Spectral Library Matching and  $\mu$ XRF. C. Brungs, R. Schmid, C. Wolf, S. van Der Bent, U. Karst. ASMS Conference on Mass Spectrometry and Allied Topics, Houston, United States of America. *Postponed due to COVID-19.*
- 2020 Abstract: Tattoo Allergy: Towards a Patch Test Series to Identify Culprit Compounds. 174-T. Rustemeyer, J. Serup, S. van der Bent, S. Schubert, M. Kaveh, A. Luch, I. Schreiver. European Society of Contact Dermatitis Congress, Amsterdam, The Netherlands. *Postponed due to COVID-19.*
- 2020 Complications in tattooing and permanent makeup. Dutch Permanent Makeup Conference: Ridderkerk, The Netherlands (oral presentation). *Postponed due to COVID-19.*



- 2020 Tattoo complications. Dermatologie Congres 2020: Arnhem, The Netherlands (oral presentation). *Postponed due to COVID-19*.
- 2019 Treatment of allergic tattoo reactions. 28th European Academy of Dermatology and Venereology Congres: Madrid, Spain (oral presentation).
- 2019 Dermatologic complications in tattoos. Presentation for Master students Medicine at symposium 'pronkstukken van het VUmc'. VU medisch centrum, Amsterdam.
- 2019 Abstract: Treatment of allergic reaction to red tattoos. S. van der Bent, A. Wolkerstorefer, T. Rustemeyer. 4rd European Congress on Tattoo and Pigment (ECTP): Bern, Switzerland (oral presentation).
- 2019 Abstract: Kwantificatie van allergische reacties met 3D optical imaging. M. den Blanken, S. van der Bent, N. Liberton, M. Hofman, M. Grimbergen, R. Verdaasdonk, T. Rustemeyer. Jaarlijkse conferentie van de Nederlandse Vereniging voor Klinische Fysica, Woudschoten, The Netherlands.
- 2018 Abstract: Analysis of tattoo pigments in human skin tissue with  $\mu$ XRF and LDI-MS. C. Brungs, T. Berg, S. van der Bent, M. Sperling, U. Karst. ANAKON, Fachgruppe Analytische Chemie in der Gesellschaft Deutscher Chemiker, Münster, Germany.
- 2018 Abstract: Determination of the skin sensitization potency of red and black tattoo inks using human reconstructed skin and IL-18. W. Bil, S.A.S. van der Bent, S.W. Spiekstra, K. Nazmib, T. Rustemeyer S. Gibbs. 54th Congress of the European Societies of Toxicology (EUROTOX 2018), Brussels, Belgium.
- 2017 Dermatologic complications in tattoos. Presentation for Master students Medicine at symposium 'pronkstukken van het VUmc'. VU medisch centrum, Amsterdam.
- 2017 Abstract: Allergic reaction to red pigment tattoos and treatment methods. S. van der Bent, A. Wolkerstorefer, T. Rustemeyer. 3rd European Congress on Tattoo and Pigment (ECTP): Regensburg, Germany (oral presentation).
- 2017 "Think before you ink: complications in tattoos". Course for Dutch Dermatologists at Eilanddagen, Schiermonnikoog, The Netherlands (oral presentation).
- 2015 Abstract: Cutaneous allergic reactions to red dye in tattoos. S. van der Bent, A. Wolkerstorefer, T. Rustemeyer. 2rd European Congress on Tattoo and Pigment (ECTP): Brugge, Belgium (poster presentation).
- 2015 Training of nurses of the GGD (Community Health Services) visiting tattoo shops about adverse events in tattooing (oral presentation), Utrecht, Netherlands.
- 2014 Population pharmacokinetics and pharmacogenetics of once daily tacrolimus formulation in stable liver transplant recipients. Annual Meeting of American Society for Clinical Pharmacology and Therapeutics, Atlanta, Georgia, USA (poster presentation).



## Conferences

- 2020 Wetenschappelijke Vergadering Dermatologie 2020 (Amsterdam UMC):  
online conference
- 2020 46. Deutscher Koloproktologen-Kongress, München, Germany (*Postponed due to COVID-19*)
- 2019 European Academy of Dermatology and Venereology 28th Congress:  
Madrid, Spain
- 2019 4rd European Congress on Tattoo and Pigment (ECTP): Bern, Switzerland
- 2018 American Academy of Dermatology, San Diego, United States of America
- 2017 3rd European Congress on Tattoo and Pigment (ECTP): Regensburg, Germany
- 2015 2rd European Congress on Tattoo and Pigment (ECTP): Brugge, Belgium
- 2014 Annual Meeting of American Society for Clinical Pharmacology and Therapeutics,  
Atlanta, Georgia, United States of America

## Teaching

- 2019 Ellen Oyen, scientific internship, Master student Medicine MUMC
- 2018 Marloes Engel, scientific internship, Master student Medicine VUmc
- 2018 Mark den Blanken, scientific internship VUmc, resident Clinical Physics
- 2017 Sanne Huisman, scientific internship, Master student Medicine VUmc
- 2016 Daan Rauwerdrink, extracurricular research project, Master student  
Medicine LUMC
- 2016 Wieneke Bil, scientific internship, Master student Toxicology UMCU
- 2016 Tess Heijs, scientific internship, Bachelor student Medicine VUmc
- 2016 Ruben de Winter, scientific internship, Master student Medicine VUmc

## Awards

- 2018 Dutch (resident) Dermatology award (JONGE LEEUW Dermatologieprijs): prize  
for 'resident dermatology of the year', annually awarded (nominated by colleagues)  
in the Netherlands, as a result of exceptional or innovative initiatives  
or performances.
- 2014 KNAW Van Walree Grant (Royal Netherlands Academy of Arts and Sciences) for  
presenting medical research abroad.




**Media contributions**

04/09/2014	<b>Het Parool</b>	<i>GGD luidt noodklok over thuishatooëerder</i>
12/03/2015	<b>VUmc Magazine</b>	<i>Veilig versieren: Meester-tatoeëerder Henk Schiffmacher en dermatoloog in opleiding Van der Bent slaan handen ineen.</i>
13/01/2017	<b>RTL Editie NL</b>	<i>Tattoo-allergie: vooral rode inkt veroorzaakt klachten</i>
13/01/2017	<b>NOS</b>	<i>Speciale tattooopoli voor pijnlijke probleemtatoeages</i>
13/01/2017	<b>Volkskrant</b>	<i>Tattooopoli gaat pijnlijke tatoeages verwijderen</i>
13/01/2017	<b>De Telegraaf</b>	<i>VUmc opent tattooopoli</i>
13/01/2017	<b>Medisch Contact</b>	<i>Dermatologen beginnen tattooopoli</i>
13/01/2017	<b>Radio 538, NPO 1</b>	<i>VUmc opent eerste tattooopoli</i>
13/01/2017	<b>Metro</b>	<i>VUmc opent eerste tattooopoli van Nederland</i>
13/01/2017	<b>www.nu.nl</b>	<i>VUmc opent tattooopolikliniek</i>
16/01/2017	<b>AT5</b>	<i>VUmc opent speciale tattooopoli</i>
10/08/2017	<b>Algemeen Dagblad</b>	<i>Helpt van tattoo-allergieën ontstaat pas lang na zetten</i>
10/08/2017	<b>Social Media*</b>	<i>Tattoo-allergieën ontstaat lange tijd ná het zetten</i>
01/12/2017	<b>HEELdeHUID</b>	<i>Tatoeages en de huid: "Think before you ink" (i.s.m. M. Wintzen)</i>
07/04/2018	<b>Bionieuws</b>	<i>Het geheim van de eeuwige tattoo</i>
21/04/2018	<b>www.scientias.nl</b>	<i>Tatoeages: een onschuldige versiering of een bedreiging voor je gezondheid?</i>
01/07/2018	<b>Ned.Tijd. v. Huidzorg</b>	<i>Complicaties bij permanente make-up</i>
29/07/2018	<b>Volkskrant</b>	<i>Onder het mes voor de perfecte wenkbrauw</i>
30/10/2018	<b>Quest</b>	<i>Hoe schadelijk is een tatoeage voor je lichaam?</i>
09/11/2018	<b>Trouw</b>	<i>Is rondreizende tatoeage-inkt schadelijk?</i>
21/12/2018	<b>Boek</b>	<i>'Tatoeage en toezicht in Amsterdam', Hygiëne &amp; Inspectie GGD Amsterdam</i>
13/06/2019	<b>Social Media*</b>	<i>Zeven feitjes over de Tattooopoli</i>
18/07/2019	<b>www.doq.nl</b>	<i>'Allergische reactie op rode inkt in tattoo voor overleden kind'</i>
01/08/2019	<b>Medisch Contact</b>	<i>Opgezette tatoeage en oogklachten</i>
21/08/2019	<b>www.rtlnieuws.nl</b>	<i>In Duitsland mogen alleen artsen straks tattoos weghalen: 'Het is best ingewikkeld'</i>
02/12/2019	<b>Medisch Contact</b>	<i>Blauw verkleurde lymfeklier in de lies (i.s.m. J.J.W.M. Brouwers en H. Veger)</i>

**NOS** Nieuws Sport Uitslagen

Om zoveel mogelijk mensen te bereiken, zoekt Van der Bent contact met de bekende tatoeëerder Henk Schiffrincher. "Belangrijk voor ons is dat hij de pool ontdekt. Hij stimuleert mensen met medische problemen bij tatoeages een afspraak te maken, of mee te nemen aan onderzoek naar de oorzaak, risicofactoren en behandeling van de allergische reacties bij tatoeages."




**De Telegraaf** NIEUWS / BINNENLAND

**Kieftien komen vaak door rode inkt**

## VUmc opent tattooepoli


11 mei 2017 15:30 uur

AMSTERDAM - Mensen die last krijgen van een tattoo, kunnen overtuigd worden om een spoed tattooepoli. Dit is vrijdag in Amsterdam geopend door het VUmc. Het medisch centrum van de Vrije Universiteit. De tattooepoli is niet bedoeld voor alle patiënten, die een tattooage hebben laten verwijderen.



**Instagram** Amsterdam UMC


Zeven feiljes over de Tattooepoli



De afgelopen decennia is het aantal tattoo's bij de mens flink en snel toegenomen. Niet de laatste reden hiervoor is de populariteit van tatoeages. Het aantal tatoeages is in Nederland in 2017 een recordaantal bereikt. Dit is geen grap van de Spinoza Lab.

**HEEL DE HUID**

**MEDISCH INK**




**NOS Radio 1 Journaal**

## de Volkskrant

### Tattooepoli gaat pijnlijke tatoeages verwijderen


Iedereen met huidproblemen door tatoeage vandaag terecht bij de eerste tattooepoli van in het VUmc in Amsterdam. Het ziekenhuis



**Trouw**


## rondreizende tatoeagekt schadelijk?

**AD** Nieuws Regio Sport Show Video NL blijft Thuis



**Het Parool**

In de tattooepoli: 'De korsten waren zo groot dat ze scheurden'



**'Helpt van tattoo-allergieën ontstaat pas lang na zetten'**



10/11/2019	<b>Het Parool</b>	<i>In de tattoopoli: 'De korsten waren zo groot dat ze scheurden'</i>
12/03/2020	<b>De Telegraaf</b>	<i>'Laseren voor een prikkie'</i>
01/06/2020	<b>SarcoScoop</b>	<i>Sarcoïdose op de Tattoopoli</i>
01/09/2020	<b>HEELdeHUID</b>	<i>Tattoopoli in Leiden als kenniscentrum</i>
23/10/2020	<b>Radar - AVROTROS</b>	<i>Tattoo verwijderen: hoelang duurt het en wat zijn de kosten?</i>

\* Twitter, Facebook, Instagram, LinkedIn, Amsterdam UMC website

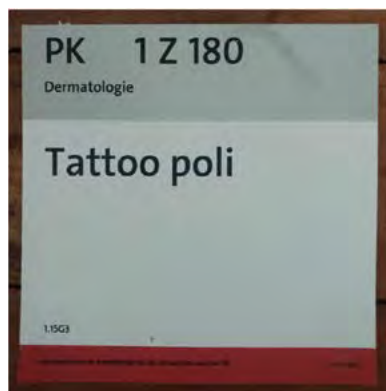### **Other activities**

2017 – 2020	Board member European Society on Tattoo and Pigment Research (ESTP)
2017 – 2020	Reviewer for JEADV, Dermatology, International Journal of Dermatology
2015 – 2020	Consultations by e-mail (info@tattoopoli.nl / tattoo@vumc.nl) or telephone for dermatologists, skin therapists, general practitioners and tattoo artists (>250)


## DANKWOORD

Het bijzondere aan dit proefschrift is dat het vanuit niets is opgebouwd. Het is ooit begonnen met een case-report van een patiënt met een tattoo allergie. Dit leidde tot verder onderzoek, veel specialistische patiëntenzorg en de oprichting van de Tattoo poli, gepaard met landelijke media aandacht. De vele onderzoeksvoorstellen, databases, congressen, subsidieaanvragen en artikelen resulteerden uiteindelijk in dit proefschrift. In deze lange looptijd zijn ontzettend veel mensen betrokken geweest (meer dan 50!). Daarom wil ik hier graag iedereen bedanken die heeft bijgedragen aan of geholpen bij de totstandkoming van dit proefschrift. Het onderzoek vergde veel tijd, toewijding en inspanning. Echter, de meeste werkzaamheden bestonden uit de reguliere (tattoo) patiëntenzorg, het opzetten van de Tattoo poli en het contact met de tatoeëerders en media. Al deze niet-gesubsidieerde activiteiten zijn gedaan naast mijn opleiding tot dermatoloog, wat resulteerde in soms drukke tijden. Desondanks heb ik dit alles als zeer leerzaam en plezierig ervaren.

*What makes this thesis special is that it started from scratch. It all began with a case-report of a patient with a tattoo allergy. This led to further research, specialised patient care and the founding of the Tattoo Clinic resulting in nationwide media coverage. Many research proposals, databases, conferences, grant applications and articles finally resulted in this thesis. During this period, many people have been involved (more than 50!). Therefore, I hereby want to thank everyone who has contributed or helped in any way realizing this thesis. The research took a lot of time, dedication and effort. However, most activities consisted of regular tattoo patient care, founding of the Tattoo Clinic and contact with tattoo artists and the media. All these non-funded activities were done before and in addition to my fulltime Dermatology residency, resulting in a busy work schedule. Nevertheless, I have always experienced it all as very educational and pleasant.*



Het eerste kamerbordje van de Tattoo poli op 13 januari 2017.  
*The first room sign of the Tattoo Clinic on January 13<sup>th</sup> 2017.*



Om te beginnen, wil ik graag alle betrokken tatoeëerders en permanente make-up artiesten bedanken. In 2014, toen ik werkte in het Albert Schweitzer Ziekenhuis, ben ik samen met jullie de eerste onderzoeken begonnen. Jullie open houding, interesse en enthousiasme waren, en zijn, ontzettend fijn en inspirerend. De goede contacten met o.a. Henk Schiffmacher (Schiffmacher & Veldhoen), Ralph Moelker (Team Tattoo Bob) en Anoesh Vroomman (SkinQuip), waardeer ik enorm!

Beste Thomas, promotor, bedankt voor alle mogelijkheden en vrijheid die je me hebt gegeven. Je reageerde altijd enthousiast op al mijn ideeën: van patiëntenzorg tot het opzetten van de Tattoo poli. Maar vooral: bij jou heb ik aangeklopt met mijn onderzoeksvoorstel naar tattoo complicaties. Hierop reageerde jij positief, en dat zal ik nooit vergeten. Bedankt voor dit vertrouwen. Onze samenwerking heeft tot mooie dingen geleid met in de toekomst mogelijk nog meer.

Beste Albert Wolkerstorfer, co-promotor, ik ga onze samenwerking erg missen. Door jouw kennis en ervaring, als autoriteit op het gebied van laserbehandelingen en pigmetaandoeningen, heb ik veel geleerd en vele onderzoeken kunnen realiseren. Je bent altijd enthousiast, kritisch en geïnteresseerd geweest in mijn onderzoeken en dat heb ik erg gewaardeerd. Soms zelfs zó enthousiast, dat ik na een bespreking vaak met nóg meer onderzoek ideeën de deur uit liep dan ik zelf voor mogelijk hield.

Alle co-auteurs, ik ben jullie erkentelijk voor jullie bijdrage, feedback en prettige samenwerking.

Geachte leden van de lees- en promotiecommissie, hartelijk dank voor uw deelname en het kritisch lezen en beoordelen van het manuscript. *I would like to thank you for the critical assessment of this manuscript.*

Beste Rick Hoekzema, ontzettend bedankt voor mijn fantastische opleidingstijd. Als 'lopende Bologna' heb ik enorm veel van u geleerd; niet alleen dermatologisch inhoudelijk, maar ook qua patiëntcommunicatie.

Beste Marjolein, dank voor alle steun, wijze lessen en mogelijkheden die ik heb gekregen tijdens mijn opleiding en onderzoeken. Ik heb onze gesprekken altijd als zeer waardevol en prettig ervaren.

Alle andere stafleden van het Amsterdam UMC, in het bijzonder Edith de Boer, wil ik graag bedanken voor mijn opleidingstijd en het stimuleren van het voltooiën van mijn onderzoek. Ook de MMA, secretariaat en verpleging van het Amsterdam UMC, voornamelijk Marjon, Yvonne, Mariska, Kees en Peter, jullie zijn onmisbaar op de afdeling!

*Dear Jørgen Serup, already in 2014 you welcomed me in your Tattoo Clinic in Copenhagen. At that time I wasn't even a dermatology resident. You introduced me to the medical world of tattoos, for this I am very grateful to you and I will never forget it. I wish to thank all other board members of the ESTP, especially Christa de Cuyper, Marie Leger, Nicolas Kluger, Wolfgang Baumler and Thijs Veenstra.* Beste Thijs, we hebben elkaar ontmoet tijdens een van de eerste congressen van het European Congress on Tattoo and Pigment Research (ECTP). Sindsdien werken we ontzettend prettig samen en houden we elkaar op de hoogte van ieders vak op het gebied van tatoeëren.

Beste Caroline Arps en Loes Magnin (afdeling communicatie AUMC), onze samenwerkingen heb ik altijd als zeer prettig ervaren. Ik vind jullie een ontzettend professioneel, leuk, innovatief en enthousiast team. Ik heb enorm veel van jullie geleerd wat betreft 'omgaan' met de media: NOS, RTL, alle kranten en social media. Niets is jullie te groot en jullie zijn altijd enthousiast.

Beste proctologie mentoren, Bart Nanninga, Mente Bousema, Charlotte Molenaar en Juan-Carlos Galvis Martinez: hartelijk dank voor alle lessen in dit bijzondere vakgebied. Het is een hele andere tak van sport in de dermatologie, maar één met zeer dankbare patiënten!

Beste studenten wetenschappelijke stage (inmiddels basisartsen of dermatologen i.o.): Ruben de Winter, Sanne Huisman, Marloes Engel, Mark den Blanken, Ellen Oyen, Daan Rauwerdink, Tess Heijs, Wieneke Bil: bedankt voor al jullie onmisbare inspanningen. Jullie hebben bergen werk verzet, zonder jullie was dit alles niet gelukt. Ik vond het leuk en gezellig om met jullie samen te werken.

Alle (oud-)collega AIOS van het Amsterdam UMC (VUmc en AMC), in het bijzonder Karen Maijer, Niels Deenen, Darryl Tio, Rosanna Kuin, Dennis Hack, Ellen Hamers, Maryam Soltanipoor, Thijs Siegenbeek van Heukelom, Hannah Verhagen en Irene Holtslag: het was een enorm leuke opleidingstijd en ik heb er ontzettend van genoten. Alle COCOMs, skireizen, borrelavonden, AAD en snijcursus San Diego, weekenden weg en farmacie-avonden: ze waren geweldig! Er gebeurden altijd bijzondere dingen: sommigen konden hun huis niet meer terug vinden, glazen werden rondgegooid of de trap kreeg een kleurtje. Gelukkig zijn we er heelhuids vanaf gekomen. Beste Niels, de Rotterdamse blufkikker in Amsterdam, het is jammer dat er niet meer kerels (lees boefjes) zoals jij zijn in een AIOS groep! Roodkapje team, door de ontelbaar mooie momenten en herinneringen hebben jullie de opleiding tot iets onvergetelijks gemaakt. *Memories never die.*



Beste Jonathan Kadouch, met jouw kennis en ervaring vanuit de cosmetische dermatologie en jouw promotieonderzoek heb je mij enorm geholpen, nogmaals dank voor al je adviezen!

Beste dermatologen van het Alrijne Ziekenhuis: Andy Kusuma, Laurence Khoe, Rachel Bakkum, Ronald Siphanto, Douwe Vellinga, Pascale Diederden, Clemens van Eijk, Robert van Leeuwen, Barbara Bussink en Ines Schornagel: het is een plezier om in deze mooie maatschap te mogen werken, bedankt voor de prettige samenwerking! Het is erg fijn dat ik alle ruimte heb gekregen om de Tattoo poli te starten in het Alrijne ziekenhuis. Beste Ines, wat bijzonder dat wij samen ooit de 1<sup>e</sup> tattoo patiënt hebben gezien, wat uiteindelijk onverwacht het begin is geweest van dit alles!

Ook alle lieve doktersassistenten en medisch secretaresses van het Alrijne: het is heel fijn om met jullie samen te werken op onze afdeling. Veel dank voor de flexibiliteit en ondersteuning bij de drukke poli's na de soms korte nachten.

Boks: harde gasten, Leidsche bekkies, wat hebben we afgelopen jaren veel meegemaakt. Van BBA tot BBS, van afstudeerborrels tot O&N, van lippenstift tot emigreren naar Indonesië, van BODE tot de Roze Beurs. Ik heb een gevoel dat er nog veel gaat komen.

Adeodatus, voornamelijk Vincent Verhulst, Boyd Wolffers, Tommy van den Bergh, Daniel Rodenburg en Felix Oostindie: jullie hebben totaal niets bijgedragen aan mijn promotieonderzoek, eerder tegengewerkt. Na sommige heetclub avonden moest ik soms drie dagen herstellen. Desondanks heb ik ervan genoten, waarvoor dank.

Lieve Wilma, Cocq en Mabel, bedankt voor jullie steun en oprechte interesse. Ook veel dank voor de vele (ontspannen) vrijdagavonden: deze worden enorm gewaardeerd. Cocq, bedankt voor jouw taalkundige correcties, we drinken er binnenkort weer een 'grappa' op!

Beste Jeroen, de Jay, Jiske. Er zijn maar weinig mensen die me midden in de nacht mogen wakker bellen. Onze vriendschap is iets unieks. Als (oud-)studie-, huis-, club- en dispuutsgenoot, maar voornamelijk vriend kennen wij elkaar door en door en is er vaak maar één woord nodig om iets te zeggen. Zoals het hoort bij twee Brabantse boefjes zoeken we soms het randje op, met vaak grote hilariteit tot gevolg. We denken vaak hetzelfde en kunnen altijd op elkaar rekenen, en dat waardeer ik enorm. Overigens hebben we allebei in het verre verleden gezworen dat we *nooit* onderzoek zouden gaan doen: dat is voor beiden niet helemaal gelukt.

Beste Alexander & Anouk, Jesse & Hannah, bedankt voor jullie steun, interesse, afleiding en relativering de afgelopen jaren. Het is fantastisch om te zien hoe onze kids met elkaar opgroeien, hopelijk krijgen zij later net zo een goede band als wij.

Alle andere familieleden: dank voor de lieve berichtjes, steun en interesse de afgelopen jaren!

Ha die lieve ma. Een betere moeder is er niet. Je bent er altijd. Jij en pa hebben me gestimuleerd mijn doelen te bereiken, zo ook hier. Bedankt voor de altijd onvoorwaardelijke steun. Het is overigens wel jammer dat ik na een 13-jarige opleiding nog steeds niet serieus wordt genomen. Je vertelt me namelijk nog regelmatig wat ik wél



en niet op die babybiljetjes moet smeren. Achja, ik hou me maar voor dat zoiets 'moeder eigen is' en dat het me 'met beide benen op de grond' houdt.

Lieve Gerard, het is ontzettend fijn dat je in ons leven bent gekomen. Je bent een enorm lieve man voor ons, en mijn moeder. We vinden je een fantastisch leuke en lieve opa, voor ál je kleinkinderen!

Lieve Sharon, Beau & Hugo, wat ontzettend bijzonder en mooi waren de afgelopen jaren. Het was soms ook hectisch (o.a. met cashewnootjes), maar jullie waren er altijd om mij te helpen relativeren. Jullie zijn dan ook van onschatbare waarde en betekenis voor mij. Nu het grootste deel van de promotie achter de rug is, kijk ik uit naar de extra tijd die we met elkaar kunnen doorbrengen. Lieve Sharon, zonder jou was dit alles zeker niet mogelijk geweest. Ook al is geneeskunde niet jouw 'vakgebied', je hebt me altijd gestimuleerd en gesteund. En dat vind ik heel lief en bijzonder. Lieve Beau en Hugo, zijn jullie de allerliefste en mooiste mannetjes die ik ken. Jullie lach is onbetaalbaar. Lieve Beau, je bent nog maar 2,5 jaar oud, maar wat ben ik al ongelofelijk trots op je. Je bent sociaal en verbaal ontzettend bedreven. Je weet dan ook altijd iedereen voor je te winnen, zo ook mij. Als ik na een 11 uur durende werkdag, hongerig en moe thuis kom en jij met je schattige stemmetje direct vraagt "Papa ook treinbaan maken?", dan ga ik als volwassen man gewoon eerst uitgebreid een treinbaan maken.

Lieve pa, uiteraard had jij hier ook bij moeten zijn. Helaas mocht dit niet zo zijn. Ik denk dat je dit, maar nog meer de afgelopen jaren, ontzettend mooi had gevonden.

*Hayatıma girdiğin için çok memnunum.*

## LIST OF PUBLICATIONS

1. van der Bent SAS, Maijer KI, Wolkerstorfer A, Rustemeyer T. De Tattoopoli: Kliniek en onderzoek. *Nederlands Tijdschrift voor Dermatologie en Venereologie*. 2020 Oct;30(8):56-59. (Article in Dutch)
2. Oyen E, Maijer KI, van der Bent SAS, Prins JM, Janssen S, Kuipers S, De Vries HJC. Spontaneous resolution of multidrug-resistant *Mycobacterium abscessus* infection in tattoo. *Journal of the European Academy of Dermatology and Venereology*. 2020 Dec 8. <https://doi.org/10.1111/jdv.17072>
3. van der Bent SAS, Huisman S, Rustemeyer T, Wolkerstorfer A. Ablative laser surgery for allergic tattoo reactions: a retrospective study. *Lasers in Medical Science*. 2020. <https://doi.org/10.1007/s10103-020-03164-2>
4. van der Bent SAS, Oyen E, Rustemeyer T, Jaspars EH, Hoekzema R. Histopathology of red tattoo reactions: a predominantly histiocytic allergic reaction. *The American Journal of Dermatopathology*. 2020 Jul 22. doi: 10.1097/DAD.0000000000001751.
5. van der Bent SAS, Engel MJC, Nossent EJ, Jonkers RE, Wolkerstorfer A, Rustemeyer T. Tattoos and self-reported adverse events in sarcoidosis patients. *Journal of the European Academy of Dermatology and Venereology*. 2020 Apr;34(4):e167-e169. <https://doi.org/10.1111/jdv.16115> 2019
6. Huisman S, van der Bent SAS, Maijer KI, Tio DCKS, Rustemeyer T. Cutaneous non-allergic complications in tattoos: an overview of the literature. *Presse Medicale*. 2020 Dec;49(4). 104049. <https://doi.org/10.1016/j.lpm.2020.104049>
7. van der Bent SAS, Kemperman PM, Vulink NC, Hoekzema R. Morgellons, een 'sociaal overdraagbare' aandoening. *Nederlands Tijdschrift voor Geneeskunde*. 2019 Nov 7;163. (Article in Dutch)
8. den Blanken MD, van der Bent SAS, Liberton N, Grimbergen M, Hofman MBM, Verdaasdonk R et al. Quantification of cutaneous allergic reactions using 3D optical imaging: A feasibility study. *Skin Research and Technology*. 2020 Jan 1;26(1):67-75. <https://doi.org/10.1111/srt.12765>
9. van der Bent SAS, de Winter RW, Wolkerstorfer A, Rustemeyer T. Red tattoo reactions, a prospective cohort on clinical aspects. *JEADV. Journal of the European Academy of Dermatology and Venereology*. 2019 Oct 1;33(10):e384-e386. <https://doi.org/10.1111/jdv.15677>
10. van der Bent SAS, Berg T, Karst U, Sperling M, Rustemeyer T. Allergic reaction to a green tattoo with nickel as a possible allergen. *Contact Dermatitis*. 2019 Jul;81(1):64-66. <https://doi.org/10.1111/cod.13226>

11. de Winter RW, van der Bent SAS, van Esch M, Wolkerstorfer A, Rustemeyer T. Allergic Reaction to Red Cosmetic Lip Tattoo Treated With Hydroxychloroquine. *Dermatitis*. 2019 Jan 1;30(1):82-83. <https://doi.org/10.1097/DER.0000000000000437>
12. Huisman S, van der Bent SAS, Wolkerstorfer A, Rustemeyer T. Granulomatous tattoo reactions in permanent makeup of the eyebrows. *Journal of Cosmetic Dermatology*. 2019 Feb 1;18(1):212-214. <https://doi.org/10.1111/jocd.12540>
13. Bil W, van der Bent SAS, Spiekstra SW, Nazmi K, Rustemeyer T, Gibbs S. Comparison of the skin sensitization potential of 3 red and 2 black tattoo inks using interleukin-18 as a biomarker in a reconstructed human skin model. *Contact Dermatitis*. 2018 Dec;79(6):336-345. <https://doi.org/10.1111/cod.13092>
14. Majier KI, van der Bent SAS, Vercoutere W, Rustemeyer T. Granulomatous tattoo reaction with associated uveitis successfully treated with methotrexate. *Journal of the European Academy of Dermatology and Venereology*. 2018;32(9):e338-e339. <https://doi.org/10.1111/jdv.14854>
15. van der Bent SAS, Majier KI, Rustemeyer T. Hyperkeratotic hypersensitivity reaction to red pigment tattoo. *British Journal of Dermatology*. 2017;177(6):e350. <https://doi.org/10.1111/bjd.16040>
16. van der Bent SAS, Rustemeyer T. Abstract: 'Think before you ink'. *Nederlands Tijdschrift voor Dermatologie en Venereologie*. 2017 Aug;27(7):369-370. (Article in Dutch)
17. van der Bent S, van Vugt M, Amir A, van der Wal A, Mekkes J. Cutaneous manifestations in treated Whipple's disease. *International Journal of Dermatology*. 2017 Apr;56(4):e82-e84. <https://doi.org/10.1111/ijd.13479>
18. van der Bent SAS, Schamp KBC, Galvis Martinez JC. A man with an unique tongue disorder. *Netherlands Journal of Medicine*. 2017 Jan;75(1):39.
19. van der Bent SAS, Wolkerstorfer A, Rustemeyer T. Huidafwijkingen bij tatoeages. *Nederlands Tijdschrift voor Geneeskunde*. 2016 Jan 1;160(29):525-536. (Article in Dutch)
20. van der Bent SAS, Van Der Velden JAJ. Periaanaal ecZEEM. *Nederlands Tijdschrift voor Dermatologie en Venereologie*. 2016 Apr 1;26(4):226-227. (Article in Dutch)
21. Geelen IGP, Cornelissen JJ, te Boekhorst PA, van der Bent SAS, Valk PJM, Beverloo V, Makkus L, Westerweel PE. Een patiënt met chronische myeloïde leukemie presenterend in gevorderd ziektestadium met diverse klinische, cytogenetische en moleculaire epifenomenen. *Nederlands Tijdschrift voor Hematologie* 2016;13: 143-8. (Article in Dutch)

22. Moes DJAR, van der Bent SAS, Swen JJ, van der Straaten T, Inderson A, Olofsen E et al. Population pharmacokinetics and pharmacogenetics of once daily tacrolimus formulation in stable liver transplant recipients. *European Journal of Clinical Pharmacology*. 2016 Feb;72(2):163-74. <https://doi.org/10.1007/s00228-015-1963-3>
23. Moes DJAR, Swen JJ, van der Bent SAS, van der Straaten T, Inderson A, Olofsen E et al. Response: Limited sampling strategies for once daily tacrolimus exposure monitoring. *European Journal of Clinical Pharmacology*. 2016 Jun;72(6):775-6. <https://doi.org/10.1007/s00228-016-2036-y>
24. van der Bent SAS, van Ham-Borawitz VEJ, de Kleijn ED, Reeder SWI, Laeijendecker R. A 7-year-old boy with fever, rash and coughing. Erythema multiforme (EM) major. *Netherlands Journal of Medicine*. 2015 Jul;73(6):302-3
25. van der Bent SAS, Schornagel IJ. Allergische reactie na permanente tatoeage. *Huisarts en Wetenschap*. 2015 Jan 1;58(1). <https://doi.org/10.1007/s12445-015-0021-9>. (Article in Dutch)
26. van der Bent SAS, Kuizinga MC, van der Velden JJAJ. Een jongen met chronische zwelling van de bovenlip. *Nederlands Tijdschrift voor Geneeskunde*. 2015;159:A9103. (Article in Dutch)
27. van der Bent SAS, Vellinga D. A woman with asymmetrical facial swelling. *Netherlands Journal of Medicine*. 2014 Jun;72(5):284,288.
28. van der Bent SAS, Vermont CL, Rijkers-Mutsaerts ERVM. Huiduitslag bij axillaire lymfadenopathie. *Tijdschrift voor Infectieziekten* 2013;8(5):168,172. (Article in Dutch)





Bron: [www.tattooopoli.nl](http://www.tattooopoli.nl). Leiden, 2020.

## CURRICULUM VITAE

Sebastiaan van der Bent werd geboren op 22 april 1988 te Bergen op Zoom. Daar doorliep hij de basisschool en middelbare school waarop in 2006 het VWO examen werd behaald bij Regionale Scholen Gemeenschap't Rijks. Later in dat jaar startte hij met de opleiding geneeskunde aan het Leids Universitair Medisch Centrum. De interesse voor de dermatologie was al snel aanwezig en hij volgde daarom zijn semi-arts stage bij de afdeling dermatologie van het Rijnland Ziekenhuis in Leiderdorp (thans: Alrijne Ziekenhuis). Tijdens deze periode zag hij zijn allereerste 'tatoeage patiënt'. Dit vond hij zo een bijzonder klinisch beeld dat hij de medische literatuur indook en hierover publiceerde. Het officiële co-schap Dermatologie volgde hij in Suriname (Academisch Ziekenhuis Paramaribo) en het keuze co-schap bij de plastische chirurgie in het LUMC.

De studie geneeskunde werd met het basisarts diploma afgerond in 2014. Hierna ging hij aan de slag als arts-assistent dermatologie (niet in opleiding) in het Albert Schweitzer Ziekenhuis in Dordrecht. In deze tijd heeft hij eigenhandig een onderzoek opgezet naar klachten en problemen bij tatoeages. Hij werkte hiervoor samen met verschillende tatoeëerders in Amsterdam, waaronder Henk Schiffmacher. De eerste onderzoeksresultaten waren zo veelbelovend, dat hij naar mogelijkheden zocht om het onderzoek uit te breiden. Hij benaderde hiervoor prof. Rustemeyer van het VU medisch centrum (VUmc), waaruit een nieuwe samenwerking volgde. Tevens bezocht hij de 'Tattoo Clinic' in Kopenhagen om zich verder te verdiepen in de behandeling van tattoo complicaties.

Op 1 april 2015 startte hij met de opleiding tot dermatoloog in het VUmc te Amsterdam. Een kleine twee jaar later, op 13 januari 2017, richtte hij daar de Tattoo poli op. Dit speciale spreekuur voor complicaties bij tatoeages werd een succes: in drie jaar werden er meer dan 350 patiënten behandeld. In 2018 ontving Sebastiaan de 'Jonge Leeuw Dermatologieprijs' vanwege zijn inzet en activiteiten op het gebied van zorg en onderzoek naar tattoo complicaties. Daarnaast slaagde hij er in meerdere nationale en internationale samenwerkingen op te zetten, o.a. met onderzoekers uit Münster, Berlijn en Kopenhagen. In die tijd begeleidde hij meer dan elf onderzoek studenten geneeskunde en gaf presentaties op internationale congressen. Sebastiaan verrichtte alle bezigheden rondom het tattoo onderzoek naast zijn fulltime opleiding tot dermatoloog. Tattoos vormden zijn voornaamste interesse, maar tijdens zijn opleidingstijd specialiseerde hij zich ook in de proctologie en dermatochirurgie.

Op 31 maart 2020 rondde hij de opleiding tot dermatoloog af. Vanaf 1 april 2020 startte Sebastiaan als dermatoloog op de plek waar hij ooit begon en waar hij het Tattoo spreekuur zal voortzetten: het Alrijne ziekenhuis in Leiden.







